



National Comprehensive
Cancer Network®

NCCN Clinical Practice Guidelines in Oncology (NCCN Guidelines®)

Bone Cancer

Version 1.2021 — November 20, 2020

NCCN Guidelines for Patients® available at www.nccn.org/patients

Continue



***J. Sybil Biermann, MD/Chair ¶ τ**
University of Michigan Rogel Cancer Center

***Warren Chow, MD/Vice-Chair † ‡**
City of Hope National Medical Center

Sarah Boles, MD † ‡
UC San Diego Moores Cancer Center

Brian Brigman, MD, PhD ¶ τ
Duke Cancer Institute

Alexandra K. Callan, MD τ ¶
UT Southwestern Simmons Comprehensive
Cancer Center

Lee D. Cranmer, MD, PhD † ¶
Fred Hutchinson Cancer Research Center/
Seattle Cancer Care Alliance

Saeed Dianat, MD ϕ
Abramson Cancer Center
at the University of Pennsylvania

Eric Donnelly, MD §
Robert H. Lurie Comprehensive Cancer
Center of Northwestern University

Nicola Fabbri, MD ¶ τ
Memorial Sloan Kettering Cancer Center

Patrick Getty, MD τ
Case Comprehensive Cancer Center/
University Hospitals Seidman Cancer Center
and Cleveland Clinic Taussig Cancer Institute

NCCN
Mary Anne Bergman
Giby George, MD

John Groundland, MD ¶
Huntsman Cancer Institute
at the University of Utah

Susan M. Hiniker, MD §
Stanford Cancer Institute

Angela Hirbe, MD, PhD †
Siteman Cancer Center at Barnes-
Jewish Hospital and Washington
University School of Medicine

Margo L. Hoover-Regan, MD €
University of Wisconsin
Carbone Cancer Center

Francis Hornicek, MD, PhD ¶
UCLA Jonsson Comprehensive Cancer Center

Lisa Kafchinski, MD τ ¶
O'Neal Comprehensive Cancer Center at UAB

Joseph B. Kuechle, MD, PhD ¶ τ
Roswell Park Comprehensive Cancer Center

Dieter Lindskog, MD τ
Yale Cancer Center/Smilow Cancer Hospital

David R. Lucas, MD ≠
University of Michigan Rogel Cancer Center

Joel L. Mayerson, MD ¶ τ
The Ohio State University Comprehensive
Cancer Center - James Cancer Hospital
and Solove Research Institute

Sean V. McGarry, MD τ ¶
Fred & Pamela Buffett Cancer Center

Carol D. Morris, MD, MS ¶ τ
The Sidney Kimmel Comprehensive
Cancer Center at Johns Hopkins

Damon R. Reed, MD €
Moffitt Cancer Center

Peter S. Rose, MD τ ¶
Mayo Clinic Cancer Center

Victor M. Santana, MD €
St. Jude Children's Research Hospital/The
University of Tennessee Health Science Center

Robert L. Satcher, MD, PhD ¶ τ
The University of Texas
MD Anderson Cancer Center

Joseph Schwab, MD, MS τ
Massachusetts General Hospital
Cancer Center

Herbert Schwartz, MD ¶ τ
Vanderbilt-Ingram Cancer Center

Breelyn A. Wilky, MD †
University of Colorado Cancer Center

Rosanna L. Wustrack, MD ¶ τ
UCSF Helen Diller Family
Comprehensive Cancer Center

[NCCN Guidelines Panel Disclosures](#)

ϕ Diagnostic/Interventional radiology	≠ Pathology
‡ Hematology/Hematologic oncology	€ Pediatric oncology
¶ Internal Medicine	§ Radiotherapy/Radiation oncology
† Medical oncology	¶ Surgery/Surgical oncology
τ Orthopedics	*Discussion Writing Committee Member

Continue



[NCCN Bone Cancer Panel Members
Summary of the Guidelines Updates](#)

[Multidisciplinary Team \(TEAM-1\)](#)
[Bone Cancer Workup \(BONE-1\)](#)

Chondrosarcoma:

- [Presentation \(CHON-1\)](#)
- [Primary Treatment, Low Grade and Intracompartmental \(CHON-2\)](#)
- [Primary Treatment, High Grade, Clear Cell, or Extracompartmental \(CHON-3\)](#)
- [Metastatic Chondrosarcoma \(CHON-4\)](#)

Chordoma:

- [Workup and Histologic Subtype \(CHOR-1\)](#)
- [Presentation and Primary/Adjuvant Treatment \(CHOR-2\)](#)
- [Surveillance and Recurrence \(CHOR-3\)](#)

Ewing Sarcoma:

- [Workup, Primary Treatment, Restage \(EW-1\)](#)
- [Adjuvant Treatment, Surveillance, and Relapse \(EW-2\)](#)
- [Metastatic Disease \(EW-3\)](#)

Giant Cell Tumor of Bone:

- [Workup and Presentation \(GCTB-1\)](#)
- [Primary Treatment \(GCTB-2\)](#)
- [Surveillance, Recurrence \(GCTB-3\)](#)

Osteosarcoma:

- [Workup and Primary Treatment \(OSTEO-1\)](#)
- [Neoadjuvant and Adjuvant Treatment \(OSTEO-2\)](#)
- [Metastatic Disease \(OSTEO-3\)](#)
- [Surveillance and Relapse \(OSTEO-4\)](#)

[Principles of Bone Cancer Management \(BONE-A\)](#)
[Systemic Therapy Agents \(BONE-B\)](#)
[Principles of Radiation Therapy \(BONE-C\)](#)
[Staging \(ST-1\)](#)

Clinical Trials: NCCN believes that the best management for any patient with cancer is in a clinical trial. Participation in clinical trials is especially encouraged.

To find clinical trials online at NCCN Member Institutions, [click here: nccn.org/clinical_trials/member_institutions.aspx](#).

NCCN Categories of Evidence and Consensus: All recommendations are category 2A unless otherwise indicated.

See [NCCN Categories of Evidence and Consensus](#).

NCCN Categories of Preference: All recommendations are considered appropriate.

See [NCCN Categories of Preference](#).

The NCCN Guidelines® are a statement of evidence and consensus of the authors regarding their views of currently accepted approaches to treatment. Any clinician seeking to apply or consult the NCCN Guidelines is expected to use independent medical judgment in the context of individual clinical circumstances to determine any patient's care or treatment. The National Comprehensive Cancer Network® (NCCN®) makes no representations or warranties of any kind regarding their content, use or application and disclaims any responsibility for their application or use in any way. The NCCN Guidelines are copyrighted by National Comprehensive Cancer Network®. All rights reserved. The NCCN Guidelines and the illustrations herein may not be reproduced in any form without the express written permission of NCCN. ©2020.



Updates in Version 1.2021 of the NCCN Guidelines for Bone Cancer from Version 1.2020 include:

Global change: Giant Cell Tumor of the Bone throughout the guideline.

[BONE-1](#)

Workup

- Lower pathway ≥ 40 for potential metastasis: Bone scan or PET/CT (category 2B).

[CHON-4](#)

Metastatic Chondrosarcoma

- Consider testing for tumor mutational burden (TMB) as determined by a validated and/or FDA-approved assay to inform the use of pembrolizumab, is a new footnote corresponding to "systemic therapy" (Also for CHOR-3, OSTEO-3)

[CHOR-1](#)

Chordoma

- Under Histologic Subtype, *Poorly differentiated* is new to the page.

[EW-1](#)

Ewing Sarcoma

- Footnote "e" has been modified to include the following: *For patients with Ewing-like sarcoma (eg, CIC-DUX4) an alternate treatment paradigm can be considered. For those who are negative, additional molecular testing is recommended.*

[EW-2](#)

Stable Improved Disease

- Under Adjuvant treatment/Additional Therapy, Negative margins, pathway modified: Chemotherapy (category 1) and consider RT for pelvic tumors.
- For Amputation in selected cases, "Postoperative chemotherapy" has been designated as a (category 1) recommendation.

[EW-3](#)

- Consider testing for (TMB) as determined by a validated and/or FDA-approved assay to inform the use of pembrolizumab category 2B, is a new footnote corresponding to metastatic Ewing sarcoma.

[GCTB-3](#)

Local Recurrence

- The following footnote is new to the page: *Risk of local recurrence is increased when denosumab is used prior to curettage. Denosumab may be beneficial to define peripheral tumor extent when planning wide resection.*

[OSTEO-1](#)

Workup

- Bullet 9 is new to the page: *Consider personal and family history for genetic consultation and testing.*

[OSTEO-3](#)

Primary Treatment

"Stereotactic RT or Ablation (if pulmonary metastasectomy is not possible)," is new to the page for resectable metastatic disease.

[OSTEO-4](#)

Footnotes

- "n": May include samarium or radium.

[BONE-A](#)

Principles of Bone Cancer Management

- Biopsy
 - ▶ 1st bullet: Prior to biopsy, consultation should be obtained with an orthopedic oncologist surgeon regarding appropriate prebiopsy imaging.
 - ▶ 2nd bullet is new to the page: *Preoperative biopsy consultation with pediatric oncologist as appropriate is recommended for children.*
- Treatment
 - ▶ 2nd bullet, [See NCCN Guidelines for Adolescent and Young Adult \(AYA\) Oncology](#), is new to this section.
 - ▶ 3rd bullet: *Select patients with osteosarcoma or chondrosarcoma may benefit from a referral for genetic consultation and testing based on family history with a genetic predisposition for bone sarcomas, is new to the page.*
- Long-term follow-up and Surveillance/Survivorship
 - ▶ 3rd bullet, deleted: See NCCN Guidelines for Adolescent and Young Adult (AYA) Oncology (15–39 years old) as clinically appropriate.

[BONE-B \(1 of 5\)](#)

Bone Cancer Systemic Therapy Agents

- The following references for Pembrolizumab for MSI-H/dMMR Tumors are new:
 - ▶ Marabelle A, Le DT, Ascierto PA, et al. *Efficacy of pembrolizumab in patients with noncolorectal high microsatellite instability/mismatch repair-deficient cancer: results from the phase II KEYNOTE-158 study. J Clin Oncol 2019;38:1-10.*
 - ▶ Lala M, Li TR, De Alwis DP, et al. *A six-weekly dosing schedule for pembrolizumab in patients with cancer based on evaluation using modelling and simulation. Eur J Cancer 2020;131:68-75.*
- Footnote "t" modified to include the following sentence: *Additional dosing recommendations follow: 200 mg IV Day 1, repeat every 3 weeks or 400 mg IV Day 1, repeat every 6 weeks until disease progression, unacceptable toxicity, or up to 24 months for treatment of patients with MSI-H bone cancer.*

[Continued](#)

UPDATES



Updates in Version 1.2021 of the NCCN Guidelines for Bone Cancer from Version 1.2020 include:

[BONE-B \(1 of 5\)](#) (continued)

Bone Cancer Systemic Therapy Agents

- **Pembrolizumab for TMB-H (≥ 10 mutations/megabase) Tumors** is new to the page, with the following footnote: *TMB-H for patients with unresectable or metastatic tumors who have progressed following prior treatment and who have no satisfactory alternative treatment options. Not for Giant Cell Tumor of Bone.*
- The following references for Pembrolizumab for TMB-H (≥ 10 mutations/megabase) Tumors are new:
 - ▶ *Marabelle A, Fakih M, Lopez J, et al. Association of tumour mutational burden with outcomes in patients with advanced solid tumours treated with pembrolizumab: prospective biomarker analysis of the multicohort, open-label, phase 2 KEYNOTE-158 study. Lancet Oncol 2020;21:1353-1365.*
 - ▶ *Merino DM, McShane LM, Fabrizio D, et al. Establishing guidelines to harmonize tumor mutational burden (TMB): in silico assessment of variation in TMB quantification across diagnostic platforms: phase I of the Friends of Cancer Research TMB Harmonization Project. J Immunother Cancer 2020;8:e000147.*
- **Chondrosarcoma**
 - ▶ **Pazopanib** for metastatic and widespread disease is new to the page under, Other Recommended Regimens
 - ◊ Corresponding footnote: *Chow W, Frankel P, Ruel C, et al. Results of a prospective phase 2 study of pazopanib in patients with surgically unresectable or metastatic chondrosarcoma. Cancer 2020;126:105-111.*
 - ▶ **Ivosidenib (for susceptible IDH1 mutations)** for conventional (Grades 1–3) is new to the page under, Useful in Certain Circumstances
 - ▶ **Ivosidenib (for susceptible IDH1 mutations)** for dedifferentiated chondrosarcoma is new to the page under, Useful in certain circumstances
 - ◊ Corresponding footnote: *Tap WD, Villalobos VM, Cote GM et al. Phase I study of the mutant IDH1 inhibitor ivosidenib: safety and clinical activity in patients with advanced chondrosarcoma. J Clin Oncol 2020;38:1693-1701.*

[BONE-B \(2 of 5\)](#)

Bone Cancer Systemic Therapy Agents

- **Ewing Sarcoma**
 - ▶ Category 1 designation deleted for VIDE (vincristine, ifosfamide, doxorubicin, and etoposide) for first-line therapy (primary/neoadjuvant/ adjuvant therapy under Other recommended regimens.
 - ▶ "Ifosfamide (high-dose) \pm etoposide" deleted for second-line therapy

(relapsed/refractory or metastatic disease) under Preferred regimens.

- ▶ **Cabozantinib** for second-line therapy (relapsed/refractory or metastatic disease) under Other Recommended Regimens is new (Also for Osteosarcoma, [BONE-B 3 of 6](#)).
- ▶ Footnote "++++", Vincristine could be added to these regimens, applies to the following:
 - ◊ Cyclophosphamide and topotecan
 - ◊ Irinotecan + temozolomide \pm vincristine
 - ◊ Docetaxel and gemcitabine
 - ◊ Ifosfamide, carboplatin, and etoposide

[BONE-B \(3 of 5\)](#)

Bone Cancer Systemic Therapy Agents

- **Osteosarcoma**
 - ▶ Footnote "++++" is new to the page, *In the event a patient receiving high-dose methotrexate experiences delayed elimination due to renal impairment, glucarpidase is strongly recommended, corresponding to the following:*
 - ◊ MAP (high-dose methotrexate, cisplatin, and doxorubicin)
 - ◊ Doxorubicin, cisplatin, ifosfamide, and high-dose methotrexate
 - ◊ High-dose methotrexate
 - ◊ High-dose methotrexate, etoposide, and ifosfamide
 - ▶ Sorafenib + everolimus (category 2B) moved from Preferred Regimens to Other Recommended Regimens.

[BONE-C \(5 of 5\)](#)

Principles of Radiation Therapy

- **Chordoma**
 - ▶ *Sebro R, DeLaney TF, Hornicek F, et al. Frequency and risk factors for additional lesions in the axial spine in subjects with chordoma: Indications for screening. Spine (Phila Pa 1976) 2017;42(1):E37-E40.*

[MS-1](#)

- The Discussion has been updated to reflect the changes in the algorithm.



MULTIDISCIPLINARY TEAM

Primary bone tumors and selected metastatic tumors should be evaluated and treated by a multidisciplinary team with expertise in the management of these tumors. The team should meet on a regular basis and should include:

Core Group

- Orthopedic oncologist
- Bone pathologist
- Medical/pediatric oncologist
- Radiation oncologist
- Musculoskeletal radiologist

Specialists Critical in Certain Cases

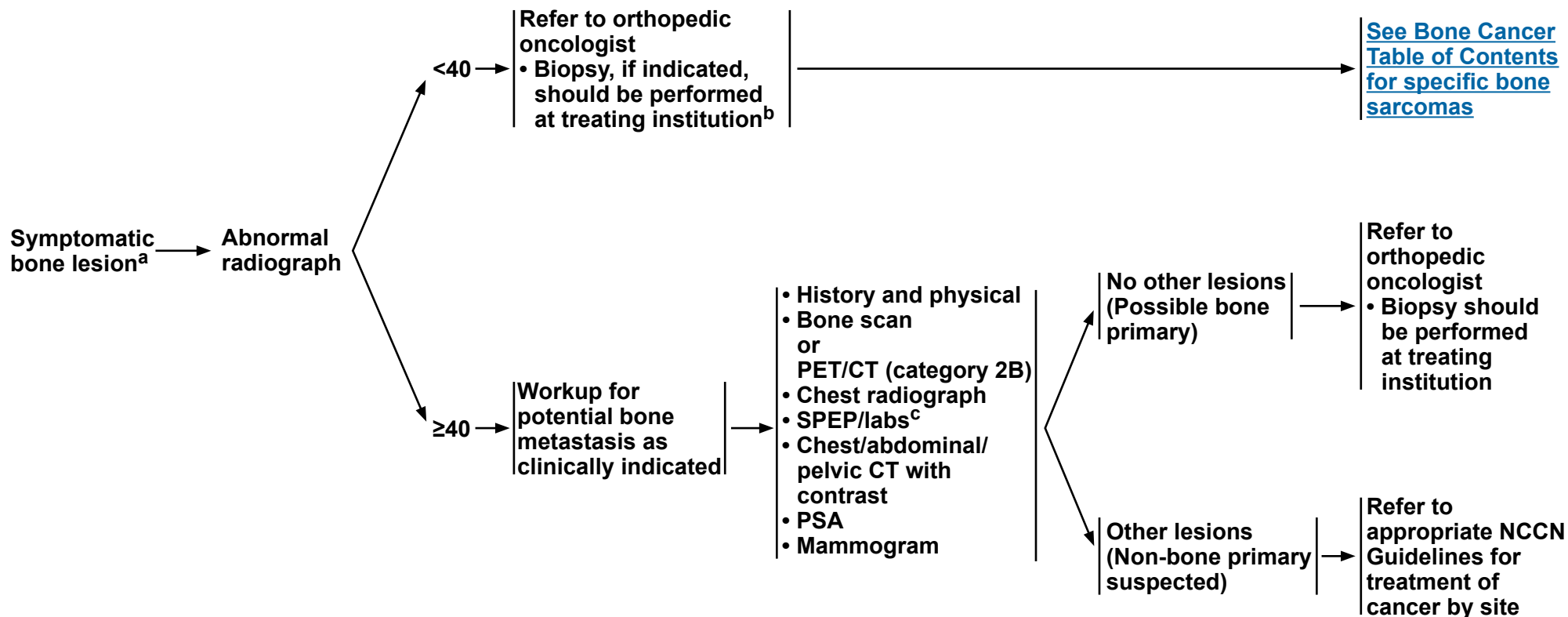
- Thoracic surgeon
- Plastic surgeon
- Interventional radiologist
- Physiatrist
- Vascular/general surgeon
- Neurosurgeon/orthopedic spine surgeon
- Additional surgical subspecialties as clinically indicated

Note: All recommendations are category 2A unless otherwise indicated.

Clinical Trials: NCCN believes that the best management of any patient with cancer is in a clinical trial. Participation in clinical trials is especially encouraged.



WORKUP



^aSee [Multidisciplinary Team \(TEAM-1\)](#).

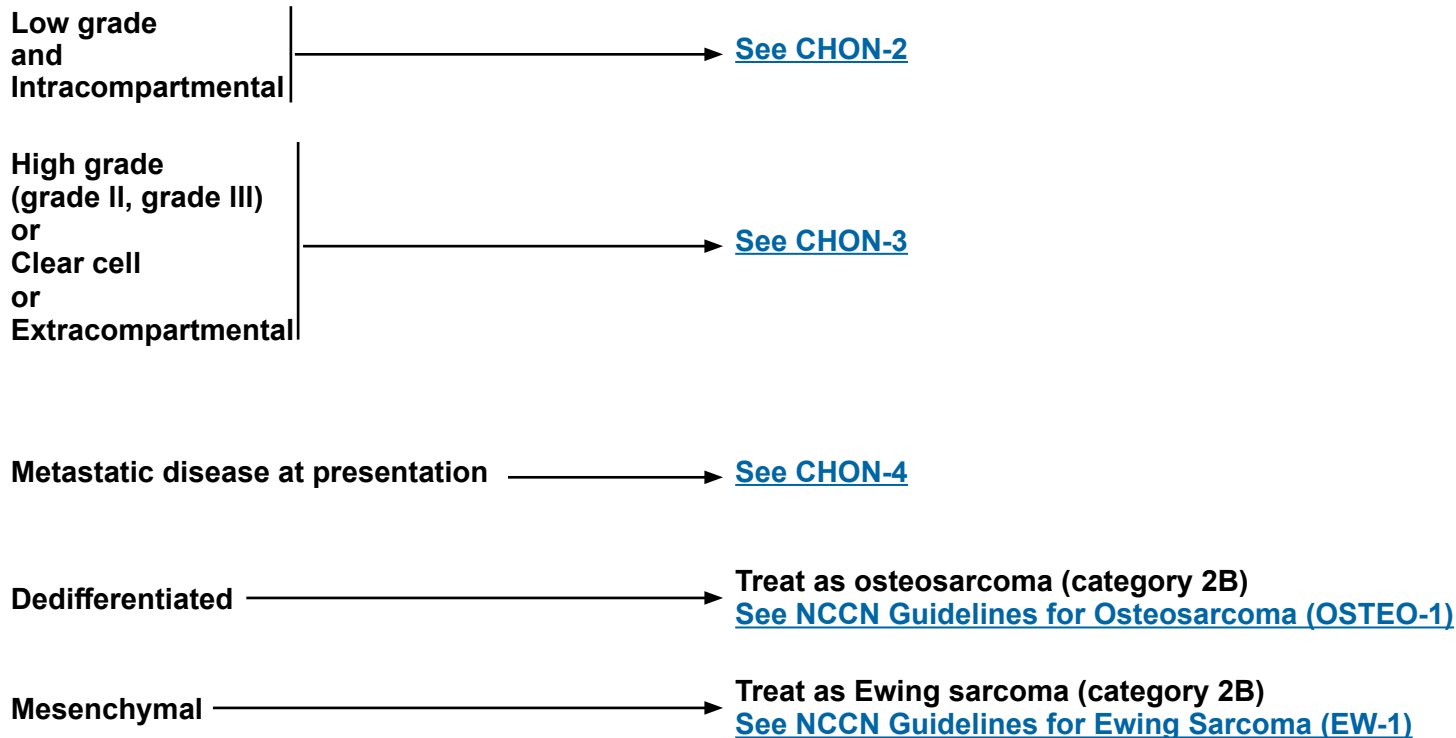
^bSee [Principles of Bone Cancer Management \(BONE-A\)](#).

^cLabs include CBC and comprehensive metabolic panel (CMP) with calcium to assess for hypercalcemia.

Note: All recommendations are category 2A unless otherwise indicated.
Clinical Trials: NCCN believes that the best management of any patient with cancer is in a clinical trial. Participation in clinical trials is especially encouraged.



PRESENTATION^{a,b,c}



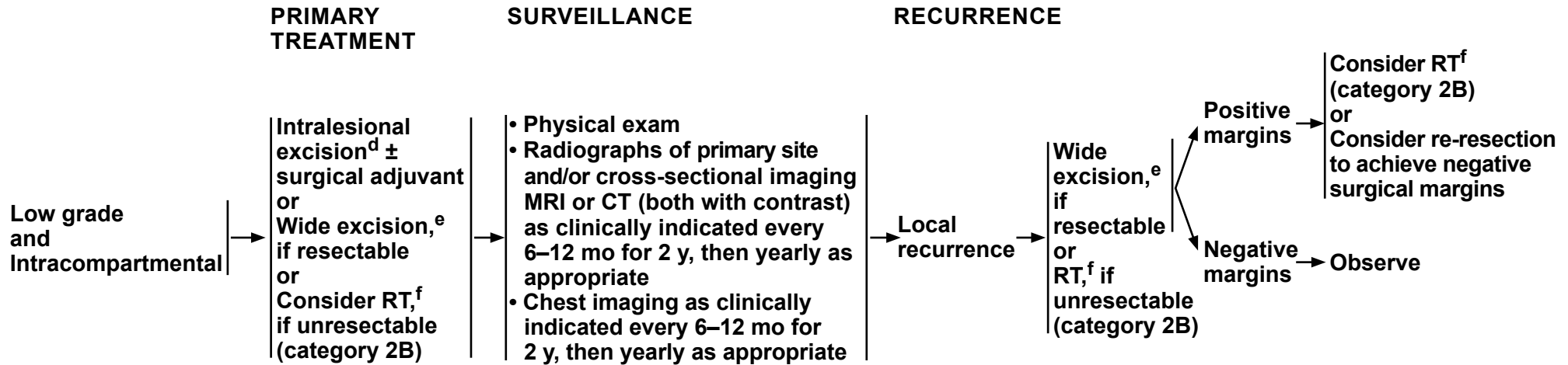
^a[See Multidisciplinary Team \(TEAM-1\)](#).

^b[See Principles of Bone Cancer Management \(BONE-A\)](#).

^cThere is considerable controversy regarding the grading of chondrosarcoma. In addition to histology, radiologic features, size, and location of tumors should also be considered in deciding local treatment.

Note: All recommendations are category 2A unless otherwise indicated.

Clinical Trials: NCCN believes that the best management of any patient with cancer is in a clinical trial. Participation in clinical trials is especially encouraged.



^dThis management should be restricted to extremity tumors (not pelvic tumors).

^eWide excision should provide histologically negative surgical margins. This may be achieved by either limb-sparing resection or limb amputation.

^f[See Principles of Radiation Therapy \(BONE-C\)](#).

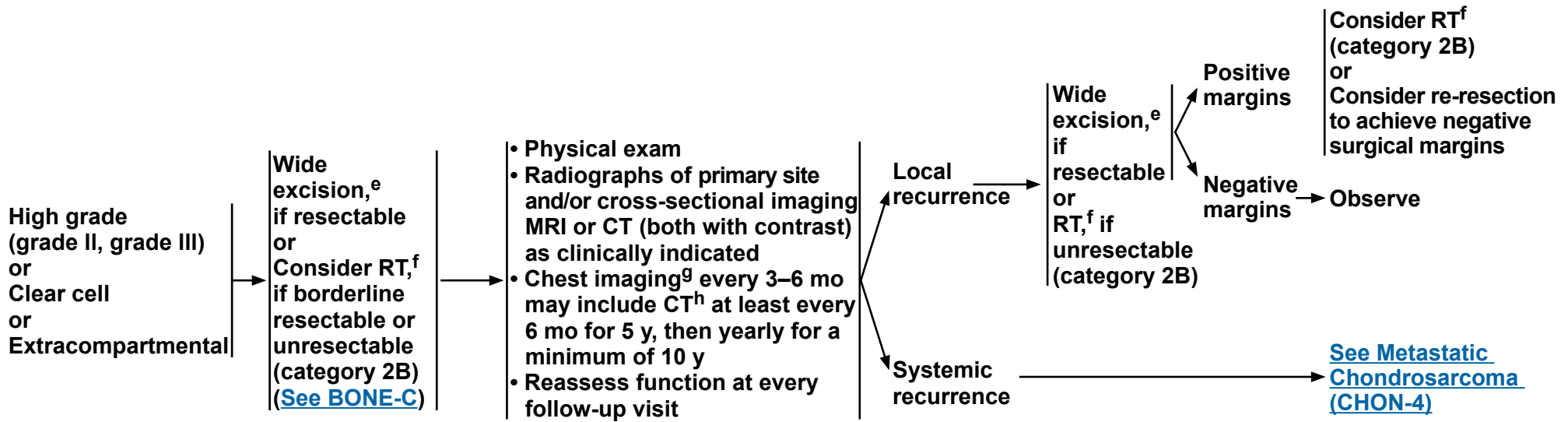
Note: All recommendations are category 2A unless otherwise indicated.
Clinical Trials: NCCN believes that the best management of any patient with cancer is in a clinical trial. Participation in clinical trials is especially encouraged.



PRIMARY TREATMENT

SURVEILLANCE

RECURRENCE



^eWide excision should provide histologically negative surgical margins. This may be achieved by either limb-sparing resection or limb amputation.

^f[See Principles of Radiation Therapy \(BONE-C\)](#).

^gBased on physician's concern for risk of recurrence.

^hChest CT with or without contrast as clinically indicated.

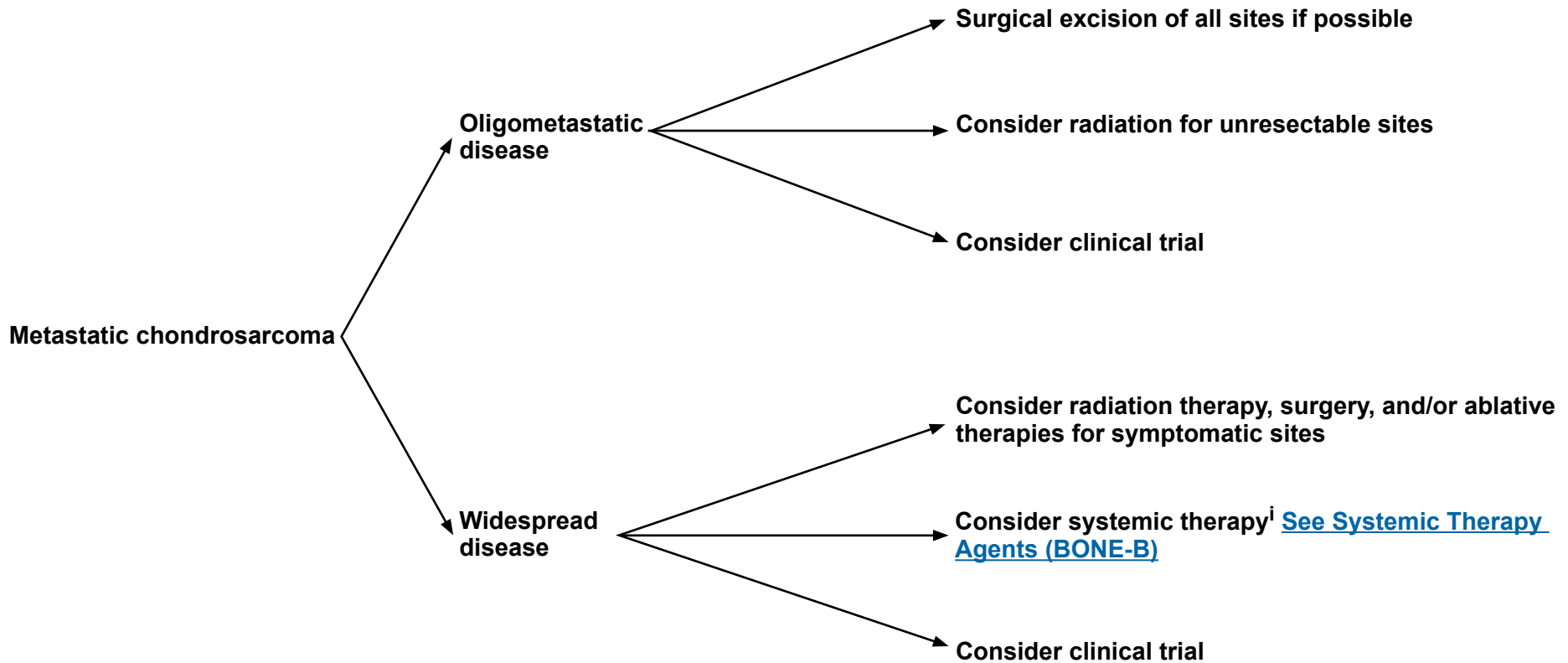
Note: All recommendations are category 2A unless otherwise indicated.

Clinical Trials: NCCN believes that the best management of any patient with cancer is in a clinical trial. Participation in clinical trials is especially encouraged.



METASTATIC CHONDROSARCOMA

Dedifferentiated [See OSTE0-1](#)
Mesenchymal [See EW-1](#)



ⁱConsider testing for tumor mutational burden (TMB) as determined by a validated and/or FDA-approved assay to inform the use of pembrolizumab.

Note: All recommendations are category 2A unless otherwise indicated.
Clinical Trials: NCCN believes that the best management of any patient with cancer is in a clinical trial. Participation in clinical trials is especially encouraged.



WORKUP^a

- All patients should be evaluated and treated by a multidisciplinary team with expertise in the management of chordoma^a
- History and physical
- Adequate imaging of primary site (eg, x-ray, CT +/- MRI) and screening MRI of spinal axis (CT/MRI with contrast)
- Chest/abdominal/pelvic CT with contrast
- Consider PET/CT (skull base to mid-thigh)
- Consider bone scan if PET/CT is negative

HISTOLOGIC SUBTYPE

Conventional
or
Chondroid

[See Presentation and Primary Treatment \(CHOR-2\)](#)

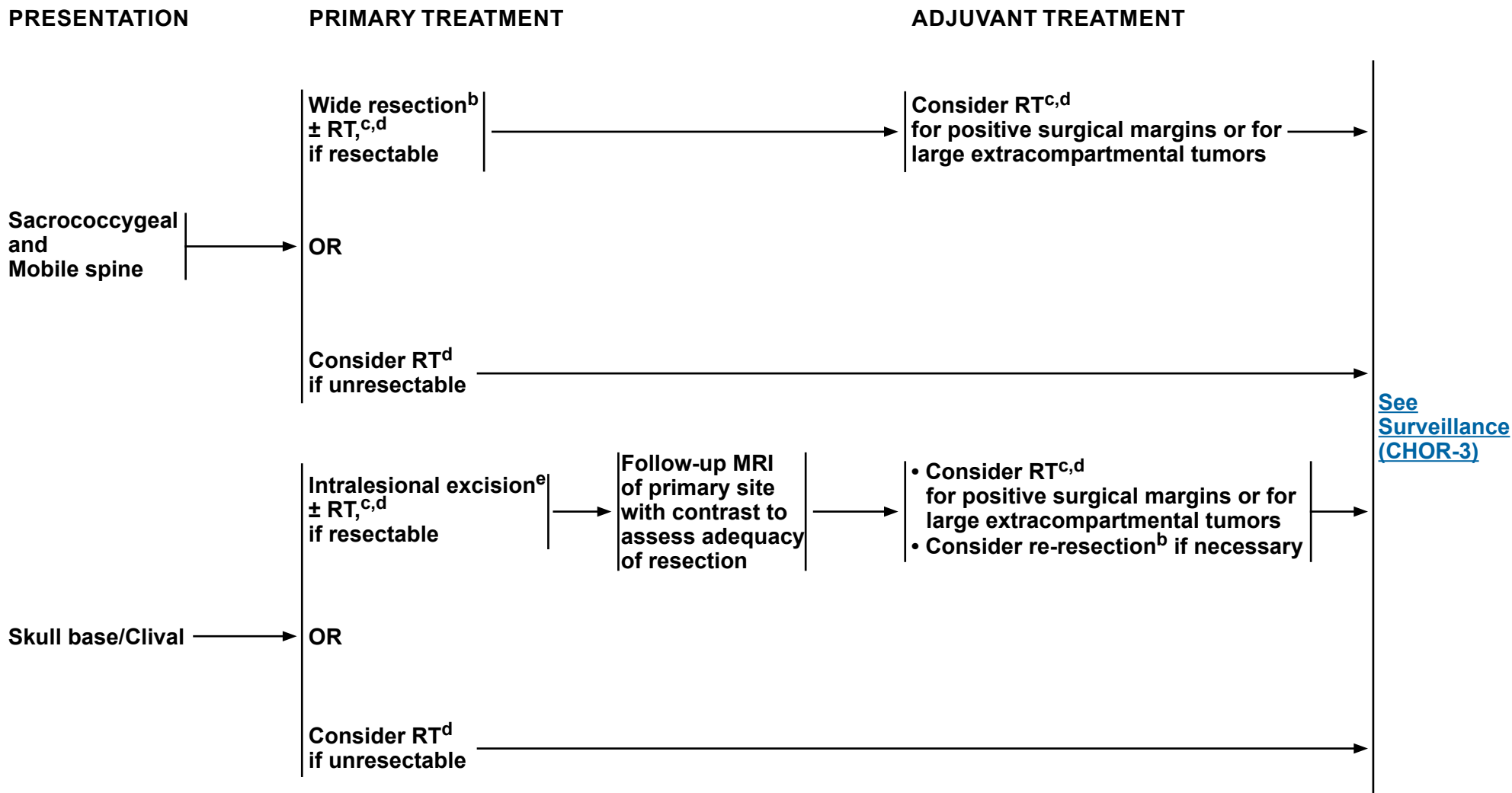
Poorly differentiated
or
Dedifferentiated

[See NCCN Guidelines for Soft Tissue Sarcoma](#)

^a[See Multidisciplinary Team \(TEAM-1\)](#).

Note: All recommendations are category 2A unless otherwise indicated.

Clinical Trials: NCCN believes that the best management of any patient with cancer is in a clinical trial. Participation in clinical trials is especially encouraged.



^bSee Principles of Bone Cancer Management (BONE-A).

^cRadiation therapy may be given preoperatively, intraoperatively, and/or postoperatively.

^dSee Principles of Radiation Therapy (BONE-C).

^eMaximal safe resection. Maximal tumor removal is recommended when appropriate.

Note: All recommendations are category 2A unless otherwise indicated.

Clinical Trials: NCCN believes that the best management of any patient with cancer is in a clinical trial. Participation in clinical trials is especially encouraged.



SURVEILLANCE

- Physical exam
- Imaging of surgical site, timing, and modality, as clinically indicated (eg, x-ray, CT with contrast +/- MRI with contrast) for up to 10 y
- Chest imaging^f every 6 mo may include CT annually for 5 y, then annually thereafter

RECURRENCE

Local recurrence

Metastatic recurrence

TREATMENT

Surgical excision^b
and/or
RT^d
and/or
Systemic therapy^g

Systemic therapy^{g,h}
and/or
Surgical excision^b
and/or
RT^d
and/or
Best supportive care

^bSee [Principles of Bone Cancer Management \(BONE-A\)](#).

^dSee [Principles of Radiation Therapy \(BONE-C\)](#).

^fChest CT with or without contrast as clinically indicated.

^gSee [Bone Cancer Systemic Therapy Agents \(BONE-B\)](#).

^hConsider testing for TMB as determined by a validated and/or FDA-approved assay to inform the use of pembrolizumab.

Note: All recommendations are category 2A unless otherwise indicated.

Clinical Trials: NCCN believes that the best management of any patient with cancer is in a clinical trial. Participation in clinical trials is especially encouraged.

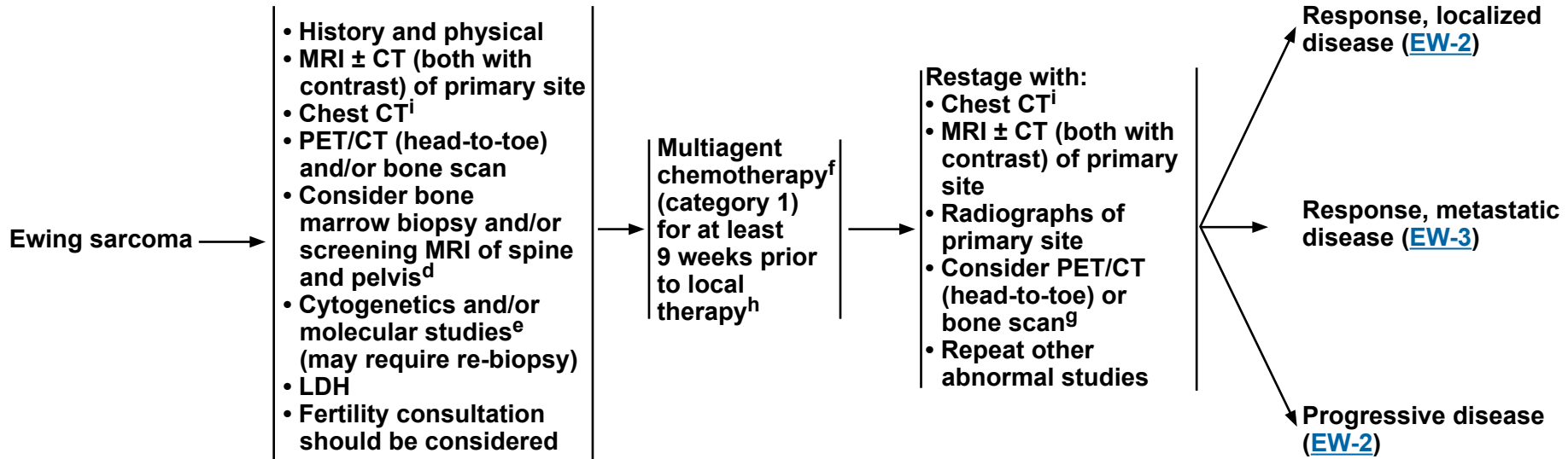


PRESENTATION^{a,b,c}

WORKUP

**PRIMARY
TREATMENT**

RESTAGE



^aSee [Multidisciplinary Team \(TEAM-1\)](#).

^bSee [Principles of Bone Cancer Management \(BONE-A\)](#).

^cEwing sarcoma can be treated using this algorithm, including primitive neuroectodermal tumor of bone, Askin tumor, and extrasosseous Ewing sarcoma.

^dKopp L, et al. *Pediatr Blood Cancer* 2015;62:12-15.

^eNinety percent of Ewing sarcoma will have one of four specific cytogenetic translocations. For patients with Ewing-like sarcoma (eg, CIC-DUX4) an alternate treatment paradigm can be considered. For those who are negative, additional molecular testing is recommended.

^fSee [Bone Cancer Systemic Therapy Agents \(BONE-B\)](#).

^gUse the same imaging technique that was performed in the initial workup.

^hLonger treatment prior to local control therapy can be considered in patients with metastatic disease based on response.

ⁱChest CT with or without contrast as clinically indicated.

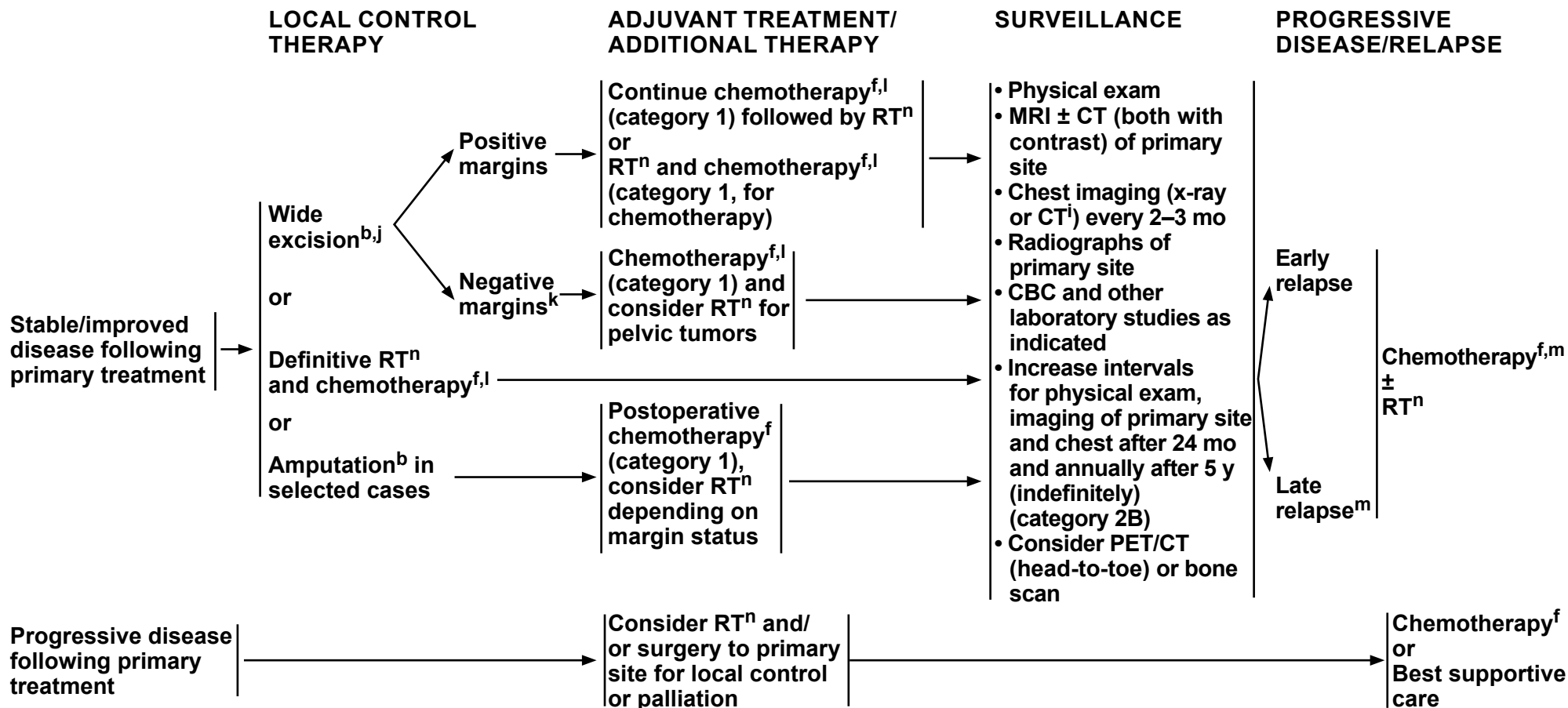
Note: All recommendations are category 2A unless otherwise indicated.

Clinical Trials: NCCN believes that the best management of any patient with cancer is in a clinical trial. Participation in clinical trials is especially encouraged.



NCCN Guidelines Version 1.2021

Ewing Sarcoma



^bSee Principles of Bone Cancer Management (BONE-A).

^fSee Bone Cancer Systemic Therapy Agents (BONE-B).

ⁱChest CT with or without contrast as clinically indicated.

^jConsider preoperative RT for marginally resectable lesions.

^kRT may be considered for close margins.

^lThere is category 1 evidence for between 28 and 49 weeks of chemotherapy depending on the chemotherapy and dosing schedule used.

^mFor late relapse, consider re-treatment with previously effective regimen.

ⁿSee Principles of Radiation Therapy (BONE-C).

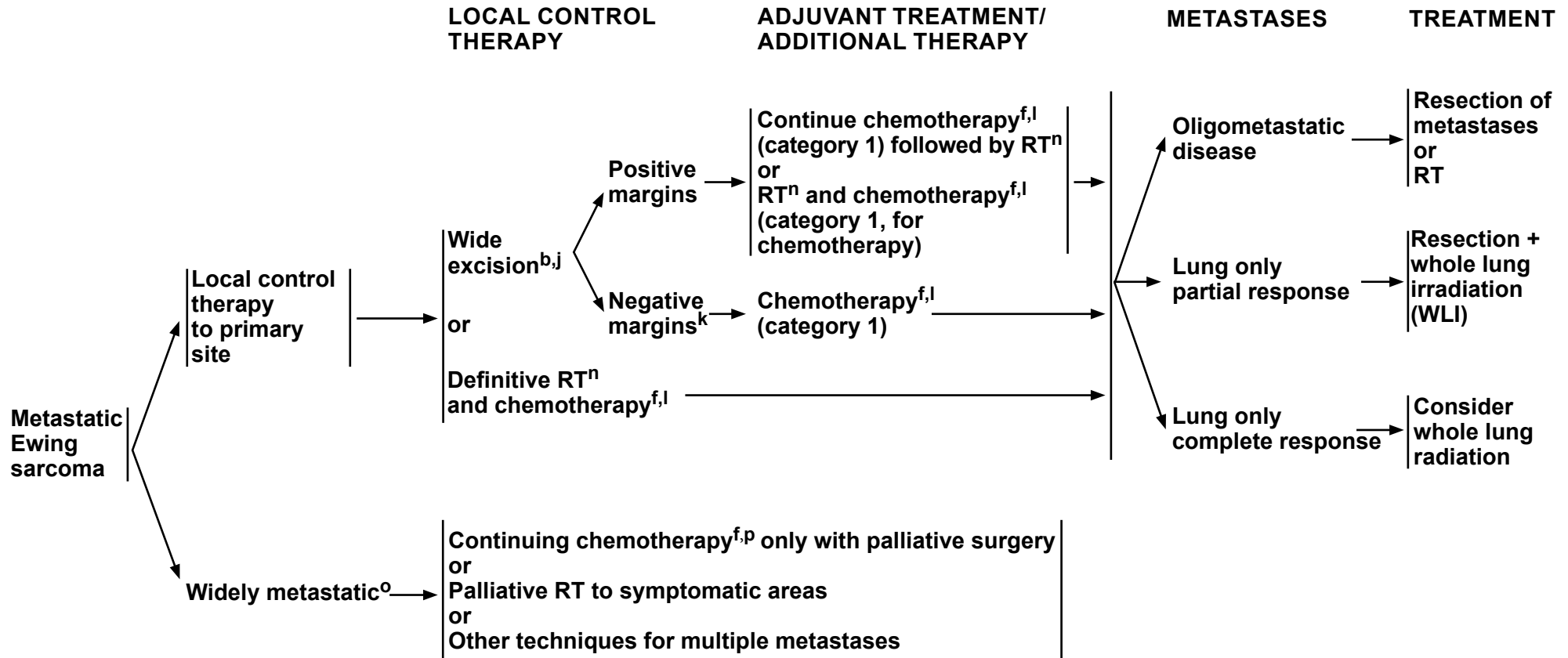
Note: All recommendations are category 2A unless otherwise indicated.

Clinical Trials: NCCN believes that the best management of any patient with cancer is in a clinical trial. Participation in clinical trials is especially encouraged.



NCCN Guidelines Version 1.2021

Ewing Sarcoma



^bSee Principles of Bone Cancer Management (BONE-A).

^fSee Bone Cancer Systemic Therapy Agents (BONE-B).

^jConsider preoperative RT for marginally resectable lesions.

^kRT may be considered for close margins.

^lThere is category 1 evidence for between 28 and 49 weeks of chemotherapy depending on the chemotherapy and dosing schedule used.

ⁿSee Principles of Radiation Therapy (BONE-C).

^oLocal control cannot be delivered to all areas of disease.

^pConsider testing for TMB as determined by a validated and/or FDA-approved assay to inform the use of pembrolizumab (category 2B).

Note: All recommendations are category 2A unless otherwise indicated.
Clinical Trials: NCCN believes that the best management of any patient with cancer is in a clinical trial. Participation in clinical trials is especially encouraged.



WORKUP

- History and physical examination
- Imaging of primary site as clinically indicated (eg, x-ray, CT with contrast ± MRI with contrast)
- Chest imaging
- Bone scan (optional)
- Biopsy to confirm diagnosis^{a,b}
- If there is malignant transformation, treat as described for osteosarcoma ([See OSTEO-1](#))

PRESENTATION

Localized disease → [See GCTB-2](#)

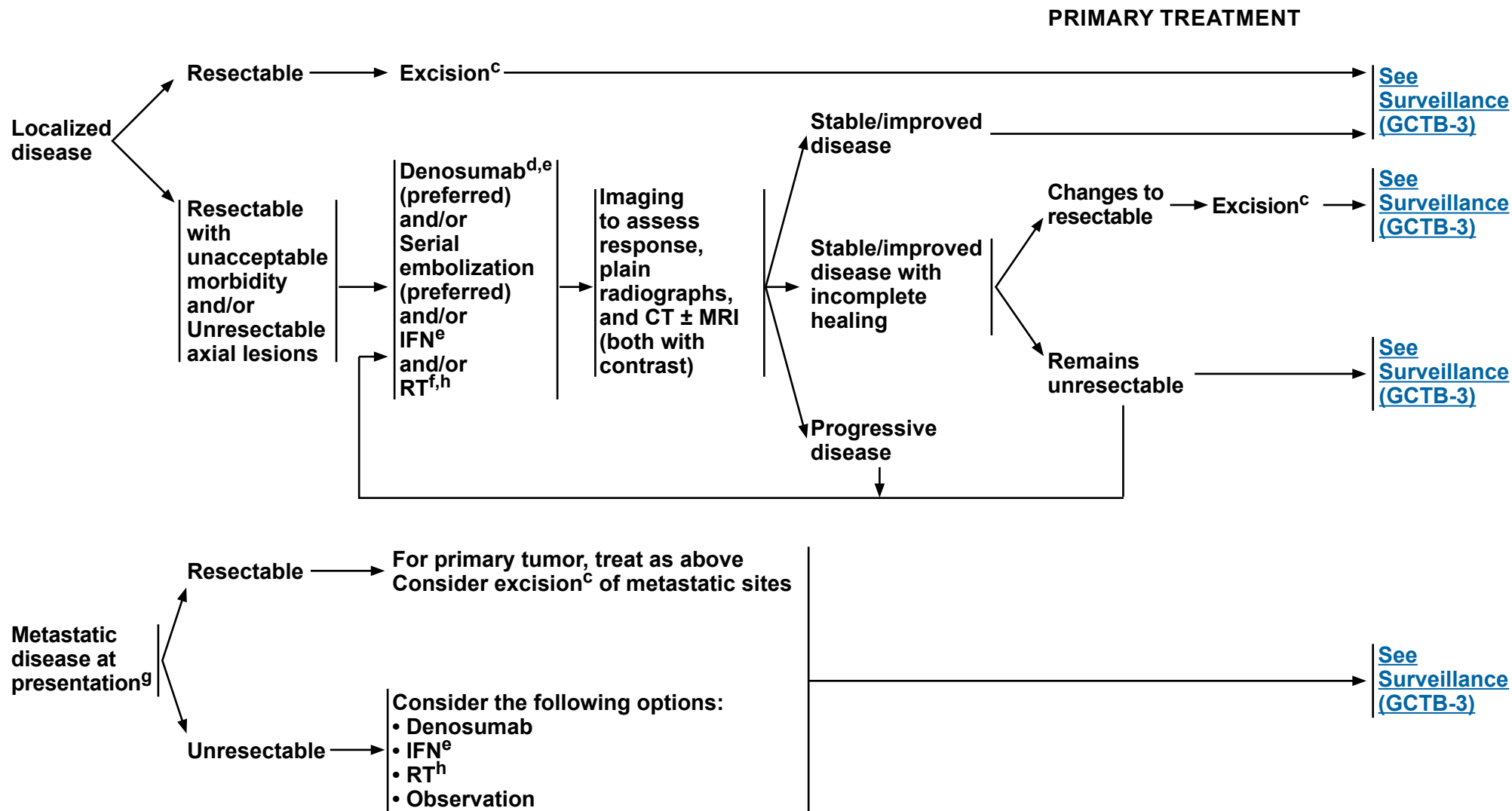
Metastatic disease at presentation → [See GCTB-2](#)

^aBrown tumor of hyperparathyroidism should be considered as a differential diagnosis.

^b[See Principles of Bone Cancer Management \(BONE-A\)](#).

Note: All recommendations are category 2A unless otherwise indicated.

Clinical Trials: NCCN believes that the best management of any patient with cancer is in a clinical trial. Participation in clinical trials is especially encouraged.



^cIntralesional excision with an effective adjuvant is adequate.

^dDenosumab should be continued until disease progression in responding disease.

^e[See Bone Cancer Systemic Therapy Agents \(BONE-B\).](#)

^fRT may be associated with increased risk of malignant transformation.

^gTreatment of primary tumor is as described for localized disease.

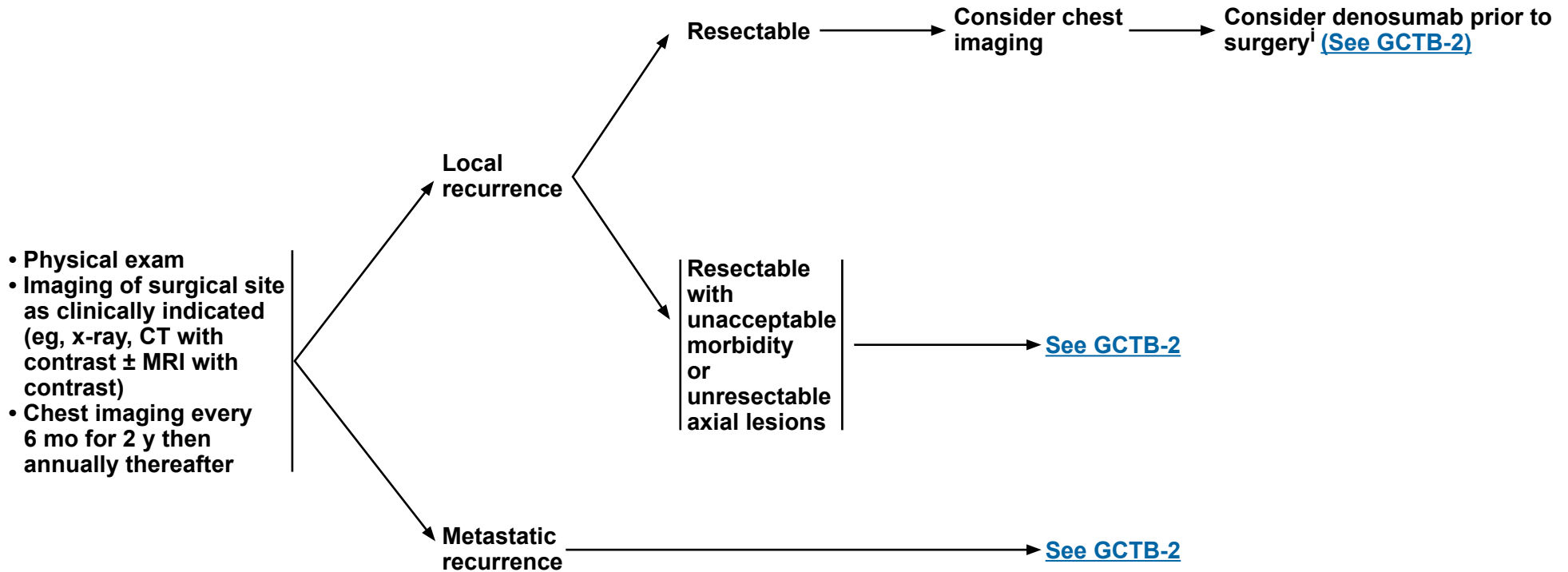
^h[See Principles of Radiation Therapy \(BONE-C\).](#)

Note: All recommendations are category 2A unless otherwise indicated.
Clinical Trials: NCCN believes that the best management of any patient with cancer is in a clinical trial. Participation in clinical trials is especially encouraged.



SURVEILLANCE

RECURRENCE



Risk of local recurrence is increased when denosumab is used prior to curettage. Denosumab may be beneficial to define peripheral tumor extent when planning wide resection.

Note: All recommendations are category 2A unless otherwise indicated.
Clinical Trials: NCCN believes that the best management of any patient with cancer is in a clinical trial. Participation in clinical trials is especially encouraged.



NCCN Guidelines Version 1.2021 Osteosarcoma

WORKUP^{a,b}

- History and physical
- MRI ± CT (both with contrast) of primary site
- Chest imaging including chest CT^c
- PET/CT (head-to-toe) and/or bone scan
- MRI or CT (both with contrast) of skeletal metastatic sites^f
- LDH
- ALP
- Fertility consultation should be considered
- Consider personal and family history for genetic consultation and testing

Low-grade osteosarcoma:^d
Intramedullary + surface

Wide excision^b

High grade

Chemotherapy^e

Periosteal osteosarcoma

Consider chemotherapy^e

Wide excision^b

Low grade

[See Surveillance \(OSTEO-4\)](#)

High-grade osteosarcoma:
Intramedullary + surface

[OSTEO-2](#)

Metastatic disease at presentation

[OSTEO-3](#)

Extraskeletal osteosarcoma

[See NCCN Guidelines for Soft Tissue Sarcoma](#)

^aSee [Multidisciplinary Team \(TEAM-1\)](#).

^bSee [Principles of Bone Cancer Management \(BONE-A\)](#).

^cChest CT with or without contrast as clinically indicated.

^dDedifferentiated parosteal osteosarcomas are not considered to be low-grade tumors.

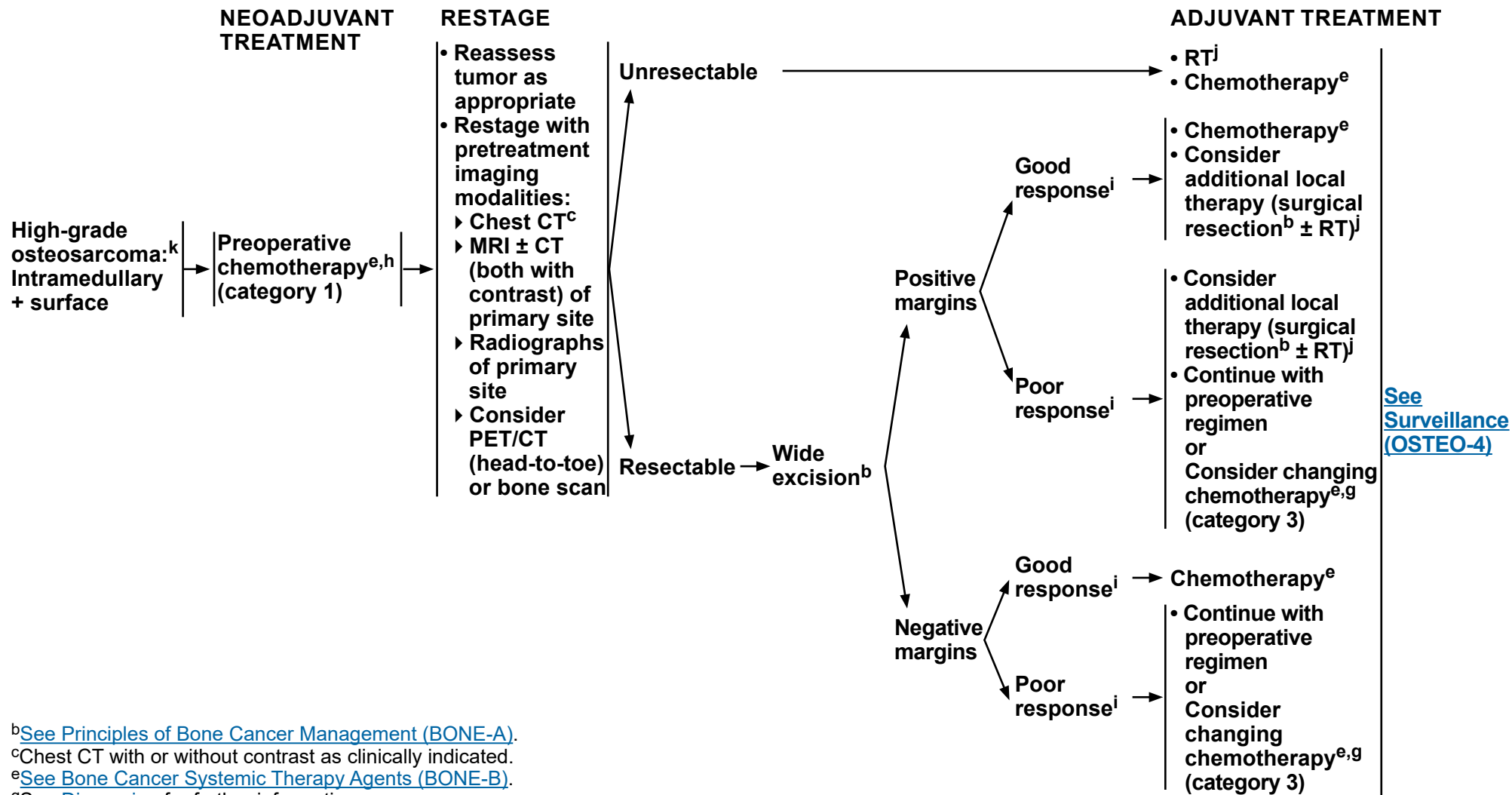
^eSee [Bone Cancer Systemic Therapy Agents \(BONE-B\)](#).

^fMore detailed imaging (CT or MRI) of abnormalities identified on primary imaging is required for suspected metastatic disease.

Note: All recommendations are category 2A unless otherwise indicated.
Clinical Trials: NCCN believes that the best management of any patient with cancer is in a clinical trial. Participation in clinical trials is especially encouraged.



NCCN Guidelines Version 1.2021 Osteosarcoma



[See Surveillance \(OSTEO-4\)](#)

^bSee [Principles of Bone Cancer Management \(BONE-A\)](#).

^cChest CT with or without contrast as clinically indicated.

^eSee [Bone Cancer Systemic Therapy Agents \(BONE-B\)](#).

^gSee [Discussion](#) for further information.

^hSelected elderly patients may benefit from immediate surgery.

ⁱResponse is defined by pathologic mapping per institutional guidelines; the amount of viable tumor is reported as <10% of the tumor area in cases showing a good response and ≥10% in cases showing a poor response.

^jSee [Principles of Radiation Therapy \(BONE-C\)](#).

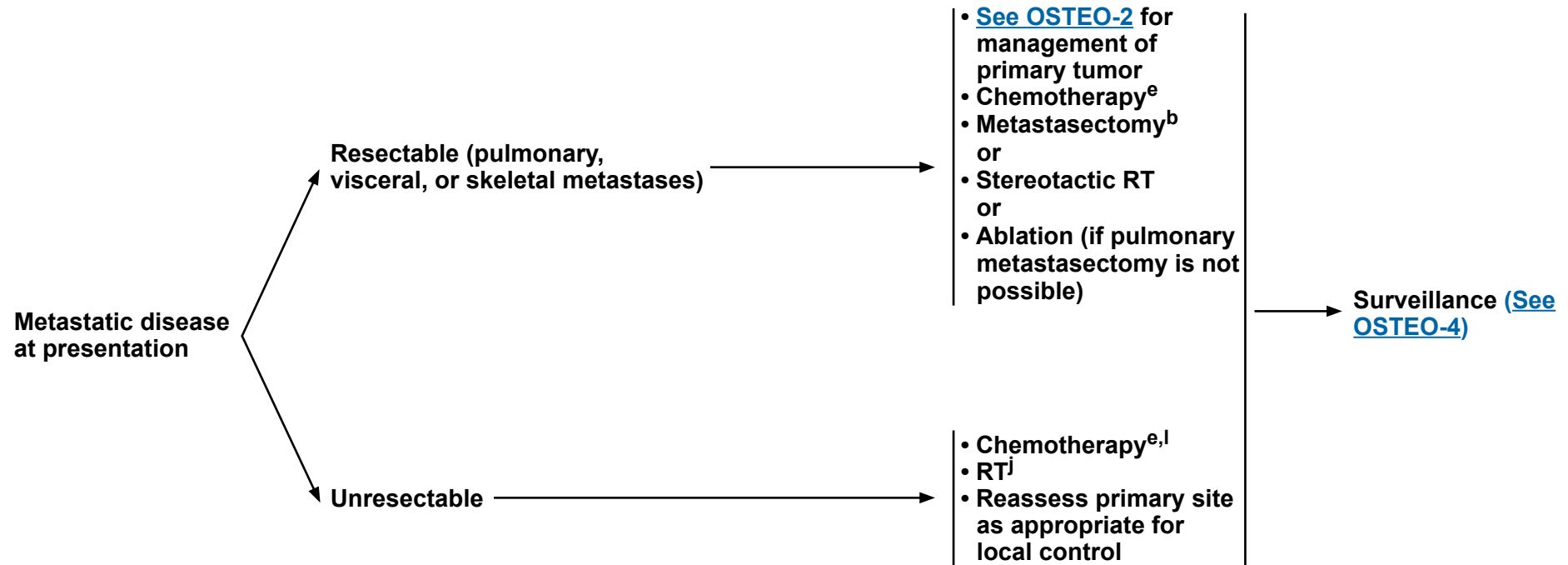
^kOther high-grade non-osteosarcoma variants such as undifferentiated pleomorphic sarcoma (UPS) of bone could also be treated using this algorithm.

Note: All recommendations are category 2A unless otherwise indicated.
Clinical Trials: NCCN believes that the best management of any patient with cancer is in a clinical trial. Participation in clinical trials is especially encouraged.



PRESENTATION

PRIMARY TREATMENT



^bSee [Principles of Bone Cancer Management \(BONE-A\)](#).

^eSee [Bone Cancer Systemic Therapy Agents \(BONE-B\)](#).

^jSee [Principles of Radiation Therapy \(BONE-C\)](#).

^lConsider testing for TMB as determined by a validated and/or FDA-approved assay to inform the use of pembrolizumab.

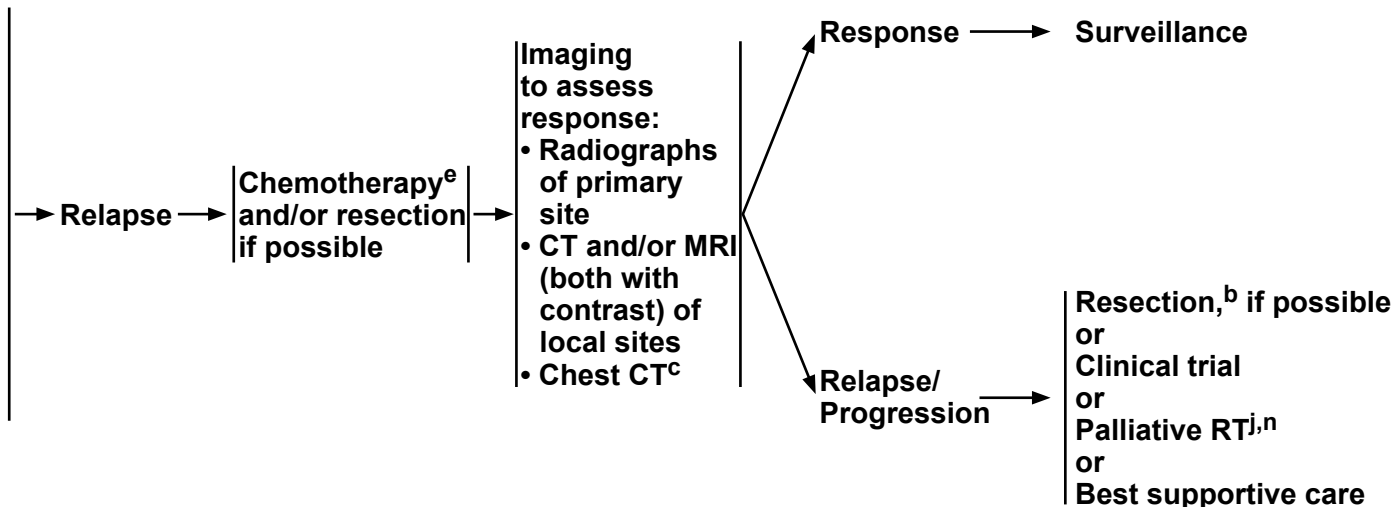
Note: All recommendations are category 2A unless otherwise indicated.

Clinical Trials: NCCN believes that the best management of any patient with cancer is in a clinical trial. Participation in clinical trials is especially encouraged.

SURVEILLANCE

RELAPSE

- Physical exam, imaging of primary site and chest^m
- Follow-up schedule: (Orthopedic and oncologic)
 - ▶ Every 3 mo for y 1 and 2
 - ▶ Every 4 mo for y 3
 - ▶ Every 6 mo for y 4 and 5 and yearly thereafter
- CBC and other laboratory studies as clinically indicated
- Consider PET/CT (head-to-toe) and/or bone scan (category 2B)
- Reassess function every visit



^bSee [Principles of Bone Cancer Management \(BONE-A\)](#).

^cChest CT with or without contrast as clinically indicated.

^eSee [Bone Cancer Systemic Therapy Agents \(BONE-B\)](#).

^jSee [Principles of Radiation Therapy \(BONE-C\)](#).

^mUse the same imaging technique that was performed in the initial workup.

ⁿMay include samarium.

Note: All recommendations are category 2A unless otherwise indicated.
Clinical Trials: NCCN believes that the best management of any patient with cancer is in a clinical trial. Participation in clinical trials is especially encouraged.



PRINCIPLES OF BONE CANCER MANAGEMENT

Biopsy

- Prior to biopsy, consultation should be obtained with an orthopedic oncologist regarding appropriate prebiopsy imaging.
- Preoperative biopsy consultation with pediatric oncologist as appropriate is recommended for children.
- Biopsy diagnosis is necessary prior to any surgical procedure or fixation of primary site.
- Biopsy is optimally performed at a center that will do definitive management.
- Placement of biopsy is critical.
- Biopsy should be core needle or surgical biopsy.
- Technique: Apply same principles for core needle or open biopsy. Needle biopsy is not recommended for skull base tumors.
- Appropriate communication between the surgeon, musculoskeletal radiologist, and bone pathologist is critical.
- Fresh tissue may be needed for molecular studies and tissue banking.
- In general, failure to follow appropriate biopsy procedures may lead to adverse patient outcomes.

Surgery

- Wide excision should achieve histologically negative surgical margins.
- Negative surgical margins optimize local tumor control.
- Local tumor control may be achieved by either limb-sparing resection or limb amputation (individualized for a given patient).
- Limb-sparing resection is preferred to optimize function if reasonable functional expectations can be achieved.
- Final pathologic evaluation should include assessment of surgical margins, size/dimensions of tumor, and response to preoperative therapy.

Lab Studies

- Lab studies such as CBC, LDH, and ALP may have relevance in the diagnosis, prognosis, and management of bone sarcoma patients and should be done prior to definitive treatment and periodically during treatment and surveillance.

Treatment

- Fertility issues should be addressed with patients prior to commencing chemotherapy.
- [See NCCN Guidelines for Adolescent and Young Adult \(AYA\) Oncology.](#)
- Select patients with osteosarcoma or chondrosarcoma may benefit from a referral for genetic consultation and testing based on family history with a genetic predisposition for bone sarcomas.
- Care for patients with bone cancer should be delivered directly by physicians on the multidisciplinary team (category 1).
[See TEAM-1.](#)

Long-Term Follow-up and Surveillance/Survivorship

- Patients should have a survivorship prescription to schedule follow-up with a multidisciplinary team.
- Life-long follow-up is recommended for surveillance and treatment of late effects of surgery, radiation, and chemotherapy in long-term survivors.

Note: All recommendations are category 2A unless otherwise indicated.

Clinical Trials: NCCN believes that the best management of any patient with cancer is in a clinical trial. Participation in clinical trials is especially encouraged.

**SYSTEMIC THERAPY AGENTS**

MSI-H/dMMR Tumors
Preferred Regimen • Pembrolizumab ^{1,2,†}
TMB-H (≥10 mutations/megabase) Tumors
Useful in Certain Circumstances • Pembrolizumab ^{3,4,††}

Chondrosarcoma	
Metastatic and widespread disease	Other Recommended Regimens • Dasatinib ^{5,6} • Pazopanib ⁷
Conventional (Grades 1–3)	Preferred Regimens • No known standard chemotherapy options Useful in Certain Circumstances • Ivosidenib ⁸ (for susceptible <i>IDH1</i> mutations)
Dedifferentiated	Preferred Regimens • Follow osteosarcoma regimens (category 2B) Useful in Certain Circumstances • Ivosidenib ⁸ (for susceptible <i>IDH1</i> mutations)
Mesenchymal	Preferred Regimens • Follow Ewing sarcoma regimens (category 2B)

[†]Pembrolizumab is a systemic treatment option for adult and pediatric patients with unresectable or metastatic, microsatellite instability-high (MSI-H) or mismatch repair deficient (dMMR) solid tumors that have progressed following prior treatment and who have no satisfactory alternative treatment options. Additional dosing recommendations follow: 200 mg IV Day 1, repeat every 3 weeks or 400 mg IV Day 1, repeat every 6 weeks until disease progression, unacceptable toxicity, or up to 24 months for treatment of patients with MSI-H bone cancer. Not for Giant Cell Tumor of Bone or Chordoma.

^{††}TMB-H for patients with unresectable or metastatic tumors who have progressed following prior treatment and who have no satisfactory alternative treatment options. Not for Giant Cell Tumor of Bone.

Note: All recommendations are category 2A unless otherwise indicated.

Clinical Trials: NCCN believes that the best management of any patient with cancer is in a clinical trial. Participation in clinical trials is especially encouraged.

[References](#)

**SYSTEMIC THERAPY AGENTS**

Chordoma
Other Recommended Regimens
<ul style="list-style-type: none"> • Imatinib^{9,10,11} • Dasatinib^{5,6} • Sunitinib¹²
Useful in Certain Circumstances
<ul style="list-style-type: none"> • Imatinib with cisplatin¹³ or sirolimus¹⁴ • Erlotinib¹⁵ • Lapatinib for EGFR-positive chordomas¹⁶ • Sorafenib^{17,18}

Ewing Sarcoma			
First-line therapy (primary/ neoadjuvant/adjuvant therapy)^{†††}	Preferred Regimens	Other Recommended Regimens	
	<ul style="list-style-type: none"> • VDC/IE (vincristine, doxorubicin, and cyclophosphamide alternating with ifosfamide and etoposide)^{19,20,††††} (category 1) 	<ul style="list-style-type: none"> • VAI (vincristine, doxorubicin, and ifosfamide)^{21,22} • VIDE (vincristine, ifosfamide, doxorubicin, and etoposide)²³ 	
Primary therapy for metastatic disease at initial presentation^{†††}	Preferred Regimens		
	<ul style="list-style-type: none"> • VDC/IE¹⁹ • VAI^{21,22} • VIDE²³ • VDC (vincristine, doxorubicin, and cyclophosphamide)²⁴ 		
Second-line therapy (relapsed/ refractory or metastatic disease)	Preferred Regimens	Other Recommended Regimens	Useful in Certain Circumstances
	<ul style="list-style-type: none"> • Cyclophosphamide and topotecan^{25-28,†††††} • Irinotecan + temozolomide ± vincristine²⁹⁻³⁵ 	<ul style="list-style-type: none"> • Cabozantinib³⁶ • Docetaxel and gemcitabine^{37,†††††} 	<ul style="list-style-type: none"> • Ifosfamide, carboplatin, and etoposide^{38,†††††}

†††Dactinomycin can be substituted for doxorubicin for concerns regarding cardiotoxicity.

††††In patients younger than 18 y, evidence supports 2-week compressed treatment.

†††††Vincristine could be added to these regimens.

Note: All recommendations are category 2A unless otherwise indicated.**Clinical Trials:** NCCN believes that the best management of any patient with cancer is in a clinical trial. Participation in clinical trials is especially encouraged.[References](#)

SYSTEMIC THERAPY AGENTS

Giant Cell Tumor of Bone
Preferred Regimen • Denosumab ³⁹⁻⁴⁰
Useful in Certain Circumstances • Interferon alfa-2b ⁴¹⁻⁴³

Osteosarcoma			
First-line therapy (primary/ neoadjuvant/adjuvant therapy or metastatic disease)	Preferred Regimens • Cisplatin and doxorubicin ⁴⁴⁻⁴⁶ (category 1) • MAP (high-dose methotrexate, cisplatin, and doxorubicin) ⁴⁶⁻⁴⁹ (category 1) ^{††††††}	Other Recommended Regimens • Doxorubicin, cisplatin, ifosfamide, and high-dose methotrexate ⁵⁰ , ††††††	
Second-line therapy (relapsed/ refractory or metastatic disease)	Preferred Regimens • Ifosfamide (high dose) ± etoposide ^{35,51} • Regorafenib ⁵² (category 1) • Sorafenib ⁵³	Other Recommended Regimens • Cabozantinib ³⁶ • Cyclophosphamide and topotecan ²⁴ • Docetaxel and gemcitabine ³⁷ • Gemcitabine ⁵⁵ • Sorafenib + everolimus (category 2B) ⁵⁴	Useful in Certain Circumstances • Cyclophosphamide and etoposide ⁵⁶ • Ifosfamide, carboplatin, and etoposide ³⁸ • High-dose methotrexate ^{††††††} • High-dose methotrexate, etoposide, and ifosfamide ^{57,††††††} • Sm ¹⁵³ -EDTMP for relapsed or refractory disease beyond second-line therapy ⁵⁸

High-Grade Undifferentiated Pleomorphic Sarcoma (UPS)
Follow osteosarcoma regimens (category 2B)

††††† In the event a patient receiving high-dose methotrexate experiences delayed elimination due to renal impairment, glucarpidase is strongly recommended.

Note: All recommendations are category 2A unless otherwise indicated.
Clinical Trials: NCCN believes that the best management of any patient with cancer is in a clinical trial. Participation in clinical trials is especially encouraged.

[References](#)

**BONE CANCER SYSTEMIC THERAPY AGENTS**
REFERENCES

- ¹Marabelle A, Le DT, Ascierto PA, et al. Efficacy of pembrolizumab in patients with noncolorectal high microsatellite instability/mismatch repair-deficient cancer: results from the phase II KEYNOTE-158 study. *J Clin Oncol* 2019;38:1-10.
- ²Lala M, Li TR, De Alwis DP, et al. A six-weekly dosing schedule for pembrolizumab in patients with cancer based on evaluation using modelling and simulation. *Eur J Cancer* 2020;131:68-75.
- ³Marabelle A, Fakih M, Lopez J, et al. Association of tumour mutational burden with outcomes in patients with advanced solid tumours treated with pembrolizumab: prospective biomarker analysis of the multicohort, open-label, phase 2 KEYNOTE-158 study. *Lancet Oncol* 2020;21:1353-1365.
- ⁴Merino DM, McShane LM, Fabrizio D, et al. Establishing guidelines to harmonize tumor mutational burden (TMB): in silico assessment of variation in TMB quantification across diagnostic platforms: phase I of the Friends of Cancer Research TMB Harmonization Project. *J Immunother Cancer* 2020;8:e000147.
- ⁵Schuetz SM, Bolejack V, Choy E, et al. Phase 2 study of dasatinib in patients with alveolar soft part sarcoma, chondrosarcoma, chordoma, epithelioid sarcoma, or solitary fibrous tumor. *Cancer* 2017 Jan 1;123(1):90-97.
- ⁶Villalobos VM, Hoffner B, Elias AD. We can study ultrarare tumors effectively in this day and age, it just takes a cooperative approach: The role of dasatinib in assorted indolent sarcomas. *Cancer* 2017;123(1):20-24.
- ⁷Chow W, Frankel P, Ruel C, et al. Results of a prospective phase 2 study of pazopanib in patients with surgically unresectable or metastatic chondrosarcoma. *Cancer* 2020;126:105-111.
- ⁸Tap WD, Villalobos VM, Cote GM, et al. Phase I study of the mutant IDH1 inhibitor ivosidenib: safety and clinical activity in patients with advanced chondrosarcoma. *J Clin Oncol* 2020;38:1693-1701.
- ⁹Georger B, Morland B, Ndiaye A, et al. Target-driven exploratory study of imatinib mesylate in children with solid malignancies by the Innovative Therapies for Children with Cancer (ITCC) European Consortium. *Eur J Cancer* 2009;45:2342-2351.
- ¹⁰Casali PG, Messina A, Stacchiotti S, et al. Imatinib mesylate in chordoma. *Cancer* 2004;101:2086-2097.
- ¹¹Stacchiotti S, Longhi A, Ferraresi V, et al. Phase II study of imatinib in advanced chordoma. *J Clin Oncol* 2012;30(9):914-920.
- ¹²George S, Merriam P, Maki RG, et al. Multicenter phase II trial of sunitinib in the treatment of nongastrointestinal stromal tumor sarcomas. *J Clin Oncol* 2009;27:3154-3160.
- ¹³Casali PG, Stacchiotti S, Grosso F, et al. Adding cisplatin (CDDP) to imatinib (IM) re-establishes tumor response following secondary resistance to IM in advanced chordoma. *J Clin Oncol (Meeting Abstracts)* 2007;25(18 suppl):10038.
- ¹⁴Stacchiotti S, Marrari A, Tamborini E, et al. Response to imatinib plus sirolimus in advanced chordoma. *Ann Oncol* 2009;20:1886-1894.
- ¹⁵Singhal N, Kotasek D, Parnis FX. Response to erlotinib in a patient with treatment refractory chordoma. *Anticancer Drugs* 2009;20(10):953-955.
- ¹⁶Stacchiotti S, Tamborini E, LoVullo S, et al. Phase II study on lapatinib in advanced EGFR-positive chordoma. *Ann Oncol* 2013;24(7):1931-1936.
- ¹⁷Amela E, Bompas E, Le Cesne A, et al. A phase II trial of sorafenib (SO) in advanced chordoma patients (pt). *J Clin Oncol* 2015; 33(15):Supplement 10520.
- ¹⁸Bompas E, Le Cesne A, Tresch-Bruneel E, et al. Sorafenib in patients with locally advanced and metastatic chordomas: a phase II trial of the French Sarcoma Group (GSF/GETO). *Ann Oncol* 2015;10:2168-2173.
- ¹⁹Grier HE, Krailo MD, Tarbell NJ, et al. Addition of ifosfamide and etoposide to standard chemotherapy for Ewing's sarcoma and primitive neuroectodermal tumor of bone. *N Engl J Med* 2003;348:694-701.
- ²⁰Womer RB, West DC, Krailo MD, et al. Randomized controlled trial of interval-compressed chemotherapy for the treatment of localized Ewing sarcoma: A report from the Children's Oncology Group. *J Clin Oncol* 2012 Nov 20;30(33):4148-4154.
- ²¹Paulussen M, Ahrens S, Dunst J, et al. Localized Ewing tumor of bone: final results of the cooperative Ewing's Sarcoma Study CESS 86. *J Clin Oncol* 2001;19:1818-1829.
- ²²Paulussen M, Craft AW, Lewis I, et al. Results of the EICESS-92 Study: two randomized trials of Ewing's sarcoma treatment--cyclophosphamide compared with ifosfamide in standard-risk patients and assessment of benefit of etoposide added to standard treatment in high-risk patients. *J Clin Oncol* 2008;26:4385-4393.
- ²³Brennan B, Kirton L, Marec-Berard P, et al. Comparison of two chemotherapy regimens in Ewing sarcoma (ES): Overall and subgroup results of the Euro Ewing 2012 randomized trial (EE2012). *J Clin Oncol* 2020;38(15_suppl):11500-11500.
- ²⁴Miser JS, Krailo MD, Tarbell NJ, et al. Treatment of metastatic Ewing's sarcoma or primitive neuroectodermal tumor of bone: evaluation of combination ifosfamide and etoposide--a Children's Cancer Group and Pediatric Oncology Group study. *J Clin Oncol* 2004;22:2873-2876.
- ²⁵Bernstein ML, Devidas M, Lafreniere D, et al. Intensive therapy with growth factor support for patients with Ewing tumor metastatic at diagnosis: Pediatric Oncology Group/Children's Cancer Group Phase II Study 9457--a report from the Children's Oncology Group. *J Clin Oncol* 2006;24:152-159.
- ²⁶Hunold A, Weddeling N, Paulussen M, et al. Topotecan and cyclophosphamide in patients with refractory or relapsed Ewing tumors. *Pediatr Blood Cancer* 2006;47:795-800.
- ²⁷Kushner BH, Kramer K, Meyers PA, et al. Pilot study of topotecan and high-dose cyclophosphamide for resistant pediatric solid tumors. *Med Pediatr Oncol* 2000;35:468-474.
- ²⁸Saylor RL 3rd, Stine KC, Sullivan J, et al. Cyclophosphamide plus topotecan in children with recurrent or refractory solid tumors: a Pediatric Oncology Group phase II study. *J Clin Oncol* 2001;19:3463-3469.
- ²⁹Casey DA, Wexler LH, Merchant MS, et al. Irinotecan and temozolomide for Ewing sarcoma: the Memorial Sloan-Kettering experience. *Pediatr Blood Cancer* 2009;53:1029-1034.
- ³⁰Wagner LM, Crews KR, Iacono LC, et al. Phase I trial of temozolomide and protracted irinotecan in pediatric patients with refractory solid tumors. *Clin Cancer Res* 2004;10:840-848.

Note: All recommendations are category 2A unless otherwise indicated.**Clinical Trials: NCCN believes that the best management of any patient with cancer is in a clinical trial. Participation in clinical trials is especially encouraged.****Continued****BONE-B**
4 OF 5

**BONE CANCER SYSTEMIC THERAPY AGENTS**
REFERENCES

- ³¹Wagner LM, McAllister N, Goldsby RE, et al. Temozolomide and intravenous irinotecan for treatment of advanced Ewing sarcoma. *Pediatr Blood Cancer* 2007;48:132-139.
- ³²McNall-Knapp RY, Williams CN, Reeves EN, et al. Extended phase I evaluation of vincristine, irinotecan, temozolomide, and antibiotic in children with refractory solid tumors. *Pediatr Blood Cancer* 2010;54:909-915.
- ³³Reed DR, Hayashi M, Wagner L, et al. Treatment pathway of bone sarcoma in children, adolescents, and young adults. *Cancer* 2017;123(12):2206-2218.
- ³⁴Raciborska A, Bilska K, Drabko K, et al. Vincristine, irinotecan, and temozolomide in patients with relapsed and refractory Ewing sarcoma. *Pediatr Blood Cancer* 2013;60(10):1621-1625.
- ³⁵Wagner LM, Perentesis JP, Reid JM, et al. Phase I trial of two schedules of vincristine, oral irinotecan, and temozolomide (VOIT) for children with relapsed or refractory solid tumors: a Children's Oncology Group phase I consortium study. *Pediatr Blood Cancer* 2010;54(4):538-545.
- ³⁶Italiano A, Mir O, Mathoulin-Pelissier S, et al. Cabozantinib in patients with advanced Ewing sarcoma or osteosarcoma (CABONE): a multicentre, single-arm, phase 2 trial. *Lancet Oncol* 2020;21:446-55.
- ³⁷Navid F, Willert JR, McCarville MB, et al. Combination of gemcitabine and docetaxel in the treatment of children and young adults with refractory bone sarcoma. *Cancer* 2008;113:419-425.
- ³⁸Van Winkle P, Angiolillo A, Krailo M, et al. Ifosfamide, carboplatin, and etoposide (ICE) reinduction chemotherapy in a large cohort of children and adolescents with recurrent/refractory sarcoma: the Children's Cancer Group (CCG) experience. *Pediatr Blood Cancer* 2005;44:338-347.
- ³⁹Branstetter DG, Nelson SD, Manivel JC, et al. Denosumab induces tumor reduction and bone formation in patients with giant-cell tumor of bone. *Clin Cancer Res* 2012;18:4415-4424.
- ⁴⁰Thomas D, Henshaw R, Skubitiz K, et al. Denosumab in patients with giant-cell tumour of bone: an open-label, phase 2 study. *Lancet Oncol* 2010;11:275-280.
- ⁴¹Kaiser U, Neumann K, Havemann K. Generalised giant-cell tumour of bone: successful treatment of pulmonary metastases with interferon alpha, a case report. *J Cancer Res Clin Oncol* 1993;119:301-303.
- ⁴²Kaban LB, Troulis MJ, Ebb D, et al. Antiangiogenic therapy with interferon alpha for giant cell lesions of the jaws. *J Oral Maxillofac Surg* 2002;60:1103-1111.
- ⁴³Yasko AW. Interferon therapy for giant cell tumor of bone. *Curr Opin Orthop* 2006;17:568-572.
- ⁴⁴Bramwell V, Burgers M, Sneath R, et al. A comparison of two short intensive adjuvant chemotherapy regimens in operable osteosarcoma of limbs in children and young adults: the first study of the European Osteosarcoma Intergroup. *J Clin Oncol* 1992;10:1579-1591.
- ⁴⁵Lewis IJ, Nooij MA, Whelan J, et al. Improvement in histologic response but not survival in osteosarcoma patients treated with intensified chemotherapy: a randomized phase III trial of the European Osteosarcoma Intergroup. *J Natl Cancer Inst* 2007;99:112-128.
- ⁴⁶Souhail RL, Craft AW, Van der Eijken JW, et al. Randomised trial of two regimens of chemotherapy in operable osteosarcoma: a study of the European Osteosarcoma Intergroup. *Lancet* 1997;350:911-917.
- ⁴⁷Bacci G, Ferrari S, Bertoni F, et al. Long-term outcome for patients with nonmetastatic osteosarcoma of the extremity treated at the istituto ortopedico rizzoli according to the istituto ortopedico rizzoli/osteosarcoma-2 protocol: an updated report. *J Clin Oncol* 2000;18:4016-4027.
- ⁴⁸Winkler K, Beron G, Delling G, et al. Neoadjuvant chemotherapy of osteosarcoma: results of a randomized cooperative trial (COSS-82) with salvage chemotherapy based on histological tumor response. *J Clin Oncol* 1988;6:329-337.
- ⁴⁹Marina NM, Smeland S, Bielack SS, et al. Comparison of MAPIE versus MAP in patients with a poor response to preoperative chemotherapy for newly diagnosed high-grade osteosarcoma (EUARMOS-1): an open-label, international, randomized controlled trial. *Lancet Oncol* 2016;17:1396-1408.
- ⁵⁰Bacci G, Briccoli A, Rocca M, et al. Neoadjuvant chemotherapy for osteosarcoma of the extremities with metastases at presentation: recent experience at the Rizzoli Institute in 57 patients treated with cisplatin, doxorubicin, and a high dose of methotrexate and ifosfamide. *Ann Oncol* 2003;14:1126-1134.
- ⁵¹Goorin AM, Harris MB, Bernstein M, et al. Phase II/III trial of etoposide and high-dose ifosfamide in newly diagnosed metastatic osteosarcoma: a pediatric oncology group trial. *J Clin Oncol* 2002;20(2):426-33.
- ⁵²Davis LE, Bolejack V, Ryan CW, et al. Randomized double-blind phase II study of regorafenib in patients with metastatic osteosarcoma. *J Clin Oncol* 2019;37(16):1424-1431.
- ⁵³Grignani G, Palmerini E, Dileo P, et al. A phase II trial of sorafenib in relapsed and unresectable high-grade osteosarcoma after failure of standard multimodal therapy: an Italian Sarcoma Group study. *Ann Oncol* 2012; 23:508-516.
- ⁵⁴Grignani G, Palmerini E, Ferraresi V, et al. Sorafenib and everolimus for patients with unresectable high-grade osteosarcoma progressing after standard treatment: a non-randomised phase 2 clinical trial. *Lancet Oncol* 2015;16(1):98-107.
- ⁵⁵Maki RG, Wathen JK, Patel SR, et al. Randomized phase II study of gemcitabine and docetaxel compared with gemcitabine alone in patients with metastatic soft tissue sarcomas: results of sarcoma alliance for research through collaboration study 002. *J Clin Oncol* 2007;25:2755-2763.
- ⁵⁶Berger M, Grignani G, Ferrari S, et al. Phase 2 trial of two courses of cyclophosphamide and etoposide for relapsed high-risk osteosarcoma patients. *Cancer* 2009;115:2980-2987.
- ⁵⁷Le Deley MC, Guinebretiere JM, Gentet JC, et al. SFOP OS94: a randomised trial comparing preoperative high-dose methotrexate plus doxorubicin to high-dose methotrexate plus etoposide and ifosfamide in osteosarcoma patients. *Eur J Cancer* 2007;43:752-761.
- ⁵⁸Anderson PM, Wiseman GA, Dispenzieri A, et al. High-dose samarium-153 ethylene diamine tetramethylene phosphonate: low toxicity of skeletal irradiation in patients with osteosarcoma and bone metastases. *J Clin Oncol* 2002;20:189-196.

Note: All recommendations are category 2A unless otherwise indicated.**Clinical Trials: NCCN believes that the best management of any patient with cancer is in a clinical trial. Participation in clinical trials is especially encouraged.**



PRINCIPLES OF RADIATION THERAPY

General Principles

- Patients should be strongly encouraged to have RT at the same specialized center that is providing surgical and systemic interventions.
- Specialized techniques such as intensity-modulated RT (IMRT); particle beam RT with protons, carbon ions, or other heavy ions; or stereotactic radiosurgery (SRS) should be considered as indicated in order to allow high-dose therapy while maximizing normal tissue sparing.
- The RT doses listed below for chondrosarcoma and chordoma are for conventional fractionated regimens (1.8–2.0 Gy). Alternative total dose and fractionation schemes are necessary for specialized techniques such as SRS and stereotactic body RT (SBRT).

General Treatment and Dosing Information - Chondrosarcoma

Dosing Prescription Regimen

- Low-grade and intracompartmental
 - ▶ Unresectable:
 - ◇ Consider RT (>70 Gy) with specialized techniques
- High-grade, clear cell, or extracompartmental
 - ▶ Resectable:¹
 - ◇ Preoperative RT: Consider if positive margins are likely (19.8–50.4 Gy) followed by individualized postoperative RT with final target dose of 70 Gy for R1 resection and 72–78 Gy for R2 resection.
 - ◇ Postoperative RT: Consider, especially for high-grade/dedifferentiated subtype, 70 Gy for R1 and >70 Gy for R2 resection using specialized techniques.
 - ◇ Radiation is not needed for R0 resection; there should be no pre- or postoperative considerations.
 - ▶ Unresectable:
 - ◇ Consider RT (>70 Gy) with specialized techniques.

¹R0 = No microscopic residual disease, R1 = Microscopic residual disease, R2 = Gross residual disease

Note: All recommendations are category 2A unless otherwise indicated.

Clinical Trials: NCCN believes that the best management of any patient with cancer is in a clinical trial. Participation in clinical trials is especially encouraged.



PRINCIPLES OF RADIATION THERAPY

General Treatment and Dosing Information - Chordoma

Dosing Prescription Regimen

• Extracranial (mobile spine/sacrum)

▶ Resectable:¹

◊ Preoperative RT: Consider if positive margins are likely (19.8–50.4 Gy) followed by individualized postoperative RT.

◊ Postoperative RT: Consider postoperative RT for R1/R2 resection using specialized techniques with final target dose of 70 Gy for R1 and 72–78 Gy for R2 resection.

▶ Unresectable: Consider RT (>70 Gy) using specialized techniques.

• Cranial (base of skull)

▶ Resectable:¹

◊ Consider postoperative RT (>70 Gy) after R1/R2 resection using specialized techniques.

▶ Unresectable:

◊ Consider RT (>70 Gy) using specialized techniques.

¹R0 = No microscopic residual disease, R1 = Microscopic residual disease, R2 = Gross residual disease

Note: All recommendations are category 2A unless otherwise indicated.

Clinical Trials: NCCN believes that the best management of any patient with cancer is in a clinical trial. Participation in clinical trials is especially encouraged.

[Continued](#)
[References](#)

BONE-C
2 OF 6

**PRINCIPLES OF RADIATION THERAPY****General Treatment & Dosing Information - Ewing Sarcoma****Treatment of Primary Tumor/Dosing Prescription Regimen****• Definitive RT**

- ▶ Should start by week 12 of VAC/IE chemotherapy or week 18 of VIDE and is given concurrently with chemotherapy, withholding anthracyclines during radiation therapy per the Womer Protocol.
- ▶ Treatment volumes and doses:
 - ◇ 45 Gy to initial gross tumor volume (GTV1) + 1–1.5 cm for clinical target volume 1 (CTV1) + 0.5–1 cm for planning target volume 1 (PTV1) – GTV1 is defined as pre-treatment extent of bone and soft tissue disease. If the tumor has responded to chemotherapy and normal tissues have returned to their natural position, GTV1 should exclude pre-chemotherapy soft tissue volume that extended into a cavity (eg, tumors indenting lung, intestine, or bladder resume normal position following chemotherapy).
 - ◇ Cone-down (CD) to cover original bony extent + a total of 55.8 Gy to postchemotherapy soft tissue volume (GTV2) + 1–1.5 cm for CTV2 + 0.5–1 cm for PTV2
 - ◇ Consider increasing boost dose to a total of 59.4 Gy for chemotherapy response <50%

• Preoperative RT

- ▶ May be considered for marginally resectable tumors and is given concurrently with consolidation chemotherapy
- ▶ Treatment volumes and doses:
 - ◇ 36–45 Gy for initial GTV + 2 cm

• Postoperative RT

- ▶ Should begin within 60 days of surgery and is given concurrently with consolidation chemotherapy
- ▶ Treatment volumes and doses:
 - ◇ R0 resection:¹ Consider treatment for poor histologic response even if margins are adequate (45 Gy to GTV2 equivalent volume + 1–1.5 cm for CTV1 + 0.5–1 cm for PTV1)
 - ◇ R1 resection:¹ 45 Gy GTV2 equivalent volume + 1–1.5 cm for CTV1 + 0.5–1 cm for PTV1
 - ◇ R2 resection:¹ 45 Gy to GTV2 equivalent volume + 1–1.5 cm for CTV1 + 0.5–1 cm for PTV1 followed by CD to residual disease plus a total of 55.8 Gy to GTV2 + 1–1.5 cm for CTV2 + 0.5–1 cm for PTV2

¹R0 = No microscopic residual disease, R1 = Microscopic residual disease, R2 = Gross residual disease**Note: All recommendations are category 2A unless otherwise indicated.****Clinical Trials: NCCN believes that the best management of any patient with cancer is in a clinical trial. Participation in clinical trials is especially encouraged.****[Continued](#)**
[References](#)**BONE-C**
3 OF 6

**PRINCIPLES OF RADIATION THERAPY****Hemithorax Irradiation**

- Should be considered for chest wall primaries with extensive ipsilateral pleural involvement
- 15–20 Gy (1.5 Gy/fx) followed by CD to primary site (final dose based on resection margins)

Treatment of Metastatic Disease

- Consider whole lung irradiation for pulmonary metastases following completion of chemotherapy/metastasectomy (category 3)
 - ▶ 15 Gy (1.5 Gy/fx) for patients <14 years
 - ▶ 18 Gy for patients >14 years
- Current Children's Oncology Group (COG) study stratifies age before or after 6 years (12 vs. 15 Gy)

General Treatment and Dosing Information - Giant Cell Tumor of Bone**Treatment of Primary Site or Metastatic Disease/Dosing Prescription Regimen**

- Consider RT (50–60 Gy) for unresectable/progressive/recurrent disease that has not responded to denosumab, serial embolizations, IFN, or other treatments.
- An increased risk of malignant transformation following RT has been noted in some studies.

General Treatment and Dosing Information - Osteosarcoma**Treatment of Primary Tumor/Dosing Prescription Regimen**

- Consider RT for positive margins (R1) or gross residual (R2) or unresectable disease.
- Postoperative RT (R1 and R2 resections):¹ 55 Gy with 9–13 Gy boost to microscopic or gross disease (total dose to high-risk sites 64–68 Gy)
- Unresectable disease: 60–70 Gy (total dose will depend on normal tissue tolerance)

Treatment of Metastatic Disease

- Consider use of Sm¹⁵³-EDTMP.
- Consider use of SRS, especially for oligometastases.

¹R0 = No microscopic residual disease, R1 = Microscopic residual disease, R2 = Gross residual disease

Note: All recommendations are category 2A unless otherwise indicated.

Clinical Trials: NCCN believes that the best management of any patient with cancer is in a clinical trial. Participation in clinical trials is especially encouraged.

References

**PRINCIPLES OF RADIATION THERAPY**
REFERENCES**Chondrosarcoma**

- Amichetti M, Amelio D, Cianchetti M, et al. A systematic review of proton therapy in the treatment of chondrosarcoma of the skull base. *Neurosurg Rev* 2010;33(2):155-165.
- Goda J, Ferguson P, O'Sullivan B, et al. High-risk extracranial chondrosarcoma: long-term results of surgery and radiation therapy. *Cancer* 2011;117:2513-2519.
- Indelicato DJ, Rotondo RL, Begosh-Mayne D, et al. A prospective outcomes study of proton therapy for chordomas and chondrosarcomas of the spine. *Int J Radiat Oncol Biol Phys* 2016; 95(1):297-303.
- Rosenberg AE, Nielsen GP, Keel SB, et al. Chondrosarcoma of the base of the skull: a clinicopathologic study of 200 cases with emphasis on its distinction from chordoma. *Am J Surg Pathol* 1999;23(11):1370.
- Sahgal A, Chan MW, Atenafu EG, et al. Image-guided, intensity-modulated radiation therapy (IG-IMRT) for skull base chordoma and chondrosarcoma: preliminary outcomes. *Neuro Oncol* 2015;17(6):889-894.
- De Amorim Bernstein K, DeLaney TJ. Chordomas and chondrosarcomas-The role of radiation therapy. *J Surg Oncol* 2016 Oct;114(5):564-569.
- Imai R, Kamada T, Araki N, WORKING GROUP FOR BONE and SOFT-TISSUE SARCOMAS. Clinical efficacy of carbon ion radiotherapy for unresectable chondrosarcomas. *Anticancer Res* 2017 Dec;37(12):6959-6964.

Chordoma

- Amichetti M, Cianchetti M, Amelio D, et al. Proton therapy in chordoma of the base of the skull: a systematic review. *Neurosurg Rev* 2009;32(4):403-416.
- Boriani S, Bandiera S, Biagini R, et al. Chordoma of the mobile spine: fifty years of experience. *Spine (Phila Pa 1976)* 2006;31(4):493-503.
- Kabolizadeh P, Chen YL, Liebsch N, et al. Updated outcome and analysis of tumor response in mobile spine and sacral chordoma treated with definitive high-dose photon/proton radiation therapy. *Int J Radiat Oncol Biol Phys* 2017;97(2):254-262.
- McDonald M, Linton OR, Moore MG, et al. Influence of residual tumor volume and radiation dose coverage in outcomes for clival chordoma. *Int J Radiat Oncol Biol Phys* 2016;95(1):304-311.
- Park L, Delaney TF, Liebsch NJ, et al. Sacral chordomas: Impact of high-dose proton/photon-beam radiation therapy combined with or without surgery for primary versus recurrent tumor. *Int J Radiat Oncol Biol Phys* 2006;65(5):1514-21.
- Pennicooke B, Laufer I, Sahgal A, et al. Safety and local of radiation therapy for chordoma of the spine and sacrum: A systematic review. *Spine (Phila PA 1976)* 2016;41 Suppl 20:S186-S192.
- Rutz HP, Weber DC, Sugahara S, et al. Extracranial chordoma: Outcome in patients treated with function-preserving surgery followed by spot-scanning proton beam irradiation. *Int J Radiat Oncol Biol Phys* 2007;67(2):512-520.
- Yasuda M, Bresson D, Chibbaro S, et al. Chordomas of the skull base and cervical spine: clinical outcomes associated with a multimodal surgical resection combined with proton-beam radiation in 40 patients. *Neurosurg Rev* 2012;35(2):171-182; discussion 182-173.
- Sebro R, DeLaney TF, et al. Frequency and risk factors for additional lesions in the axial spine in subjects with chordoma: Indications for screening. *Spine (Phila Pa 1976)* 2017;42(1):E37-E40.

Ewing Sarcoma

- Denbo JW, Shannon Orr W, Wu Y, et al. Timing of surgery and the role of adjuvant radiotherapy in Ewing sarcoma of the chest wall: A single-institution experience. *Ann Surg Oncol* 2012;19(12):3809-15.
- Donaldson SS. Ewing sarcoma: radiation dose and target volume. *Pediatr Blood Cancer* 2004;42(5):471-6.
- Dunst J, Schuck A. Role of radiotherapy in Ewing tumors. *Pediatr Blood Cancer* 2004;42(5):465-70.
- Indelicato DJ, Keole SR, Lagmay JP, et al. Chest wall Ewing sarcoma family of tumors: long-term outcomes. *Int J Radiat Oncol Biol Phys* 2011;81(1):158-66.
- Paulino AC, Mai WY, Teh BS. Radiotherapy in metastatic Ewing sarcoma. *Am J Clin Oncol* 2013;36:283-286.
- Paulino AC, Nguyen TX, Mai WY, et al. Dose response and local control using radiotherapy in non-metastatic Ewing sarcoma. *Pediatr Blood Cancer* 2007;49(2):145-148.
- Rombi B, DeLaney TF, MacDonald SM, et al. Proton radiotherapy for pediatric Ewing's sarcoma: initial clinical outcomes. *Int J Radiat Oncol Biol Phys* 2012;82(3):1142-1148.

Note: All recommendations are category 2A unless otherwise indicated.**Clinical Trials: NCCN believes that the best management of any patient with cancer is in a clinical trial. Participation in clinical trials is especially encouraged.**[Continued](#)

**PRINCIPLES OF RADIATION THERAPY**
REFERENCES**Ewing Sarcoma (continued)**

Womer RB, West DC, Krailo MD, et al. Randomized controlled trial of interval-compressed chemotherapy for the treatment of localized Ewing sarcoma: a report from the Children's Oncology Group. *J Clin Oncol* 2012;30(33):4148-4154.

Schuck A, Ahrens S, von Schorlemer I, et al. Radiotherapy in Ewing tumors of the vertebrae: treatment results and local relapse analysis of the CESS 81/86 and EICESS 92 trials. *Int J Radiat Oncol Biol Phys* 2005;63(5):1562-1567.

Tanguturi SK, George S, Marcus KJ, et al. Whole lung irradiation in adults with metastatic Ewing Sarcoma: Practice patterns and implications for treatment. *Sarcoma* 2015, Article ID 591698.

Yock TI, Krailo M, Fryer CJ, et al. Local control in pelvic Ewing sarcoma: analysis from INT-0091--a report from the Children's Oncology Group. *J Clin Oncol* 2006 Aug 20;24(24):3838-3843. Erratum in: *J Clin Oncol* 2006;24(30):4947.

Casey DL, Meyers PA, Alektiar KM, et al. Ewing sarcoma in adults treated with modern radiotherapy techniques. *Radiother Oncol* 2014 Nov;113(2):248-253.

Talleur AC, Navid F, Spunt SL, et al. Limited margin radiation therapy for children and young adults with Ewing sarcoma achieves high rates of local tumor control. *Int J Radiat Oncol Biol Phys* 2016;96(1):119-126.

Giant Cell Tumor of Bone

Caudell JJ, Ballo MT, Zagars GK, et al. Radiotherapy in the management of giant cell tumor of bone. *Int J Radiat Oncol Biol Phys* 2003;57(1):158-165.

Hug EB, Muenter MW, Adams JA, et al. 3-D-conformal radiation therapy for pediatric giant cell tumors of the skull base. *Strahlenther Onkol* 2002;178(5):239-244.

Malone S, O'Sullivan B, Catton C, et al. Long-term follow-up of efficacy and safety of megavoltage radiotherapy in high-risk giant cell tumors of bone. *Int J Radiat Oncol Biol Phys* 1995;33(3):689-694.

Ruka W, Rutkowski P, Morysinski T, et al. The megavoltage radiation therapy in treatment of patients with advanced or difficult giant cell tumors of bone. *Int J Radiat Oncol Biol Phys* 2010;78(2):494-498.

Mixed Histology Reports

DeLaney TF, Liebsch NJ, Pedlow FX, et al. Phase II study of high-dose photon/proton radiotherapy in the management of spine sarcomas. *Int J Radiat Oncol Biol Phys* 2009;74(3):732-739.

Jingu K, Tsujii H, Mizoe JE, et al. Organizing Committee for the Working Group for Head-and-Neck Cancer. Carbon ion radiation therapy improves the prognosis of unresectable adult bone and soft-tissue sarcoma of the head and neck. *Int J Radiat Oncol Biol Phys* 2012;82(5):2125-2131.

Kamada T, Tsujii H, Yanagi T, et al. Efficacy and safety of carbon ion radiotherapy in bone and soft tissue sarcomas. Working Group for the Bone and Soft Tissue Sarcomas. *J Clin Oncol* 2002;20(22):4466-4471.

Wagner TD, Kobayashi W, Dean S, et al. Combination short-course preoperative irradiation, surgical resection, and reduced-field high-dose postoperative irradiation in the treatment of tumors involving the bone. *Int J Radiat Oncol Biol Phys* 2009;73(1):259-266.

Osteosarcoma

Anderson PM, Wiseman GA, Dispenzieri A, et al. High-dose samarium-153 ethylene diamine tetramethylene phosphonate: low toxicity of skeletal irradiation in patients with osteosarcoma and bone metastases. *J Clin Oncol* 2002;20:189-196.

Ciernik IF, Niemierko A, Harmon DC, et al. Proton-based radiotherapy for unresectable or incompletely resected osteosarcoma. *Cancer* 2011;117(19):4522-4530.

DeLaney TF, Park L, Goldberg SI, et al. Radiotherapy for local control of osteosarcoma. *Int J Radiat Oncol Biol Phys* 2005;61(2):492-498.

Guadagnolo BA, Zagars GK, Raymond AK, et al. Osteosarcoma of the jaw/craniofacial region: outcomes after multimodality treatment. *Cancer* 2009;115(14):3262-3270.

Mahajan A, Woo SY, Kornguth DG, et al. Multimodality treatment of osteosarcoma: radiation in a high-risk cohort. *Pediatr Blood Cancer* 2008;50(5):976-982.

Note: All recommendations are category 2A unless otherwise indicated.

Clinical Trials: NCCN believes that the best management of any patient with cancer is in a clinical trial. Participation in clinical trials is especially encouraged.

**American Joint Committee on Cancer (AJCC)**
TNM Staging System for Bone (*Primary malignant lymphoma and multiple myeloma are not included*)**Table 1. Definitions for T, N, M**

Appendicular Skeleton, Trunk, Skull, and Facial Bones

T Primary Tumor

- TX** Primary tumor cannot be assessed
- T0** No evidence of primary tumor
- T1** Tumor ≤8 cm in greatest dimension
- T2** Tumor >8 cm in greatest dimension
- T3** Discontinuous tumors in the primary bone site

Spine

T Primary Tumor

- TX** Primary tumor cannot be assessed
- T0** No evidence of primary tumor
- T1** Tumor confined to one vertebral segment or two adjacent vertebral segments
- T2** Tumor confined to three adjacent vertebral segments
- T3** Tumor confined to four or more adjacent vertebral segments, or any nonadjacent vertebral segments
- T4** Extension into the spinal canal or great vessels
- T4a** Extension into the spinal canal
- T4b** Evidence of gross vascular invasion or tumor thrombus in the great vessels

Pelvis

T Primary Tumor

- TX** Primary tumor cannot be assessed
- T0** No evidence of primary tumor
- T1** Tumor confined to one pelvic segment with no extrasosseous extension
- T1a** Tumor ≤8 cm in greatest dimension
- T1b** Tumor >8 cm in greatest dimension
- T2** Tumor confined to one pelvic segment with extrasosseous extension or two segments without extrasosseous extension
- T2a** Tumor ≤8 cm in greatest dimension
- T2b** Tumor >8 cm in greatest dimension
- T3** Tumor spanning two pelvic segments with extrasosseous extension
- T3a** Tumor ≤8 cm in greatest dimension
- T3b** Tumor >8 cm in greatest dimension
- T4** Tumor spanning three pelvic segments or crossing the sacroiliac joint
- T4a** Tumor involves sacroiliac joint and extends medial to the sacral neuroforamen
- T4b** Tumor encasement of external iliac vessels or presence of gross tumor thrombus in major pelvic vessels

N Regional Lymph Nodes

- NX** Regional lymph nodes cannot be assessed

Because of the rarity of lymph node involvement in bone sarcomas, the designation NX may not be appropriate and cases should be considered N0 unless clinical node involvement is clearly evident.

- N0** No regional lymph node metastasis
- N1** Regional lymph node metastasis

Used with the permission of the American College of Surgeons, Chicago, Illinois. The original source for this information is the AJCC Cancer Staging Manual, Eighth Edition (2017) published by Springer International Publishing.

**American Joint Committee on Cancer (AJCC)**
TNM Staging System for Bone *(continued)***M Distant Metastasis****M0** No distant metastasis**M1** Distant metastasis

M1a Lung

M1b Bone or other distant sites

G Histologic Grade**GX** Grade cannot be assessed**G1** Well differentiated — Low Grade**G2** Moderately differentiated — High Grade**G3** Poorly differentiated — High Grade**Table 2. AJCC Prognostic Groups**

There are no AJCC prognostic stage groupings for spine and pelvis.

	T	N	M	G
Stage IA	T1	N0	M0	G1, GX
Stage IB	T2	N0	M0	G1, GX
	T3	N0	M0	G1, GX
Stage IIA	T1	N0	M0	G2, G3
Stage IIB	T2	N0	M0	G2, G3
Stage III	T3	N0	M0	G2, G3
Stage IVA	Any T	N0	M1a	Any G
Stage IVB	Any T	N1	Any M	Any G
	Any T	Any N	M1b	Any G

Used with the permission of the American College of Surgeons, Chicago, Illinois. The original source for this information is the AJCC Cancer Staging Manual, Eighth Edition (2017) published by Springer International Publishing.



NCCN Categories of Evidence and Consensus	
Category 1	Based upon high-level evidence, there is uniform NCCN consensus that the intervention is appropriate.
Category 2A	Based upon lower-level evidence, there is uniform NCCN consensus that the intervention is appropriate.
Category 2B	Based upon lower-level evidence, there is NCCN consensus that the intervention is appropriate.
Category 3	Based upon any level of evidence, there is major NCCN disagreement that the intervention is appropriate.

All recommendations are category 2A unless otherwise indicated.

NCCN Categories of Preference	
Preferred intervention	Interventions that are based on superior efficacy, safety, and evidence; and, when appropriate, affordability.
Other recommended intervention	Other interventions that may be somewhat less efficacious, more toxic, or based on less mature data; or significantly less affordable for similar outcomes.
Useful in certain circumstances	Other interventions that may be used for selected patient populations (defined with recommendation).

All recommendations are considered appropriate.



Discussion

This discussion corresponds to the NCCN Guidelines for Bone Cancer. Last updated on 11/20/2020.

Table of Contents

Overview	MS-2
Literature Search Criteria and Guidelines Update Methodology	MS-2
Staging	MS-3
Principles of Bone Cancer Management	MS-3
Chondrosarcoma	MS-5
Prognostic Factors	MS-6
Treatment	MS-7
Metastatic Disease	MS-9
Surveillance	MS-9
Relapsed Disease	MS-9
Chordoma	MS-9
Workup	MS-10
Treatment	MS-10
Surveillance	MS-12
Relapsed Disease	MS-13
Ewing Sarcoma	MS-13
Prognostic Factors	MS-14
Workup	MS-14

Treatment	MS-15
Surveillance	MS-18
Relapsed or Refractory Disease	MS-19
NCCN Recommendations	MS-20
Giant Cell Tumor of Bone	MS-20
Workup	MS-20
Treatment	MS-20
Surveillance	MS-22
Osteosarcoma	MS-22
Prognostic Factors	MS-23
Workup	MS-24
Treatment	MS-24
Localized Disease	MS-26
Metastatic Disease at Presentation	MS-27
Surveillance	MS-27
Relapsed or Refractory Disease	MS-28
High-Grade Undifferentiated Pleomorphic Sarcoma of Bone	MS-29
Immunotherapy for Bone Cancer	MS-30
Summary	MS-31
References	MS-33



Overview

Primary bone cancers are extremely rare neoplasms accounting for less than 0.2% of all cancers, although the true incidence is difficult to determine secondary to the rarity of these tumors.¹ In 2020, an estimated 3,600 people will be diagnosed in the United States and 1,720 people will die from the disease.² Primary bone cancers demonstrate wide clinical heterogeneity and may be curable with proper treatment. In adults, chondrosarcoma is the most common primary bone cancer, accounting for 40%, followed by osteosarcoma (28%), chordoma (10%), Ewing sarcoma (8%), and lastly undifferentiated pleomorphic sarcoma (UPS) (4%). In children and adolescents, osteosarcoma and Ewing sarcoma are far more common than chondrosarcoma and chordoma.³ High-grade UPS of bone, fibrosarcoma, chordoma, and giant cell tumor of bone (GCTB) are relatively rare tumors collectively constituting 1% to 5% of primary malignant bone tumors.⁴ GCTB has both benign and malignant forms, with the benign form being the most common subtype. Various types of bone cancers are named based on their histologic origin: chondrosarcomas arise from cartilage, osteosarcomas arise from bone, and fibrogenic tissue is the origin of fibrosarcoma of bone, whereas vascular tissue gives rise to hemangioendothelioma and hemangiopericytoma. Notochordal tissue gives rise to chordoma. Several primary bone cancers, including Ewing sarcoma, are of unknown histologic origin. Chondrosarcoma usually arises in middle-aged and older adults. Osteosarcoma and Ewing sarcoma develop mainly in children and young adults. Chordoma is more common in males, with the peak incidence in the fifth to sixth decades of life.^{5,6}

The pathogenesis and etiology of most bone cancers remain unclear. Gene rearrangements between the *EWS* and *ETS* family of genes have been implicated in the pathogenesis of Ewing sarcoma.⁷⁻¹⁰ Specific germline mutations have also been implicated in the pathogenesis of osteosarcoma.^{11,12} Li-Fraumeni syndrome characterized by a germline

mutation in the *TP53* gene is associated with a high risk of developing osteosarcoma.¹³⁻¹⁵ Osteosarcoma is the most common second primary malignancy in patients with a history of retinoblastoma, characterized by a mutation in the retinoblastoma gene *RB1*.^{11,16,17} Increased incidences of osteosarcoma have also been associated with other genetic mutations and inherited genetic predisposition syndromes.¹¹ Osteosarcoma is also the most common radiation-induced bone sarcoma.^{18,19}

The development of multiagent chemotherapy regimens for neoadjuvant and adjuvant treatment has considerably improved the prognosis for patients with osteosarcoma and Ewing sarcoma.^{20,21} With current multimodality treatment, approximately three quarters of all patients diagnosed with osteosarcoma are cured and 90% to 95% of patients diagnosed with osteosarcoma can be successfully treated with limb-sparing approaches rather than amputation.²² Survival rates have improved to almost 70% in patients with localized Ewing sarcoma.²¹ In patients with Ewing sarcoma and osteosarcoma, a cure is still achievable in selected patients diagnosed with metastatic disease at presentation.^{23,24} The 5-year survival across all types of primary bone cancers is 66.9%.¹

The NCCN Guidelines for Bone Cancer focus on chordoma, chondrosarcoma, Ewing sarcoma, and osteosarcoma. The guidelines also provide recommendations for treating GCTB. Although typically benign, GCTB is locally aggressive and can lead to significant bone destruction.

Literature Search Criteria and Guidelines Update Methodology

Prior to the update of this version of the NCCN Guidelines for Bone Cancer, an electronic search of the PubMed database was performed to obtain key literature published in bone cancer since the previous Guidelines update, using the following search terms: chondrosarcoma OR chordoma OR Ewing sarcoma OR giant cell tumor of bone OR



osteosarcoma OR bone sarcoma OR primary bone cancer OR primary bone neoplasm OR primary bone tumor.

The search results were narrowed by selecting studies in humans published in English. Results were confined to the following article types: Clinical Trial; Guideline; Randomized Controlled Trial; Meta-Analysis; Systematic Reviews; and Validation Studies.

The data from key PubMed articles as well as articles from additional sources deemed as relevant to these guidelines and discussed by the panel have been included in this version of the Discussion section (eg, e-publications ahead of print, meeting abstracts). Recommendations for which high-level evidence is lacking are based on the panel's review of lower-level evidence and expert opinion.

The complete details of the Development and Update of the NCCN Guidelines are available at www.NCCN.org.

Staging

The eighth edition of AJCC staging classification (2018) is based on the assessment of histologic grade (G), tumor size (T), and presence of regional (N) and/or distant metastases (M).²⁵

The NCCN Panel would like to clarify that although some studies interpret imaging before chemotherapy treatment based on the extent of tumor invasion relative to the periosteum (eg, extraperiosteal, intraperiosteal) for prognostic purposes, these terms do not specifically occur in any validated staging systems and the significance is unknown.

Principles of Bone Cancer Management

Multidisciplinary Team Involvement

Primary bone tumors and selected metastatic tumors should be evaluated and treated by a multidisciplinary team of physicians with demonstrated

expertise in the management of these tumors. Long-term surveillance and follow-up are necessary when considering the risk of recurrence and comorbidities associated with chemotherapy and radiation therapy (RT). Life-long follow-up is recommended for surveillance and treatment of late effects of surgery, RT, and chemotherapy in long-term survivors. Patients should be given a survivorship prescription to schedule follow-up with a multidisciplinary team. Fertility issues should be discussed with appropriate patients.²⁶ For information on disease- and survivorship-related issues for adolescent and young adult (AYA) patients, please refer to the NCCN Guidelines for Adolescent and Young Adult (AYA) Oncology as clinically appropriate. Finally, select patients with a family history of genetic predisposition to bone sarcomas may benefit from genetic consultation and testing.

Diagnostic Workup

Suspicion of a malignant bone tumor in a patient with a symptomatic lesion often begins when a poorly marginated lesion is seen on a plain radiograph. In patients younger than 40 years, an aggressive, symptomatic bone lesion has a significant risk of being a malignant primary bone tumor, and referral to an orthopedic oncologist should be considered prior to further workup. In patients 40 years of age and older, CT scan of the chest, abdomen, and pelvis with contrast; bone scan; mammogram; and other imaging studies as clinically indicated should be performed if plain radiographs do not suggest a specific diagnosis.²⁷

All patients with suspected bone sarcoma should undergo complete staging prior to biopsy. Prior to biopsy, consultation should be obtained with an orthopedic oncologist regarding appropriate pre-biopsy imaging. The standard staging workup for a suspected primary bone cancer should include chest imaging (chest radiograph or chest CT to detect pulmonary metastases), appropriate imaging of the primary site (plain radiographs, MRI for local staging, and/or CT scan), and bone scan or PET/CT.²⁸



Whole-body MRI is a sensitive imaging technique for the detection of skeletal metastases in patients with small cell neoplasms, Ewing sarcoma, and osteosarcoma.^{29,30} Imaging of painless bone lesions should be evaluated by a musculoskeletal radiologist followed by appropriate referral to a multidisciplinary treatment team if necessary. Laboratory studies, such as complete blood count (CBC), comprehensive metabolic panel (CMP) with calcium to assess for hypercalcemia, lactate dehydrogenase (LDH), and alkaline phosphatase (ALP) should be done prior to initiation of treatment.

PET/CT is an alternative imaging technique that has been utilized in the pretreatment staging of soft tissue and bone sarcomas.^{31,32} Published reports have demonstrated the utility of PET scans in the evaluation of response to chemotherapy in patients with osteosarcoma, Ewing sarcoma, and advanced chordoma.³³⁻³⁶ PET/CT with the investigational radioactive substance ¹⁸F-fluoromisonidazole (FMISO) has been shown to identify the hypoxic component in residual chordomas prior to RT.³⁷ This approach is being evaluated and would be helpful in identifying tumors with low oxygen levels that are more resistant to RT.

Biopsy

Incisional (open) biopsy and percutaneous biopsy (core needle or fine-needle aspiration [FNA]) are the two techniques historically used in the diagnosis of musculoskeletal lesions.^{38,39} Open biopsy is the most accurate method because of larger sample size, which is useful for performing additional studies such as immunohistochemistry or cytogenetics.⁴⁰ However, open biopsy requires general or regional anesthesia and operating room facilities, whereas core biopsy can be performed under local anesthesia, with or without sedation. Core needle biopsy has also been used as an alternative to open biopsy for the diagnosis of musculoskeletal lesions with accuracy rates ranging from 88% to 96% when adequate samples are obtained.⁴¹⁻⁴⁴ Cost savings may

be realized when needle biopsy is employed in selected patients.⁴¹ Advances in imaging techniques have contributed to the increasing use of image-guided percutaneous biopsy for the diagnosis of primary and secondary bone tumors.⁴⁵ The method of choice for biopsy remains controversial since no randomized controlled trials have compared core needle biopsy with open biopsy.

The guidelines recommend core needle or open biopsy to confirm the diagnosis of primary bone tumor prior to any surgical procedure or fixation of primary site. Biopsy should be performed at the center that will provide definitive treatment for patients with a suspected primary malignant bone tumor. At the time of biopsy, careful consideration should be given to appropriate stabilization of the bone and/or measures to protect against impending pathologic fracture. The placement of biopsy is critical to the planning of limb-sparing surgery, and failure to follow appropriate biopsy procedures may lead to adverse patient outcomes.^{38,39} In a multicenter review of 597 patients with musculoskeletal tumors, alteration of the treatment plan (complex resection or the use of adjunctive treatment) was encountered in 19% of patients and unnecessary amputation was performed in 18 patients.⁴⁶

Both open and core needle biopsy techniques are associated with risk of local tumor recurrence either by tumor spillage or tumor seeding along the biopsy tract, if the scar is not removed en bloc during the tumor resection. The risk of tumor seeding is less with core needle biopsy.^{47,48}

Nevertheless, the same principles should be applied for core needle and open biopsy. Appropriate communication between the surgeon, orthopedic oncologist, musculoskeletal radiologist, and bone pathologist is critical in planning the biopsy route. In the case of children, consultation with a pediatric oncologist is recommended. It is essential to select the biopsy route in collaboration with the surgeon to ensure that the biopsy tract lies within the planned resection bed so that it can be resected with the same



wide margins as the primary tumor during surgery. Although the risk of tumor seeding is not significant with FNA biopsy, it is not suitable for the diagnosis of primary lesions since the diagnostic accuracy of FNA is less than that of core needle biopsy.⁴⁹

Surgery

Surgical margins should be negative, wide enough to minimize potential local recurrence, and narrow enough to maximize function. Wide excision implies histologically negative surgical margins and it is necessary to optimize local control. Local control may be achieved either by limb-sparing surgery or amputation. In selected cases, amputation may be the most appropriate option to achieve this goal. However, limb-sparing surgery is preferred if reasonable functional outcomes can be achieved. Final pathologic evaluation should include assessment of surgical margins and size/dimensions of tumor. The response to the preoperative therapy should be evaluated utilizing pathologic mapping. Consultation with a physiatrist is recommended to evaluate for mobility training and to prescribe an appropriate rehabilitation program.

Radiation Therapy

RT is used either as an adjuvant to surgery for patients with resectable tumors or as definitive therapy in patients with tumors not amenable to surgery. Specialized techniques such as intensity-modulated RT (IMRT); particle beam RT with protons, carbon ions, or other heavy ions; or stereotactic radiosurgery (SRS)/stereotactic RT (SRT) should be considered as clinically indicated in order to deliver high radiation doses while maximizing normal tissue sparing.^{50,51} RT should be administered at the same specialized center that is providing surgical and systemic interventions. See *Principles of Radiation Therapy* in the algorithm for treatment volumes and radiation doses specific to each subtype.

Chondrosarcoma

Chondrosarcomas characteristically produce cartilage matrices from neoplastic tissue devoid of osteoid and may occur at any age, but they are more common in older adults.^{52,53} They may be classified according to the location from which they arise, with the pelvis and the proximal femur the most common primary sites of origin. They may also be distinguished by their location along the bone as follows: 1) primary or central lesions (arising normally from the medullary cavity) originating from previously normal-appearing bone preformed from cartilage; or 2) secondary or peripheral tumors (arising from the periosteum) that develop from preexisting benign cartilage lesions, such as enchondromas, or from the cartilaginous portion of an osteochondroma.^{52,54,55} Conventional chondrosarcoma of the bone constitutes approximately nearly 90% of all chondrosarcomas and of these 90% are low to intermediate grade.⁵⁶ Malignant transformation has been reported in patients with Ollier disease (enchondromatosis) and Maffucci syndrome (enchondromatosis associated with soft tissue hemangioma).⁵⁷ The peripheral or secondary tumors are usually low grade with infrequent metastasis.⁵⁸ Nearly 65% of chondrosarcoma cases and nearly all cases of Ollier disease and Maffucci syndrome are related to isocitrate dehydrogenase (*IDH1* or *IDH2*) mutations.^{56,59-61} Other implicated genetic aberrations include inactivating mutations of *CDKN2A* and *COL2A1*.⁵⁵ In addition to conventional chondrosarcoma, there are several non-conventional subtypes constituting about 10% to 15% of all chondrosarcomas.⁵² These include clear cell, juxtacortical, dedifferentiated, myxoid, and mesenchymal forms of chondrosarcoma.^{52,62,63} Primary skeletal myxoid chondrosarcoma (myxoid chondrosarcoma of bone) is an extremely rare neoplasm that has not been fully characterized as a distinct clinicopathologic entity.^{64,65} It is considered to be a myxoid variant of intermediate- or high-grade chondrosarcoma and is commonly located in the bones around the hip joint.^{52,65} An epidemiologic study of mesenchymal chondrosarcomas using the SEER database found that 40% of these were skeletal and 60% were



extraskelatal.⁶⁶ Research suggests that alterations in the retinoblastoma pathway are present in a significant majority of clear cell, dedifferentiated, and mesenchymal chondrosarcomas.⁶²

Extraskelatal myxoid chondrosarcoma, on the other hand, is a rare soft tissue sarcoma that is characterized by chromosomal translocations t(9;22)(q22;q11-12) or t(9;17)(q22;q11), generating the fusion genes *EWS-CHN* (*EWSR1-NR4A3*) or *RBP56-CHN* (*TAF2N-NR4A3*), respectively.^{67,68} In addition, two other variant chromosomal translocations, t(9;15)(q22;q21) and t(3;9)(q12;q22), resulting in fusion genes *TCF12-NR4A3* and *TFG-NR4A3*, respectively, have also been identified in case reports.⁶⁹ A retrospective study demonstrated prolonged overall survival (OS) in patients with extraskelatal myxoid chondrosarcoma despite high rates of local and distant recurrence.⁷⁰ The data also revealed a significant pattern of decreased event-free survival (EFS) with increasing tumor size. Extraskelatal myxoid chondrosarcoma is not included in the NCCN Guidelines for Bone Cancer.

Symptoms of chondrosarcoma are usually mild and depend on tumor size and location. Patients with pelvic or axial lesions typically present later in the disease course, as the associated pain has a more insidious onset and often occurs when the tumor has reached a significant size.⁷¹⁻⁷³ Central chondrosarcomas demonstrate cortical destruction and loss of medullary bone trabeculations on radiographs, as well as calcification and destruction.⁷² MRI will show the intramedullary involvement as well as extraosseous extension of the tumor. Secondary lesions arise from preexisting lesions. Serial radiographs will demonstrate a slow increase in size of the osteochondroma or enchondroma. A cartilage “cap” measuring greater than 2 cm on a pre-existing lesion or documented growth after skeletal maturity should raise the suspicion of sarcomatous transformation.⁷⁴

Prognostic Factors

Whether the lesion is primary or secondary, central or peripheral, the anatomic location, histologic grade, and size of the lesion are essential prognostic features.^{66,71,75-79} In an analysis of 2890 patients with chondrosarcoma from the SEER database, female sex, a low histologic grade, and local surgical stage were associated with a significant disease-specific survival benefit in the univariate analysis, whereas only grade and stage had significant association with disease-specific survival on multivariate analysis.⁸⁰ An epidemiologic study examined the impact of demographic and tumor characteristics on OS.⁶⁶ No differences in OS were observed between skeletal and extraskelatal mesenchymal chondrosarcoma, with a 5- and 10-year OS of 51% and 43%, respectively. Anatomic tumor location was a significant prognostic factor, with poorer OS observed among patients with axial versus cranial or appendicular tumor locations. Cranial tumors had different clinical behavior compared with axial and appendicular locations with data suggesting better OS for younger patients. Prognostic factors were also examined in a retrospective, multi-institutional analysis of 225 patients with low-grade chondrosarcoma.⁸¹ Metastasis-free survival (MFS) probability was 95% at 5 years and 92% at 10 years. A low histologic grade and no recurrence had a significant MFS benefit, but tumor size at diagnosis and surgical margin width had no effect on MFS. In a SEER database analysis, differences in the presence of metastasis were noted among the various chondrosarcoma subtypes.⁶³ Dedifferentiated (19.8%) followed by mesenchymal (10.6%) chondrosarcoma were most associated with the presence of metastasis on presentation, whereas juxtacortical chondrosarcoma was least associated (2.1%) with the presence of metastasis on presentation.⁶³ Similarly, median survival was found to be lowest with the dedifferentiated subtype (11 months) and highest with the juxtacortical subtype (97 months).⁶³

**Treatment****Surgery**

Wide excision with negative margins is the preferred primary treatment for patients with large tumors and pelvic localization, irrespective of the grade.^{77,82-84} Wide resection with adequate surgical margins is associated with higher EFS and OS rates in patients with chondrosarcoma of axial skeleton and pelvic girdle. The 10-year OS and EFS rates were 61% and 44%, respectively, for patients who underwent resection with adequate surgical margins compared to the corresponding survival rates of 17% and 0% for those who underwent resection with inadequate surgical margins.⁸⁵ Intralesional curettage with adjuvant cryosurgery has been shown to be associated with low rates of recurrence in patients with grade I intracompartmental chondrosarcomas.⁸⁶⁻⁸⁸ In selected patients with low-grade and less radiographically aggressive, non-pelvic chondrosarcomas, intralesional excision can be used as an alternative to wide excision without compromising outcomes.⁸⁹⁻⁹² This approach should be restricted to extremity tumors.⁹³ In a meta-analysis comparing outcome in patients with central, low-grade (grade I) chondrosarcoma of the long bones following either intralesional excision or wide resection, there was little difference in the recurrence-free survival between both groups after 24 months. The rate of major complications was found to be higher following wide resection of the lesion (230 per 1000 vs. 40 per 1000 for intralesional curettage).⁹⁴

Radiation Therapy

Primary RT can be considered for borderline resectable and unresectable disease (category 2B). RT is also recommended after incomplete resection or for palliation of symptoms in patients with recurrent tumors.^{52,53} In a retrospective analysis of 60 patients who underwent surgery for extracranial high-risk chondrosarcoma, the use of RT as an adjunct to surgery (preoperative or postoperative) was associated with excellent and durable local control for tumors not amenable to wide

surgical resection.⁹⁵ A prospective outcomes study of patients with chondrosarcomas (n = 17) of the sacrum, cervical spine, and thoracolumbar spine found that high-dose external proton beam RT had a 4-year OS rate of 72% and more than half of patients (58%) with local control of disease. Treating patients with RT at the time of diagnosis is suggested to reduce the likelihood of local progression.⁹⁶

Proton beam RT alone or in combination with photon beam RT has been associated with an excellent local tumor control and long-term survival in the treatment of patients with low-grade skull base and cervical spine chondrosarcomas.⁹⁷⁻¹⁰⁴ In two separate studies, proton beam RT resulted in local control rates of 92% and 94% in patients with skull base chondrosarcoma.^{97,101} Noel and colleagues reported a 3-year local control rate of 92% in 26 patients with chondrosarcoma of the skull base and upper cervical spine treated with surgical resection followed by a combination of proton and photon beam RT.¹⁰⁰ In a larger series involving 229 patients with skull base chondrosarcomas, the combination of proton and photon beam RT resulted in 10-year local control rates of 94%.⁹⁸ Carbon ion RT has also been reported to result in high local control rates in patients with skull base chondrosarcoma^{105,106} and patients with other unresectable chondrosarcomas.¹⁰⁷ SRS has also been evaluated for adjuvant treatment of skull base chondrosarcoma.¹⁰⁸

Chemotherapy

Chemotherapy is generally not effective in chondrosarcoma, particularly for the conventional and dedifferentiated subtypes. Mitchell and colleagues reported that adjuvant chemotherapy with cisplatin and doxorubicin was associated with improved survival in patients with dedifferentiated chondrosarcoma.¹⁰⁹ However, this finding could not be confirmed in other studies.¹¹⁰⁻¹¹² A review of outcomes for 113 patients with mesenchymal chondrosarcoma reported that the addition of chemotherapy was associated with reduced risk of recurrence and



death.¹¹³ Another report from the German study group confirmed that the outcome was better in younger patients with mesenchymal chondrosarcoma who received chemotherapy.¹¹⁴ In the absence of data from prospective randomized trials, the role of chemotherapy in the treatment of chondrosarcomas remains undefined.

A multicenter, phase 2, single-arm study in patients with advanced sarcoma evaluated dasatinib, the small-molecule inhibitor of kinases (including SRC family, BCR-ABL, c-KIT, and platelet-derived growth factor receptors [PDGFRs] α and β). The Sarcoma Alliance for Research through Collaboration (SARC) coordinated this study, known as SARC009, which included three parallel trials focused on different rare sarcoma histologic types: aggressive sarcoma subtypes, indolent sarcoma subtypes, and gastrointestinal stromal tumors. The indolent sub-study included patients with unresectable, recurrent, or metastatic soft tissue or bone sarcoma, which included 33 patients with grade 1 or 2 chondrosarcoma.¹¹⁵ The primary endpoint was progression-free survival (PFS) at 6 months using the Choi criteria, which for patients with chondrosarcoma was 47%, just below the 50% cutoff for an active agent. Six patients had objective tumor response and four patients (12%) had stable disease for more than 1 year, suggesting some tumor control. An editorial published in the same issue of *Cancer* compared results of this and other trials using different chemotherapies for chondrosarcoma and found improved PFS at 6 months with dasatinib.¹¹⁶

Similarly, pazopanib is an oral, multi-kinase inhibitor with antiangiogenic activity. A single-arm, multicenter, phase 2 study evaluated the safety and efficacy of pazopanib in 42 patients with unresectable or metastatic conventional chondrosarcoma. The primary endpoint of the study was disease control rate (DCR) at week 16 and the secondary endpoints included PFS and OS. Overall, treatment with pazopanib resulted in a DCR of 43% at 16 weeks, a median PFS of 7.9 months, and a median OS

of 17.6 months. Prior reports of the antitumor activity of pazopanib (including a case report and a small cohort study) in unresectable or metastatic chondrosarcoma are also favorable.⁵⁶

A multicenter, open-label dose-escalation and expansion phase 1 trial in patients with *IDH1*-mutant advanced solid tumors, including 21 patients with advanced chondrosarcoma, evaluated the response to ivosidenib, a selective *IDH1* inhibitor. Median PFS was 5.6 months (95% CI, 1.9–7.4 months), PFS at 6 months was 39.5%, and 52% of patients had stable disease. All patients demonstrated decreased plasma 2-hydroxyglutarate (2-HG) levels following treatment.¹¹⁷ Ivosidenib has thus been added as a treatment option for patients with *IDH1*-mutant conventional or dedifferentiated chondrosarcoma.

NCCN Recommendations

The histologic grade and tumor locations are the most important variables that determine the choice of primary treatment.

Wide excision or intralesional excision with or without an adjuvant are the primary treatment options for patients with resectable low-grade and intracompartmental lesions.^{90,91} Wide excision is the preferred treatment option for patients with pelvic low-grade chondrosarcomas.⁸² High-grade (grade II, III), clear cell, or extracompartmental lesions, if resectable, should be treated with wide excision obtaining negative surgical margins.⁸⁵ Wide excision should provide negative surgical margins and may be achieved by either limb-sparing surgery or amputation.

Postoperative treatment with proton and/or photon beam RT may be useful for patients with tumors in an unfavorable location not amenable to resection, especially in chondrosarcomas of the skull base and axial skeleton.^{52,53} RT can be considered for patients with unresectable high- and low-grade lesions. However, since there are not enough data to



support the use of RT in patients with chondrosarcoma, the panel has included this option as a category 2B recommendation.

The guidelines suggest that patients with dedifferentiated chondrosarcomas could be treated as per osteosarcoma and those with mesenchymal chondrosarcomas could be treated as per Ewing sarcoma. Both of these options are included as category 2B recommendations. Dasatinib, pazopanib, and ivosidenib are included as category 2A recommendations for select patients with chondrosarcoma.

Metastatic Disease

Patients with metastatic chondrosarcoma that is not dedifferentiated or mesenchymal either after recurrence or at presentation can be classified as oligometastatic or widespread disease. In general, patients with oligometastatic disease are amenable to local control (potentially rendering it disease free), such as with resection or RT, or treated as part of a clinical trial (goal is disease free/cure; more likely to proceed with surgery or radiation). Conversely, widespread disease cannot be treated by local resection or SBRT (goal is palliation).

For oligometastatic disease that is resectable, NCCN recommends surgical excision of all sites of disease, if possible. For oligometastatic disease that is unresectable, consider RT that may include ablative therapy. For widespread disease, NCCN recommends considering RT, surgery, and/or ablative therapies for symptomatic sites, systemic therapy, or clinical trial.

Surveillance

Surveillance for low-grade lesions consists of a physical exam and imaging. Imaging with radiographs of the primary site, and/or cross-sectional imaging (MRI or CT, both with contrast) and imaging of the

chest and primary site are recommended as clinically indicated every 6 to 12 months for 2 years and then yearly as appropriate.

Surveillance for high-grade lesions consists of a physical exam, radiographs of the primary site, and/or cross-sectional imaging (MRI or CT) as clinically indicated as well as chest imaging based on physician's concern for risk of recurrence. Chest imaging should occur every 3 to 6 months (may include CT at least biannually) for the first 5 years and yearly thereafter for a minimum of 10 years, as late metastases and recurrences after 5 years are more common with chondrosarcoma than with other sarcomas.⁷⁶ Functional assessment should be performed at every visit.

Relapsed Disease

Local recurrence should be treated with wide excision if the lesions are resectable. RT (category 2B) or re-resection to achieve negative surgical margins should be considered following wide excision with positive surgical margins. Negative surgical margins should be observed. Unresectable recurrences are treated with RT (category 2B). A study in 25 patients demonstrated effective local control and low acute toxicity with carbon ion RT in patients with recurrent skull base chordoma or chondrosarcoma.¹¹⁸ Patients with systemic recurrence of a high-grade chondrosarcoma should follow the recommendations described above for *Metastatic Disease*.

Chordoma

Chordomas arise from the embryonic remnants of the notochord and are more common in older adults. Chordomas predominantly arise in the axial skeleton, with the sacrum (50%–60%), skull base (25%–35%), and spine (15%) being the most common primary sites.^{6,119} Chordomas are traditionally classified by the World Health Organization (WHO) into three histologic variants: conventional, chondroid, and dedifferentiated. Conventional chordomas are the most common histologic subtype



characterized by the absence of cartilaginous or mesenchymal components. Chondroid chordomas present with histologic features of chordoma and cartilage elements, accounting for 5% to 15% of all chordomas. Dedifferentiated chordomas constitute about 2% to 8% of all chordomas and have features of high-grade pleomorphic spindle cell soft tissue sarcoma and an aggressive clinical course.¹¹⁹ More recently, an additional subset of chordoma has been identified in children. Poorly differentiated chordoma is characterized molecularly by the absence of SMARCB1 expression. SMARCB1 is a chromatin remodeling agent and its absence is also implicated in the pathogenesis of some sarcomas, including but not limited to epithelioid sarcoma, malignant rhabdoid tumor, and epithelioid malignant peripheral nerve sheath tumor (MPNST). It is reported that poorly differentiated chordoma may be more common in the pediatric population and show a predilection for occurrence in the skull base and cervical spine. Although further research is warranted, poorly differentiated chordoma is considered to be more aggressive than either the conventional or chondroid variants with a poorer OS.¹²⁰ Chordomas of the spine and sacrum present with localized deep pain or radiculopathies, whereas cervical chordomas can cause airway obstruction or dysphagia and might present as an oropharyngeal mass. Neurologic deficit is more often associated with chordomas of the skull base and mobile spine than chordomas of sacrococcygeal region.⁶ A review of 47 patients with skull base chordomas suggested that male sex was associated with worse PFS and OS.¹²¹

Workup

Initial workup should include history and physical examination with adequate primary site imaging (ie, x-ray, CT with contrast ± MRI with contrast), screening MRI of spinal axis, and chest-abdominal-pelvic CT with contrast. Skull base to mid-thigh PET/CT or bone scan (if PET/CT is negative) can be considered for unusual cases. Benign notochordal cell tumors (BNCTs) are considered precursors to chordomas and do not

require surgical management.^{122,123} CT and MRI may be useful in distinguishing BNCTs from chordomas.^{124,125}

For skull base chordomas, CT is useful to delineate bone destruction and the presence of calcifications, whereas MRI is the modality of choice to define the tumor margin from brain, characterize the position and extension of tumors into the adjacent soft tissue structures, and visualize blood vessels.^{126,127} For sacrococcygeal chordomas, CT and MRI are useful to assess the soft tissue involvement, calcifications, and epidural extension.¹²⁸⁻¹³⁰ MRI provides more precise and superior contrast with surrounding soft tissues compared with CT and is helpful to assess recurrent or metastatic lesions.^{128,129} CT is also of particular importance to assess bony involvement, calcifications, and soft tissue and epidural extension of spinal chordomas, whereas MRI is the best imaging modality to detect tumor extension, cord compression, local recurrence, and residual tumor in the surgical scar tissue after surgical resection.^{131,132} CT is also useful in planning the reconstruction of the resistant osseous defect in tumors of the proximal sacrum.

Treatment

Surgery

Wide excision with adequate margins is the preferred primary treatment for patients with chordoma.^{133,134} A retrospective analysis of 962 patients with chordoma identified in the SEER database demonstrated that surgery significantly improves OS.¹³⁴ Several other reports have confirmed the prognostic significance of wide surgical margins, in terms of relapse-free survival (RFS) and OS, in patients with chordomas of the sacrum,¹³⁵⁻¹³⁸ skull base,¹³⁹⁻¹⁴⁵ and spine.^{137,146,147} Among patients with chordoma of the mobile spine, Boriani and colleagues reported that only margin-free en bloc resection was associated with continuous disease-free survival (DFS) with a follow-up of longer than 5 years; 12 of 18 patients were continuously disease-free at an average of 8 years after en bloc resection, whereas all patients who were treated with intralesional excision



experienced recurrences in less than 2 years.¹⁴⁶ In patients with chordomas of the sacrum and spine, Ruggieri and colleagues reported a local recurrence rate of only 17% following wide surgical margins compared to 81% following intralesional excision or marginal surgery. Tzortzidis and colleagues reported that aggressive microsurgical resection is associated with long-term, tumor-free survival with good functional outcome in patients with cranial base chordomas; gross total removal was achieved in 72% of patients resulting in local control rates of 50%.¹⁴⁰ In a 10-year meta-analysis that included 802 patients with skull base chordoma, Di Maio and colleagues reported that patients with incomplete resection were 3.83 times more likely to experience a recurrence at 5 years than patients with complete resection.^{143,144} In a meta-analysis of 33 noncomparative studies evaluating the management of sacrococcygeal chordomas, the overall mortality rate was found to be lowest with surgical resection followed by adjuvant RT (16%) when compared to either surgical resection (28%) or RT (43%) alone. Additionally, the PFS at 60 months follow-up was highest after surgical resection with adjuvant RT (74%) than when compared to only surgery (55%) or only RT (36%).¹⁴⁸

Radiation Therapy

RT (preoperative, postoperative, or intraoperative) is used in combination with surgery to improve local control and DFS for patients with resectable chordomas. Various retrospective studies and case series have demonstrated improved local control and DFS with combined surgical/RT approaches for treating spinal/sacral^{96,103,149-153} and clival/skull base chordomas.^{139,151,154-158}

A meta-analysis of 464 patients with cranial chordoma revealed a recurrence rate of 68% with an average/median DFS of 23 and 45 months, respectively.¹⁵⁶ Patient subsets with decreased recurrence rates included younger patients, those with chondroid-type chordoma, and patients who received surgery and adjuvant RT.

Particle beam RT (either alone or in combination with photon beam RT) with high-energy protons^{97-100,103,150,157,159-164} or carbon ions^{105,106,165-169} has resulted in local control rates ranging from 62% to 81% in patients with skull base as well as extracranial chordomas involving the spine and sacrum. Carbon ion RT also resulted in preservation of urinary-anorectal function compared with surgery in patients with sacral chordomas.¹⁶⁷

A prospective trial of high-dose photon/proton RT in 50 patients with bone sarcomas of the spine (n = 29 chordoma, 14 chondrosarcoma, 7 other histologies) resulted in 5- and 8-year actuarial local control rates of 94% and 85% for primary tumors and 81% and 74% for primary and locally recurrent tumors. The 8-year actuarial risk of grades 3–4 RT toxicity was 13%.¹⁰³ A subsequent retrospective review of 126 patients with spinal/sacral chordoma who received high-dose proton therapy revealed 5-year OS and local control of 81% and 62%, respectively.¹⁵⁰ A retrospective analysis of 40 patients with unresected chordoma treated with photon/proton RT showed 5-year local control rate and OS of 85.4% and 81.9%, respectively.¹⁷⁰ Similarly, a phase I/phase II trial with 20 patients confirmed to have non-metastatic chordoma or chondrosarcoma treated with proton RT also reported favorable results with a 3-year local control rate of 86% and a PFS of 81%.¹⁷¹ A meta-analysis of 25 studies evaluating the 3-, 5-, and 10-year OS rates of conformal RT (CRT), stereotactic RT, proton therapy, and carbon-ion therapy found that the OS rates were higher for SRT, proton therapy, and carbon-ion therapy when compared to CRT.¹⁷² Specialized techniques such as IMRT and SRS/SRT have also been associated with good local control rates in cranial as well as extracranial chordomas.^{104,173-177}

Systemic Therapy

Chordomas are not sensitive to chemotherapy except for the potentially dedifferentiated portion of high-grade dedifferentiated chordomas.¹⁷⁸ Several signal transduction pathways including PDGFR, epidermal growth



factor receptor (EGFR), and mammalian target of rapamycin (mTOR) have been implicated in the pathogenesis of chordomas, leading to the development of targeted therapies.^{179,180}

In a phase II trial of 56 patients with advanced chordoma treated with imatinib, a tyrosine kinase inhibitor, 70% of patients had stable disease. The clinical benefit rate (CBR) as determined by RECIST criteria (complete response + partial response and stable disease ≥ 6 months) was 64%, and the median PFS in the intention-to-treat population was 9 months.³⁶ Imatinib in combination with cisplatin or sirolimus has also been effective in a small series of patients with advanced chordoma resistant to prior imatinib therapy.^{181,182} A retrospective study of imatinib in advanced, progressive, and inoperable chordoma achieved stable disease in 74% of patients, with a median PFS of 9.9 months.¹⁸³ The efficacy of EGFR inhibitors such as erlotinib and lapatinib has also been demonstrated in patients with advanced chordoma resistant to imatinib.¹⁸⁴⁻¹⁸⁶ In a phase II study of 18 patients with locally advanced and metastatic chordoma, lapatinib induced partial response in 33% of patients and 39% of patients had stable disease, based on Choi response criteria, whereas all patients had stable disease based on RECIST criteria.¹⁸⁶ The median PFS was 6 months and 8 months (with a CBR of 22%) based on Choi and RECIST criteria, respectively.

The multi-kinase inhibitor sorafenib is included as a systemic therapy option based on data from a phase II trial in 27 patients with advanced/metastatic chordoma. In this trial, the intent-to-treat best objective response was 1/27 (3.7%; 95% CI, 0.1%–19.0%), 9-month PFS was 73.0% (95% CI, 46.1–88.0), and 12-month OS was 86.5% (95% CI, 55.8–96.5).^{187,188}

Dasatinib is also included as a systemic therapy option based on data from the SARC009 indolent sub-study that included 32 patients with unresectable, recurrent, or metastatic chordoma.¹¹⁵ The primary endpoint

was PFS at 6 months using the Choi criteria, which for patients with chordoma was 54%. For patients with chordoma, the median PFS was 6.3 months and 5-year OS was 18%. The authors also compared reported patient outcomes in selected phase 2 studies in patients with chordomas and no substantial differences in overall response rate (ORR), median PFS, or 6-months PFS compared with imatinib or lapatinib treatment.

NCCN Recommendations

Tumor location is the most important variable that determines the choice of primary treatment for patients with conventional or chondroid chordomas. Dedifferentiated and poorly differentiated chordomas are usually managed as described in the NCCN Guidelines for Soft Tissue Sarcoma.

Wide excision with or without RT is the primary treatment option for patients with resectable conventional or chondroid chordomas of the sacrum and mobile spine.^{133,134} Intralesional excision with or without RT (followed by MRI to assess the adequacy of resection) is the treatment of choice for patients with resectable skull base tumors of conventional or chondroid histology. Maximal safe resection is recommended when appropriate.¹⁴² Adjuvant treatment with RT can be considered for large extra-compartmental tumors or for positive surgical margins following resection. Postoperative RT has been associated with improved local control and DFS following surgery with macroscopic surgical margins or intralesional excision.^{149,151,156,189,190} Re-resection, if necessary, can be considered for skull base tumors with positive surgical margins.

RT is the primary treatment option for patients with unresectable chordomas, irrespective of the location of the tumor.

Surveillance

Surveillance consists of a physical exam, imaging (ie, x-ray, CT with contrast \pm MRI with contrast) of surgical site (timing and modality as



clinically indicated) for up to 10 years, and chest imaging (every 6 months for 5 years and annually thereafter; may include CT annually; chest CT may be done with or without contrast as clinically indicated).

Relapsed Disease

Chordomas are characterized by a high rate of local recurrence, and distant metastases to lungs, bone, soft tissue, lymph nodes, liver, and skin have been reported in up to 40% of patients with local recurrence.^{135,159,191,192} Among patients with recurrent chordomas of skull base and spine, Fagundes and colleagues reported a higher 2-year actuarial OS rate for patients treated with subtotal resection than those who received supportive care only (63% and 21%, respectively; $P = .001$).¹⁵⁹ However, some studies have reported that surgery and RT are associated with lower local control rates for recurrent tumors than for primary tumors in patients with sacral chordomas.^{161,175} A study in 25 patients demonstrated effective local control and low acute toxicity with carbon ion RT in patients with recurrent skull base chordoma or chondrosarcoma.¹¹⁸

Patients with recurrent disease can be managed with surgery and/or RT¹⁹³ and/or systemic therapy. The guidelines include imatinib with or without cisplatin or sirolimus, erlotinib, sunitinib, lapatinib (for patients with EGFR-positive disease), sorafenib, and dasatinib as systemic therapy options for patients with recurrent tumors.

Ewing Sarcoma

Ewing sarcoma is characterized by the fusion of the *EWS* gene (*EWSR1*) on chromosome 22q12 with various members of the *ETS* gene family (*FLI1*, *ERG*, *ETV1*, *ETV4*, and *FEV*).^{8,9} The *EWS-FLI1* fusion transcript resulting from the fusion of *EWS* and *FLI1* on chromosome 11 and the corresponding chromosomal translocation, t(11;22)(q24;q12), is identified in about 85% of patients with Ewing sarcoma.⁸ In 5% to 10% of cases,

EWS is fused with other members of the *ETS* gene family. In rare cases, *FUS* can substitute for *EWS* resulting in fusion transcripts with no *EWS* rearrangement [*FUS-ERG* fusion transcript resulting from the translocation t(16;21)(p11;q24) or *FUS-FEV* fusion transcript resulting from the translocation t(2;16)(q35;p11)].^{194,195} Overall, 90% of Ewing sarcoma will have one of four cytogenetic translocations. Ewing sarcoma is also characterized by the strong expression of cell surface glycoprotein MIC2 (CD99).^{196,197} The expression of MIC2 may be useful in the differential diagnosis of Ewing sarcoma and primitive neuroectodermal tumor (PNET) from other small round-cell neoplasms, although it is not exclusively specific to these tumors.¹⁹⁸ Similar in morphology with various molecular signatures, Ewing-like sarcomas are a heterogeneous group of tumors that namely affect the pediatric and adolescent population.¹⁹⁹ Ewing-like tumors have been divided into three main categories based on cytogenetics: CIC-rearranged sarcomas (eg, CIC-DUX4), BCOR-rearranged sarcomas, and round cell sarcomas with EWSR1 fusions with non-ETS genes.²⁰⁰

Typically, Ewing sarcoma occurs in adolescents and young adults. The most common primary sites are the pelvic bones, femur, and the bones of the chest wall, although any bone may be affected.²⁰ When arising in a long bone, the diaphysis is the most frequently affected site. On imaging, the bone appears mottled. Periosteal reaction is classic and it is referred to as “onion skin” by radiologists.

Patients with Ewing sarcoma, as with most patients with bone sarcomas, seek attention because of localized pain or swelling. Unlike other bone sarcomas, constitutional symptoms such as fever, weight loss, and fatigue are occasionally noted at presentation. Abnormal laboratory studies may include elevated serum LDH and leukocytosis.



Prognostic Factors

The important indicators of favorable prognosis include a distal/peripheral site of primary disease, tumor volume <100 mL, normal LDH level at presentation, and the absence of metastatic disease at the time of presentation.²⁰¹⁻²⁰⁷ Ewing sarcoma in the spine and sacrum is associated with significantly worse outcome and prognosis than primary Ewing sarcoma in other sites.²⁰⁸ In a systematic review, Bosma and colleagues also reported tumor size (diameter more than 8 cm) and histologic response (90% or more necrosis) to be important prognostic variables.²⁰⁹ Nevertheless, metastatic disease at presentation is the most significant adverse prognostic factor in Ewing sarcoma, as it is for other bone sarcomas.^{23,205,210} Lungs, bone, and bone marrow are the most common sites of metastasis. In a retrospective analysis of 975 patients from the EICESS Study Group, 5-year RFS was 22% for patients with metastatic disease at diagnosis compared with 55% for patients without metastases at diagnosis.²³ Among patients with metastases, there was a trend for better survival for those with lung metastases compared to those with bone metastases or a combination of lung and bone metastases.²³ Metastases to uncommon sites (ie, brain, liver, spleen) were associated with a worse prognosis in a retrospective study of 30 patients.²¹¹ Poor histologic/radiologic response to chemotherapy has also been identified as an adverse prognostic factor in patients with localized non-metastatic disease,^{204,212,213} even when chemotherapy was followed by R0 resection.²¹⁴

The results of the IESS study analyzing the clinicopathologic features of 303 cases of Ewing sarcoma showed that patients with primary tumors in pelvic bones have lower survival rates compared with patients with lesions in distal bones of the extremities.²¹⁵ In an analysis of 53 patients (24 adult and 29 pediatric) with Ewing sarcoma treated with chemotherapy, Gupta and colleagues identified pelvic disease and time to local therapy as significant prognostic factors associated with EFS in a multivariate

analysis.²¹⁶ In another retrospective analysis of patients with Ewing sarcoma from a large population-based cancer registry, Lee and colleagues determined that adult age, Hispanic race, metastatic disease, large tumor size, and low socioeconomic status are poor prognostic factors for OS.²¹⁷

Workup

If Ewing sarcoma is suspected as a diagnosis, the patient should undergo complete staging prior to biopsy. This should include CT of the chest with or without contrast as clinically indicated; MRI with or without CT of the primary site; head-to-toe PET/CT and/or bone scan; and possibly bone marrow biopsy and/or screening MRI of the spine and pelvis. In a systematic review and meta-analysis, Treglia and colleagues reported that the combination of PET/CT with conventional imaging is a valuable tool for the staging and restaging of Ewing sarcoma, with 96% sensitivity and 92% specificity.²¹⁸ An ongoing diagnostic study is comparing whole-body MRI and conventional imaging for detecting distant metastases in pediatric patients with Ewing sarcoma, Hodgkin lymphoma, non-Hodgkin lymphoma, rhabdomyosarcoma, and neuroblastoma.

Cytogenetic and/or molecular studies of the biopsy specimen should be performed to evaluate the t(11;22) translocation. Preliminary reports suggest that *EWS-FLI1* translocation is associated with a better prognosis than other variants.²¹⁹⁻²²¹ However, reports from the EURO-EWING 99 study and the Children's Oncology Group study suggest that with currently available effective therapies, patients with Ewing sarcoma have similar outcomes, regardless of fusion subtype in contrast to previous reports.^{222,223} In addition to *EWS*, *FUS* should be considered as a fusion gene partner in the molecular diagnosis to identify the rare cases of Ewing sarcoma with *FUS-ERG* or *FUS-FEV* fusion transcripts.^{194,195} Since serum LDH has been shown to have prognostic value as a tumor marker, the



guidelines have included this test as part of initial evaluation. Fertility consultation should be considered as appropriate.

Treatment

Chemotherapy

Multiagent chemotherapy regimens including vincristine, doxorubicin, and cyclophosphamide alternating with ifosfamide and etoposide have been shown to be effective in patients with localized Ewing sarcoma in single- as well as multi-institution collaborative trials in the United States and Europe. Multiagent chemotherapy for at least 9 weeks is recommended prior to surgery to downstage the tumor and increase the probability of achieving a complete resection with microscopically negative margins. Adjuvant chemotherapy following surgical resection improves RFS and OS in a majority of patients.²²⁴⁻²²⁸ Surgical resection with or without RT is used for local control following chemotherapy.

The addition of ifosfamide, alone or in combination with etoposide to standard chemotherapy, was evaluated in patients with newly diagnosed, non-metastatic Ewing sarcoma.^{226,229-233} In the Pediatric Oncology Group-Children's Cancer Group (POG-CCG) study (INT-0091), 398 patients with non-metastatic Ewing sarcoma were randomized to receive chemotherapy with either vincristine, doxorubicin, VACD alone or alternating with ifosfamide and etoposide (VACD-IE) for a total of 17 cycles.²²⁶ The 5-year EFS rate was significantly higher in the VACD-IE group than the VACD alone group (69% and 54%, respectively; $P = .005$). The 5-year OS rate was also significantly better among patients in the VACD-IE group (72% and 61%, respectively; $P = .01$). VACD-IE also was associated with lower incidences of local failure (11%) compared with VACD (30%) irrespective of the type of local control therapy; 5-year cumulative incidences of local failure were 30% in the VACD arm compared with 11% in the VACD-IE arm.²³⁴

While dose escalation of alkylating agents in the VDC-IE regimen did not improve the outcome for patients with localized disease,²³⁵ chemotherapy intensification through interval compression improved outcome in patients with localized disease.²³⁶ In a randomized trial for patients younger than 50 years with localized Ewing sarcoma ($n = 568$), Womer and colleagues reported that VDC-IE given on an every-2-week schedule was found to be more effective than VDC-IE given on an every-3-week schedule, with no increase in toxicity; median 5-year EFS was 73% and 65%, respectively.²³⁶

The Euro Ewing 2012 (EE2012) was a randomized analysis conducted to compare the induction and consolidation regimens for newly diagnosed Ewing sarcoma in both the United States and Europe. Six hundred forty patients between the ages of 5 to 50 years were randomized to two treatment arms, A and B. Treatment arm A received the European regimen: VIDE induction therapy followed by VAI or VAC consolidation. Treatment arm B received the U.S. regimen: compressed VDC/IE induction followed by IE/VC consolidation. The primary endpoint of the study was PFS while the secondary endpoints were OS and toxicity. The VDC/IE regimen proved superior to the European regimen in terms of PFS and OS with similar toxicity profiles.²³⁷

IESS-I and IESS-II showed that RT plus adjuvant chemotherapy with VACD (vincristine, dactinomycin, cyclophosphamide, and doxorubicin) was superior to VAC (vincristine, dactinomycin, and cyclophosphamide) in patients with localized non-metastatic disease.²²⁵ The 5-year RFS rate was 60% and 24% for VACD and VAC, respectively ($P < .001$). The corresponding OS rate was 65% and 28% ($P < .001$).

In the INT-0091 study, which included 120 patients with metastatic disease, there was no significant difference, however, in the EFS and OS rates between VACD-IE and VACD regimens.²²⁶ The 5-year EFS rate was 22% for both regimens and the 5-year OS rate was 34% and 35% for the



VACD-IE and VACD groups, respectively. In a study of 68 patients (44 patients with locoregional disease and 24 patients with distant metastases), Kolb and colleagues reported 4-year EFS and OS rates of 82% and 89%, respectively, for patients with locoregional disease treated with intensive chemotherapy (doxorubicin and vincristine with or without high-dose cyclophosphamide) followed by ifosfamide and etoposide.²³¹ In patients with distant metastases the corresponding survival rates were 12% and 18%, respectively. Miser and colleagues also reported similar findings in patients with Ewing sarcoma or PNET of bone with metastases at diagnosis.²³⁸

The EICESS-92 study investigated whether cyclophosphamide has a similar efficacy as ifosfamide in patients with standard-risk Ewing sarcoma (small localized tumors) and whether the addition of etoposide to a regimen already containing ifosfamide improves survival in patients with high-risk disease (large tumors or metastatic disease at diagnosis).²³⁹ Patients with standard-risk disease were randomly assigned to VAIA (vincristine, dactinomycin, ifosfamide, and doxorubicin; n = 76) followed by either VAIA or VACA (vincristine, dactinomycin, cyclophosphamide, and doxorubicin; n = 79).²³⁹ The 3-year EFS rates were 73% and 74%, respectively, for VACA and VAIA, suggesting that cyclophosphamide has the same efficacy as ifosfamide in this group of patients. Patients with high-risk disease were randomly assigned to VAIA or VAIA plus etoposide (EVAIA). The 3-year EFS rate was not significantly different between the two treatment groups (52% and 47%, respectively, for EVAIA and VAIA). However, there was some evidence that the addition of etoposide was associated with a greater survival benefit in the subgroup of patients without metastases ($P = .18$) than in those with metastases ($P = .84$).²³⁹

As a follow-up to the EICESS-92 study, the Euro-EWING99-R1 trial evaluated cyclophosphamide as a replacement for ifosfamide as a part of consolidation therapy that also included vincristine and dactinomycin (VAC

vs. VAI [vincristine, dactinomycin, ifosfamide]) after VIDE (vincristine, ifosfamide, doxorubicin, and etoposide) induction chemotherapy in 856 patients with standard-risk Ewing sarcoma. VAC was statistically not inferior to VAI, but was associated with a slight increase in events (-2.8% decrease in 3-year EFS). The proportion of patients experiencing severe hematologic toxicity was slightly higher in the VAC arm, but renal tubular function impairment was more significant for patients receiving VAI.²⁴⁰

High-Dose Therapy Followed by Hematopoietic Stem Cell Transplant

High-dose therapy followed by hematopoietic stem cell transplant (HDT/HCT) has been evaluated in patients with localized as well as metastatic disease. HDT/HCT has been associated with potential survival benefit in patients with non-metastatic disease.^{241,242} However, studies that have evaluated HDT/HCT in patients with primary metastatic disease have shown conflicting results.²⁴³⁻²⁴⁹

The EURO-EWING 99 study was the first large randomized trial designed to evaluate the efficacy and safety of multiagent induction chemotherapy with 6 courses of VIDE, local treatment (surgery and/or RT), and HDT/HCT in 281 patients with Ewing sarcoma with primary disseminated disease.²⁴⁴ After a median follow-up of 3.8 years, the EFS and OS rates at 3 years for the entire study cohort were 27% and 34%, respectively.²⁴⁸ The EFS rates were 57% and 25%, respectively, for patients with complete and partial response after HDT/HCT. Patient's age, tumor volume, and extent of metastatic spread were identified as relevant risk factors. The outcome of patients with and without HDT/HCT was not performed because of the bias introduced early in the non-transplant group (82% of patients without HDT/HCT died after a median time of 1 year).

The EURO-EWING 99 and Ewing-2008 randomized trial asked whether consolidation high-dose chemotherapy improved survival in patients with localized Ewing sarcoma.²⁴⁹ Two hundred forty high-risk patients were randomly assigned to receive seven VAI courses (n = 118) or one course



of busulfan and melphalan (BuMel) HDT with autologous HCT (n = 122), after a VIDE 6-course induction plus one VAI consolidation course. Patients were followed for 15 years; median follow-up time was 7.8 years. BuMel-treated patients had greater improvement in 3-year EFS (69.0% vs. 56.7%) and 8-year EFS (60.7% vs. 47.1%) compared to VAI-treated patients. There were three treatment-related deaths: two due to BuMel toxicity and one due to VAI toxicity. More patients experienced severe acute toxicities related to BuMel versus VAI course.

Local Control Therapy

Surgery and RT are the local control treatment modalities used for patients with localized disease, but no randomized trials have compared these approaches head-to-head.

In patients with localized Ewing sarcoma treated in cooperative intergroup studies there was no significant effect of local control modality (surgery, RT, or surgery plus RT) on OS or EFS rates.^{234,250} In the CESS 86 trial, although radical surgery and resection plus RT resulted in better local control rates (100% and 95%, respectively) than definitive RT (86%), there was no improvement in RFS or OS because of higher frequency of metastases after surgery.²⁵⁰ In the INT-0091 study, the incidences of local failure were similar for patients treated with surgery or RT alone (25%), but surgery plus RT resulted in lower incidences of local failure (10.5%).²³⁴ The 5-year EFS rate was also not significantly different between the groups (42%, 52%, and 47% for patients treated with surgery, RT, and surgery plus RT, respectively).

Data from other retrospective analyses suggest that surgery (with or without postoperative RT) affords better local control than RT alone in patients with localized disease.^{251,252} The combined analysis of 1058 patients treated in the CESS 81, CESS 86, and EICESS 92 trials showed that the rate of local failure was significantly lower after surgery (with or without postoperative RT) than after definitive RT (7.5% vs. 26.3%,

respectively; $P = .001$), whereas the local control rate with preoperative RT was comparable to that of the surgery group (5.3%).²⁵¹ The most recent retrospective analysis of sequential studies (INT-0091, INT-0154, or AEWS0031) performed by the Children's Oncology Group also demonstrated that definitive RT was associated with a higher risk of local failure than surgery plus RT, but there was no effect on distant failure.²⁵² Definitive RT could be an effective treatment option for patients with tumors in anatomical locations not amenable to achieve surgery with wider resection margins.^{253,254} In a retrospective analysis of patients with Ewing sarcoma of vertebrae treated in the CESS 81/86 and EICESS 92 studies, definitive RT resulted in a local control rate of 22.6%, which was comparable to those of other tumor sites treated with definitive RT; EFS and OS at 5 years were 47% and 58%, respectively.²⁵³ Tumor size and RT dose have been shown to be predictive of local control rates in patients with non-metastatic Ewing sarcoma treated with chemotherapy and definitive RT.^{255,256} Local control therapy has also been associated with improved outcomes in patients with primary metastatic disease.²⁵⁷⁻²⁵⁹ In the EURO-EWING 99 trial, the 3-year EFS was significantly lower in patients with primary metastatic disease who did not receive any local control therapy compared to those treated with local therapy for primary tumor.²⁵⁷ Retrospective analysis of 198 patients from EURO-EWING 99 showed no improvement of 5-year EFS associated with adjuvant RT in the setting of completely resected disease of the chest wall.²⁶⁰

NCCN Recommendations

All patients with Ewing sarcoma should be treated with the following protocol: primary treatment followed by local control therapy and adjuvant treatment. Primary treatment consists of multiagent chemotherapy along with appropriate growth factor support for at least 9 weeks (category 1). Longer duration could be considered for patients with metastatic disease based on response. VDC/IE (vincristine, doxorubicin, and cyclophosphamide alternating with ifosfamide and etoposide) is the



preferred regimen for patients with localized disease and is a category 1 recommendation. See *Bone Cancer Systemic Therapy Agents* in the algorithm for a list of other chemotherapy regimens that are recommended for patients with localized and metastatic disease.

Disease should be restaged with imaging following primary treatment. Chest imaging should be performed with CT and primary site imaging should include MRI with or without CT and plain radiographs. Head-to-toe PET/CT and/or bone scan can be used for restaging depending on the imaging technique that was used in the initial workup. Patients with stable or improved disease after primary treatment should be treated with local control therapy. Local control options include wide excision, definitive RT with chemotherapy, or amputation in selected cases.^{251,253,255,257} The choice of local control therapy should be individualized and is dependent on tumor location, size, response to chemotherapy, patient's age, anticipated morbidity, and patient preference.²³⁴

Adjuvant chemotherapy following wide excision or amputation is recommended for all patients regardless of surgical margins. The panel strongly recommends that the duration of chemotherapy following wide excision or amputation should be between 28 and 49 weeks depending on the type of regimen and the dosing schedule (category 1).²²⁴⁻²²⁶ The addition of postoperative RT to chemotherapy is recommended for patients with positive or very close surgical margins.²⁵¹ Denbo and colleagues reported that in patients with smaller tumor size (<8 cm) and negative margins, postoperative RT can be omitted without any decrement in OS.²⁶¹ The 15-year estimated OS for patients who received adjuvant RT was 80% compared to 100% for those who did not. The guidelines have included adjuvant chemotherapy alone for patients treated with wide excision and negative margins.

In the setting of widely metastatic disease, palliative therapies may be considered. For metastatic disease that may be amenable to local therapy,

local control modalities, in the form of wide excision or definitive RT with adjuvant chemotherapy, are recommended. Regardless of postoperative margin status, chemotherapy for at least 28 to 49 weeks is to be administered (category 1). RT may be considered for positive surgical margins. Following adjuvant treatment, metastases may be managed according to the location. In the case of oligometastatic disease, resection or RT is recommended. For pulmonary metastases, dependent on the response, resection or whole lung irradiation (WLI) may be considered. Based on the EORTC-SIOP phase III study published in 1988, which concluded there to be no survival benefit of WLI over adjuvant chemotherapy for patients with osteosarcoma, a systematic review of both prophylactic as well as curative WLI in patients with osteosarcoma and Ewing sarcoma was conducted.^{262,263} Only two studies compared the results of chemotherapy alone and chemotherapy and curative WLI in patients with metastatic Ewing sarcoma. In both trials, patients reported some benefit with WLI and chemotherapy when compared to chemotherapy alone. For instance, in the EICESS-92 trial, patients who also received WLI showed a 12% improvement in 5-year OS.^{263,264} Ultimately, it was concluded that the decision to use WLI should be based on the patient's risk of pulmonary metastases and any coexisting respiratory diseases.²⁶³ Progressive disease following primary treatment is best managed with RT and/or surgery to primary site followed by chemotherapy or best supportive care.

Surveillance

Surveillance of patients with Ewing sarcoma should include a physical exam, CBC and other laboratory studies, and cross-sectional imaging (MRI with or without CT) and plain radiographs of the primary site. Chest imaging (x-ray or CT) is recommended every 2 to 3 months. Head-to-toe PET/CT or bone scan can be considered. Surveillance intervals should be increased after 2 years. Long-term surveillance should be performed annually after 5 years (category 2B).²⁶⁵

**Relapsed or Refractory Disease**

About 30% to 40% of patients with Ewing sarcoma experience recurrence (local and/or distant) and have a very poor prognosis. Patients with a longer time to first recurrence have a better chance of survival following recurrence. Late relapse (2 years or more from the time of original diagnosis), lung-only metastases, local recurrence that can be treated with radical surgery, and intensive chemotherapy are the most favorable prognostic factors, whereas early relapse (less than 2 years from the time of original diagnosis) with metastases in lungs and/or other sites, recurrence at local and distant sites, elevated LDH at initial diagnosis, and initial recurrence are considered adverse prognostic factors.²⁶⁶⁻²⁶⁹ In a retrospective analysis, site of first relapse and time to first relapse were significant prognostic factors for adult patients with localized Ewing sarcoma.²⁷⁰ The probability of 5-year post-relapse survival was 55% and 22%, respectively, for patients with local and distant relapse. The probability of 5-year post-relapse survival was also significantly higher for patients with late relapse than for those with early relapse.^{23,270,271} Overall, it is reported that close to 70% of relapses are early relapses, of which two-thirds occur at distant sites (in the lungs and/or bones). Patients who initially presented with widespread disease are more likely to relapse at distant sites, whereas those individuals who presented with localized disease are more likely to develop local relapse.²⁷²

Topoisomerase I inhibitors (topotecan and irinotecan) in combination with cyclophosphamide and temozolomide have been associated with favorable response rates in patients with relapsed or refractory bone sarcomas.²⁷³⁻²⁷⁹ In a series of 54 patients with relapsed or refractory Ewing sarcoma, cyclophosphamide and topotecan induced responses in 44% of patients (35% of patients had complete response and 9% had partial response).²⁷⁴ After a median follow-up of 23 months, 26% of patients were in continuous remission. In a retrospective analysis of patients with recurrent or progressive Ewing sarcoma, irinotecan and temozolomide

resulted in an overall objective response rate of 63%. The median time to progression (TTP) for all the evaluable patients (n = 20) was 8.3 months (16.2 months for the subset of patients with recurrent disease).²⁷⁷ Patients who were in a 2-year first remission and those with primary localized disease had better median TTP compared to those who relapsed within 2 years from diagnosis and patients with metastatic disease at diagnosis.

Combination therapy with vincristine, irinotecan, and temozolomide also appears to be active and well-tolerated in patients with relapsed or refractory Ewing sarcoma, with an ORR of 68.1%.²⁸⁰ A review of 107 patients with relapsed or refractory Ewing sarcoma examined the combination of etoposide with a platinum agent (ie, cisplatin or carboplatin), suggesting that further study of etoposide/carboplatin may be warranted.²⁸¹ HDT/HCT has been associated with improved long-term survival in patients with relapsed or progressive Ewing sarcoma in small, single-institution studies.²⁸²⁻²⁸⁴ The role of this approach is yet to be determined in prospective randomized studies.

The CABONE trial, a multicenter, single-arm phase 2 trial, evaluated the activity of cabozantinib in patients with advanced Ewing sarcoma and osteosarcoma.²⁸⁵ Currently approved for renal carcinoma, hepatocellular carcinoma, and medullary thyroid cancer, cabozantinib is a VEGFR2 tyrosine kinase inhibitor with inhibitory activity against the MET receptor. For Ewing sarcoma, the primary endpoint in this study was 6-month objective response, while the secondary endpoints included safety, 6-month non-progression, best overall response, 1-year and 2-year PFS and OS, and metabolic response (evaluated by ¹⁸F-FDG PET-CT 28 days after the first dose). The primary endpoint was reached with a 6-month objective response of 25.6% (95% CI, 13.–42.1) among 39 patients with Ewing sarcoma. Additionally, the median OS was reported to be 10.2 months with a median PFS of 4.4 months. OS was noted to be 84% at 6 months, 48% at 12 months, and finally 14% at 24 months. Forty two



percent (95% CI, 25–61) of patients exhibited a metabolic tumor response. Lastly, cabozantinib was found to be well-tolerated among patients with the most common grade 3 or 4 adverse effects being hypophosphatemia and elevated aspartate aminotransferase (AST).²⁸⁵

Finally, docetaxel in combination with gemcitabine was well-tolerated, resulting in an overall objective response rate of 29% in children and young adults with refractory bone sarcomas; median duration of response was 4.8 months.²⁸⁶

NCCN Recommendations

Treatment options for patients with relapsed or refractory disease include participation in a clinical trial and chemotherapy with or without RT. If a relapse is delayed, as sometimes occurs with this sarcoma, re-treatment with a previously effective regimen may be useful. See *Bone Cancer Systemic Therapy Agents* in the algorithm for a list of other chemotherapy regimens recommended for patients with relapsed or refractory disease.

All patients with recurrent and metastatic disease should be considered for clinical trials investigating new treatment approaches.

Giant Cell Tumor of Bone

GCTB is a rare benign primary tumor of the bone accounting for about 3% to 5% of all primary bone tumors, with a strong tendency for local recurrence and that may metastasize to the lungs.^{287,288} GCTB usually occurs between 20 and 40 years of age. The meta-epiphyseal regions of the distal femur and proximal tibia are the most common primary sites.²⁸⁹ Malignant transformation to high-grade osteosarcoma has been observed in rare cases and is associated with a poor prognosis.^{290,291}

Workup

Initial workup should include history and physical examination with imaging (ie, x-ray, CT ± MRI [both with contrast]) of the primary site as

clinically indicated, in addition to chest imaging. CT is useful to define the extent of cortical destruction, whereas MRI is the preferred imaging modality to assess the extension of tumors into the adjacent soft tissue and neurovascular structures.^{292,293} Chest imaging is essential to identify the presence of metastatic disease. Bone scan can be considered for unusual cases. Biopsy is essential to confirm the diagnosis. Brown tumor of hyperparathyroidism should be considered as a differential diagnosis; routine evaluation of serum calcium, phosphate, and parathyroid hormone levels can help exclude this diagnosis.²⁹⁴

Treatment

Surgery

Wide excision and intralesional curettage are the two surgical treatment options for patients with resectable tumors.²⁹⁵⁻³⁰¹ Wide excision is associated with a lower risk of local recurrence than intralesional curettage, with the local recurrence rates ranging from 0% to 12% for wide excision and 12% to 65% for intralesional curettage. In some studies, the extent of intralesional excision and the tumor stage have been identified as prognostic indicators for risk of recurrence.³⁰²⁻³⁰⁴ Blackley and colleagues reported a local recurrence rate of 12% in 59 patients who were treated with curettage with high-speed burr and bone grafting, which was similar to that observed with the use of adjuvants; the majority of the patients had grade II or III tumors.³⁰³ In another retrospective analysis of 137 patients, Prosser and colleagues reported local recurrences in 19% of patients following curettage as a primary treatment; local recurrence rate was only 7% for patients with grade I and II tumors confined to the bone compared with 29% for those with grade III tumors with extraosseous extension.³⁰⁴

Surgical adjuvants have been used in conjunction with intralesional curettage to improve local control rates. However, the findings from studies that have evaluated intralesional curettage, with and without



adjuvant in the same cohort of patients with primary or recurrent GCTB, are inconsistent, with some reporting decreased local recurrence rates with the use of adjuvants.^{299,305-308} Others, however, have reported no significant difference in local recurrence rates with and without adjuvants.^{136,309,310}

Wide excision is also associated with poor functional outcome and greater surgical complications.³¹¹⁻³¹⁵ Therefore, intralesional curettage is considered the treatment of choice in a majority of patients with stage I or II tumors. Wide excision is usually reserved for more aggressive stage III tumors with extraosseous extension or otherwise unresectable tumors.^{304,316-319}

Radiation Therapy

RT has been used either as a primary treatment or in combination with surgery to improve local control and DFS for patients with marginally resected, unresectable, progressive, or recurrent disease.³²⁰⁻³³¹ In a retrospective analysis of 58 patients with GCTB (45 patients with primary tumor and 13 patients with recurrent tumor) treated with RT, the 5-year local control and OS rates were 85% and 94%, respectively.³³⁰ Median follow-up was 8 years. In this analysis, patient age was the only prognostic factor with the local control rates (96% for younger patients vs. 73% for the older group) as well as OS (100% vs. 87%) and DFS rates (96% vs. 65%). Other studies have identified tumor size >4 cm, recurrent tumors, and RT doses of 40 Gy or less as negative prognostic factors for local control.^{326-328,331}

Specialized techniques such as 3-D CRT and IMRT have also been associated with good local control rates in patients with GCTB in locations that are not amenable to complete surgical resection.^{332,333}

Adverse side effects have occurred from RT. As GCTB is a benign growth, use of radiation should be considered more risky than for malignant

tumors. Therefore, the panel recommends that RT should be considered if no other treatment options are available, if possible.

Systemic Therapy

Denosumab (a fully humanized monoclonal antibody against the RANK ligand) has demonstrated activity in patients with unresectable or recurrent GCTB.³³⁴⁻³³⁷ In June 2013, denosumab was approved by the FDA for the treatment of adults and skeletally mature adolescents with GCTB that is unresectable or where surgical resection is likely to result in severe morbidity.

Several phase II trials have examined the efficacy of denosumab for treating primary and recurrent GCTB. In an open-label, phase II study (n = 37), denosumab induced tumor response (defined as the elimination of at least 90% of giant cells or no radiologic progression of the target lesion for up to 25 weeks) in 86% (30 of 35 evaluable patients) of patients with unresectable or recurrent GCTB.³³⁴ An open-label, parallel-group, phase II study divided patients with GCTB into three cohorts: those with unresectable GCTB (cohort 1), those with resectable GCTB associated with severe surgical morbidity (cohort 2), and those transferred from a previous study of denosumab for GCTB (cohort 3).^{336,338} After a median follow-up of 13 months, 96% of evaluable patients (163 of 169) in cohort 1 had no disease progression.³³⁶ Clinically significant reductions in pain were reported by over half of the study patients within 2 months.³³⁹ Final analysis of outcomes from cohort 2 (n = 222) showed that denosumab enabled 48% of patients to delay/avoid surgery and 38% to undergo less morbid resections.

The risk of local recurrence has been reported to be higher when denosumab is used prior to curettage. In a retrospective analysis of 408 patients treated for GCTB using either intralesional curettage or wide excision, the local recurrence rate for patients treated with curettage and denosumab was 60%, compared to 16% for those individuals treated with



curettage alone.³⁴⁰ Additionally, the joint preservation rate of patients managed with curettage and denosumab was 80% compared to 94% for those treated with curettage alone. Although denosumab usage was reported to be the only independent factor associated with increased recurrence, it is likely that such an association may also stem from selection bias.³⁴⁰ Use of denosumab before surgery may aid in defining a peripheral rim around the tumor, however.^{341,342}

Phase II trial data have also suggested that sequential FDG-PET imaging appears to be a sensitive tool for early detection of tumor response to denosumab treatment.³⁴³

There have been reports of increased risk for developing osteosarcoma associated with denosumab therapy.^{344,345} The data are limited to determine the cause for the increased risk, but the NCCN Panel identifies some possibilities, such as spontaneous conversion to a secondary sarcoma, or a diagnostic and/or sampling error that erroneously categorizes a tumor as GCTB.

NCCN Recommendations

Localized Disease

Intralesional excision with or without an effective adjuvant is an adequate primary treatment for resectable tumors.^{136,309,310}

Serial arterial embolizations have been shown to be effective in the management of patients with giant cell tumors of the extremities, especially for tumors with large cortical defects or joint involvement and for those with large giant cell tumors of the sacrum.³⁴⁶⁻³⁴⁹ A few case reports have reported the efficacy of interferon (IFN) in the management of GCTB.³⁵⁰⁻³⁵³

For patients with lesions that are resectable with unacceptable morbidity or unresectable axial lesions, the guidelines have included denosumab

and/or serial embolizations as preferred options. Another primary treatment option is IFN-alfa-2b. RT may be associated with increased risk of malignant transformation and should be used in patients with tumors that are not amenable to embolization, denosumab, or IFNs. Imaging should be used to assess treatment response and should include plain radiographs as well as CT with or without MRI.

Following primary treatment, patients with stable/improved disease can be observed. For patients with stable/improved disease with incomplete healing following primary treatment, intralesional excision is recommended if the lesion has become resectable. Patients with unresectable disease should be retreated with denosumab, serial embolization, and/or IFN-alfa-2b. The guidelines recommend continuation of treatment until disease progression.

Metastatic Disease

For patients presenting with resectable metastases, the guidelines recommend that primary tumor be managed as described above for localized disease.^{287,288,354,355} Intralesional excision is recommended for resectable metastatic sites. Denosumab, IFN, observation, and RT are included as options for patients with unresectable metastases.

Surveillance

Surveillance should include a physical exam, imaging (ie, x-ray, CT ± MRI [both with contrast]) of the surgical site as clinically indicated, and chest imaging every 6 months for 2 years then annually thereafter.

Recurrent disease (local or metastatic) should be managed as per primary treatment for localized disease or metastatic disease at presentation.

Osteosarcoma

Osteosarcoma is the most common primary malignant bone tumor in children and young adults. The median age for all patients with



osteosarcoma is 20 years. In adults older than 65 years, osteosarcoma develops as a secondary malignancy related to Paget's disease of the bone.¹⁶ Osteosarcoma is broadly classified into three histologic subtypes (intramedullary, surface, and extraskeletal).³⁵⁶

High-grade intramedullary osteosarcoma is the classic or conventional form comprising nearly 80% of osteosarcomas.³⁵⁶ It is a spindle cell tumor that produces osteoid or immature bone. The most frequent sites are the metaphyseal areas of the distal femur or proximal tibia, which are the sites of maximum growth. Low-grade intramedullary osteosarcoma comprises less than 2% of all osteosarcomas and the most common sites are similar to that of conventional osteosarcoma.³⁵⁷

Parosteal and periosteal osteosarcomas are juxtacortical or surface variants. Parosteal osteosarcomas are low-grade lesions accounting for up to 5% of all osteosarcomas.³⁵⁷ The most common site is the posterior distal femur. This variant tends to metastasize later than the conventional form. Transformation of low-grade parosteal osteosarcoma into high-grade sarcoma has been documented in 24% to 43% of cases.^{358,359} Periosteal osteosarcomas are intermediate-grade lesions most often involving the femur followed by the tibia.³⁵⁷ High-grade surface osteosarcomas are very rare accounting for 10% of all juxtacortical osteosarcomas.^{360,361}

Pain and swelling are the most frequent early symptoms. Pain is often intermittent in the beginning and a thorough workup sometimes is delayed because symptoms may be confused with growing pains. Osteosarcoma spreads hematogenously, with the lung being the most common metastatic site.

For treating extraskeletal osteosarcomas, please see the NCCN Guidelines for Soft Tissue Sarcoma.

Prognostic Factors

Tumor site and size, patient age, presence and location of metastases, histologic response to chemotherapy, and type of surgery and surgical margins are significant prognostic factors for patients with osteosarcoma of the extremities and trunk.³⁶²⁻³⁷⁰ In an analysis of 1702 patients with osteosarcoma of trunk or extremities treated in the COSS group protocols, patient age at diagnosis, tumor site, and primary metastases were identified as predictors of survival.³⁶⁴ In patients with extremity osteosarcomas, in addition to these variables, size and location within the limb at the time of diagnosis also had significant influence on outcome.³⁶⁴ All factors except age were significant in multivariate testing, with surgical remission and histologic response to chemotherapy emerging as the key prognostic factors. In a meta-analysis of data from prospective neoadjuvant chemotherapy trials in 4838 patients with osteosarcoma, female sex was associated with increased chemotherapy-induced tumor necrosis and greater OS, and children had better outcomes than adolescents and adults.³⁷¹ In a report of the combined analysis of three European Osteosarcoma Intergroup randomized controlled trials, Whelan and colleagues reported that good histologic response to preoperative chemotherapy, distal location (other than proximal humerus/femur), and female gender were associated with improved survival.³⁶⁷ However, high body mass index (BMI) in patients with osteosarcoma was associated with lower OS compared with patients with normal BMI.³⁷²

In patients with proven primary metastatic osteosarcoma, the number of metastases at diagnosis and the completeness of surgical resection of all clinically detected tumor sites are of independent prognostic value.²⁴ Patients with one or a few resectable pulmonary metastases have a survival rate that approaches that of patients with no metastatic disease.^{373,374}



Elevated serum ALP and LDH levels have also been identified as prognostic indicators in patients with osteosarcoma.^{363,365,366,375,376} In a cohort of 1421 patients with osteosarcoma of the extremity, Bacci and colleagues reported significantly higher serum LDH levels in patients with metastatic disease at presentation than in patients with localized disease (36.6% vs. 18.8%; $P < .0001$).³⁶⁵ The 5-year DFS correlated with serum LDH levels (39.5% for patients with high LDH levels and 60% for those with normal values). In another retrospective analysis of 789 patients with osteosarcoma of the extremity, it was reported that serum ALP level was a significant prognostic factor of EFS in patients with osteosarcoma of extremity; the 5-year EFS rate was 24% for patients with a serum ALP value of more than 4 times higher than the normal value and 46% for patients with high values below this limit ($P < .001$).³⁶⁶ However, in multivariate analysis, these markers did not retain their prognostic significance when compared to tumor volume, age, and histologic response to chemotherapy.^{363,365}

Workup

Osteosarcomas present both a local problem and a concern for distant metastasis. Initial workup should include imaging of the primary site (MRI with or without CT), chest imaging including chest CT, and head-to-toe PET/CT and/or bone scan. More detailed imaging (CT or MRI) of abnormalities identified on primary imaging is required for suspected metastatic disease.

Plain radiographs of osteosarcomas show cortical destruction and irregular reactive bone formation. Bone scan, while uniformly abnormal at the lesion, may be useful to identify additional synchronous lesions. MRI provides excellent soft tissue contrast and may be essential for operative planning. MRI is the best imaging modality to define the extent of the lesion within the bone as well as within the soft tissues, to detect “skip” metastases and to evaluate anatomic relationships with the surrounding

structures. In addition, ALP and LDH are frequently elevated in patients with osteosarcoma. Serum LDH was significantly higher in patients with metastatic disease at presentation than in patients with localized disease.³⁶⁵

Given that osteosarcoma is most common among children and AYAs, the effect of cancer and its treatment on fertility must be discussed with patients. Fertility preservation methods and alternatives should be discussed with patients as appropriate. The American Society of Reproductive Medicine (ASRM) recommends that conversations concerning fertility be undertaken by an interdisciplinary medical team comprised of oncologists, reproductive endocrinologists and urologists, and reproductive surgeons trained in fertility-preservation methods and that fertility preservation programs be affiliated with an experienced assisted reproductive technology (ART) program.^{377,378} For further details and recommendations, refer to the NCCN Guidelines for Adolescent and Young Adult (AYA) Oncology.

Finally, a number of genetic aberrations may underly osteosarcoma.³⁷⁹ For instance, it is reported that nearly 70% of patients with osteosarcoma may exhibit mutations in the tumor suppressor retinoblastoma gene, *Rb*.³⁷⁹ Genetic cancer syndromes that exhibit a predisposition for osteosarcoma include: Li-Fraumeni syndrome, hereditary retinoblastoma, Rothmund-Thomson syndrome type 2, Bloom syndrome, Werner syndrome, RAPADILINO syndrome, and Diamond Blackfan anemia. Thus, the NCCN Panel now recommends that genetic consultation and testing be considered for patients diagnosed with chondrosarcoma or osteosarcoma who possess a family or personal history of bone sarcomas.¹¹

**Treatment****Surgery**

Surgery (limb-sparing surgery or amputation) remains an essential part of management of patients with osteosarcoma.³⁸⁰ Studies that have compared limb-sparing surgery and amputation in patients with high-grade, non-metastatic osteosarcoma have not shown any significant difference in survival and local recurrence rates between these procedures.³⁸¹⁻³⁸³ However, limb-sparing surgery is associated with better functional outcomes.³⁸⁴ In patients with high-grade osteosarcomas with good histologic response to neoadjuvant chemotherapy, limb-sparing surgery is considered the preferred surgical modality if wide surgical margins can be achieved.^{381,385} Amputation is generally reserved for patients with tumors in unfavorable anatomical locations not amenable to limb-sparing surgery with adequate surgical margins.^{380,385}

Chemotherapy

The addition of adjuvant and neoadjuvant chemotherapy regimens to surgery has improved outcomes in patients with localized osteosarcoma. Early trials used chemotherapy regimens including at least three or more of the following drugs: doxorubicin, cisplatin, bleomycin, cyclophosphamide or ifosfamide, dactinomycin, and high-dose methotrexate.³⁸⁶⁻³⁹¹ Subsequent clinical trials have demonstrated that short, intensive chemotherapy regimens including cisplatin and doxorubicin with or without high-dose methotrexate and ifosfamide produce excellent long-term results, similar to those achieved with multiagent chemotherapy.³⁹²⁻³⁹⁹ Cisplatin/doxorubicin and high-dose methotrexate, cisplatin, and doxorubicin (MAP) are included as category 1 recommended regimens for first-line therapy.

In a randomized trial conducted by the European Osteosarcoma Group, the combination of doxorubicin and cisplatin was better tolerated compared to a multi-drug regimen with no difference in survival between

the groups in patients with operable, non-metastatic osteosarcoma.³⁹³ The 3-year and 5-year OS rates were 65% and 55%, respectively, in both groups. The 5-year PFS rate was 44% in both groups. In the INT-0133 study, which compared the 3-drug regimen (cisplatin, doxorubicin, and methotrexate) with the 4-drug regimen (cisplatin, doxorubicin, methotrexate, and ifosfamide) for the treatment of patients with non-metastatic resectable osteosarcoma, there was no difference in the 6-year EFS (63% and 64%, respectively) and OS (74% and 70%, respectively) between the two groups.³⁹⁹

Chemotherapy regimens without doxorubicin or cisplatin have also been evaluated in patients with localized osteosarcoma with the aim of minimizing long-term cardiotoxicity and ototoxicity.^{400,401} In a randomized multicenter trial (SFOP-OS94), the combination of ifosfamide and etoposide resulted in a higher histologic response rate than the regimen containing high-dose methotrexate and doxorubicin (56% and 39%, respectively). However, the 5-year OS was similar in both arms and there was no significant difference in 5-year EFS rates.⁴⁰¹

Good histopathologic response (greater than 90% necrosis) to neoadjuvant chemotherapy has been shown to be predictive of survival regardless of the type of chemotherapy administered after surgery.^{265,402,403} In an analysis of 881 patients with non-metastatic osteosarcoma of the extremities treated with neoadjuvant chemotherapy and surgery at the Rizzoli Institute, Bacci and colleagues showed that the 5-year DFS and OS correlated significantly with histologic response to chemotherapy.⁴⁰⁴ The 5-year DFS and OS in good and poor responders were 67.9% versus 51.3% ($P < .0001$) and 78.4% versus 63.7% ($P < .0001$), respectively. A report from the Children's Oncology Group also confirmed these findings; the 8-year postoperative EFS and OS rates were 81% and 87%, respectively, in good responders.⁴⁰² The corresponding survival rates were 46% and 52%, respectively, in poor responders.

**Localized Disease**

The guidelines recommend wide excision as the primary treatment for patients with low-grade (intramedullary and surface) osteosarcomas and periosteal lesions. Chemotherapy prior to wide excision could be considered for patients with periosteal lesions. If pathologic high-grade disease is discovered after wide excision, adjuvant chemotherapy is a category 2A recommendation. Although chemotherapy (neoadjuvant or adjuvant) has been used in the treatment of patients with periosteal osteosarcoma, there are no data to support that the addition of chemotherapy to wide excision improves outcome in patients with periosteal osteosarcoma.^{405,406} In a review of 119 patients with periosteal sarcoma published by the European Musculo-Skeletal Oncology Society, the use of neoadjuvant chemotherapy was not a prognostic factor, although it was used in the majority of the patients.⁴⁰⁶ Cesari and colleagues also reported similar findings; the 10-year OS rate was 86% and 83%, respectively, for patients who received adjuvant chemotherapy with surgery and for those who underwent surgery alone ($P = .73$).⁴⁰⁵ Long-term results (>25 years of follow-up) from patients with high-grade, localized osteosarcoma reveal significant benefits of adjuvant chemotherapy on DFS and OS.⁴⁰³

Preoperative chemotherapy prior to wide excision is preferred for those with high-grade osteosarcoma (category 1).^{373,392-394,397-401,407} Repeat imaging using pretreatment imaging modalities should be used to reassess the tumor for resectability. Selected elderly patients may benefit from immediate surgery.

Following wide excision, patients whose disease has a good histologic response (amount of viable tumor is less than 10% of the tumor area) should continue to receive several more cycles of the same chemotherapy. Surgical re-resection with or without RT can be considered for positive surgical margins. In a study of 119 patients with osteosarcoma

of the head and neck, combined modality treatment with surgery and RT (vs. surgery alone) improved local control and OS for patients with positive or uncertain surgical margins.⁴⁰⁸ Combined photon/proton or proton beam RT has been shown to be effective for local control in some patients with unresectable or incompletely resected osteosarcoma.^{409,410}

Patients whose disease has a poor response (viable tumor is $\geq 10\%$ of the tumor area) could be considered for chemotherapy with a different regimen (category 3). However, attempts to improve the outcome of poor responders by modifying the adjuvant chemotherapy remain unsuccessful.⁴¹¹⁻⁴¹⁵ Upon review of the evidence for the 2018 update, this recommendation was changed from category 2B to category 3. Recent data from the European and American Osteosarcoma Study (EURAMOS) Group trial^{412,416} informing this panel decision are discussed below.

An ongoing randomized phase III trial of the EURAMOS Group is evaluating treatment strategies for resectable osteosarcoma based on histologic response to preoperative chemotherapy. RT or adjuvant chemotherapy is recommended if the sarcoma remains unresectable following preoperative chemotherapy. The EURAMOS-1 trial included cohorts that received maintenance therapy with MAP (methotrexate/cisplatin/doxorubicin); MAP with IFN- α -2b therapy; or MAP with ifosfamide and etoposide (MAPIE). The addition of maintenance IFN- α -2b therapy to MAP in the adjuvant setting did not improve outcomes for “good responders” to preoperative chemotherapy.⁴¹⁶ However, the authors note that a significant portion of patients in the IFN arm did not receive the intended dose of IFN- α -2b due to failure to initiate therapy or premature termination of therapy. Additionally, adding ifosfamide and etoposide to MAP (ie, MAPIE) failed to improve outcomes for “poor responders” to preoperative chemotherapy.⁴¹²

Chemotherapy should include appropriate growth factor support. See the NCCN Guidelines for Hematopoietic Growth Factors for growth factor



support. See *Bone Cancer Systemic Therapy Agents* in the algorithm for a list of specific chemotherapy regimens.

Metastatic Disease at Presentation

Approximately 10% to 20% of patients present with metastatic disease at diagnosis.^{24,417} The number of metastases at diagnosis and complete surgical resection of all clinically detected tumor sites are of independent prognostic value in patients with primary metastatic disease at presentation.²⁴ Unilateral metastases and lower number of lung nodules were associated with improved outcomes with chemotherapy in patients with synchronous lung metastases.^{373,374} The 2-year DFS rate was significantly higher for patients with only one or two metastatic lesions than for patients with three or more lesions (78% and 28%, respectively).³⁷³

Although chemotherapy is associated with improved outcomes in patients with non-metastatic, high-grade, localized osteosarcoma, the results were significantly poorer in patients with metastatic disease at presentation.⁴¹⁷⁻⁴²⁰ In a study of 57 patients with metastatic disease at presentation treated with cisplatin, doxorubicin, and high dose of methotrexate and ifosfamide, the 2-year EFS and OS rates were 21% and 55%, respectively, compared to 75% and 94% in patients with non-metastatic disease at presentation, treated with the same chemotherapy protocol.⁴¹⁹ High-dose ifosfamide plus etoposide was examined in a phase II/III trial of 43 patients with newly diagnosed metastatic osteosarcoma, revealing an ORR of 59% ± 8%, but considerable toxicity.⁴²¹

Among patients with primary metastases treated in cooperative osteosarcoma trials, long-term survival rates were higher for patients whose metastases were excised following chemotherapy and surgery of the primary tumor compared to those patients whose metastases could not be removed (48% and 5%, respectively).⁴²² The combination of aggressive chemotherapy with simultaneous resection of primary and

metastatic lesions has also resulted in improved outcomes in patients with osteosarcoma of the extremity with lung metastases at presentation.⁴²³

For patients with resectable metastases (pulmonary, visceral, or skeletal) at presentation, the guidelines recommend preoperative chemotherapy followed by wide excision of the primary tumor. Chemotherapy and metastasectomy are included as options for the management of metastatic disease. In the case that pulmonary metastasectomy is not feasible, SBRT or ablation procedures may be considered. In a study conducted by UCLA, 16 patients (who had received either prior chemotherapy or surgery) with lung metastases from high-grade sarcomas were treated with SBRT.⁴²⁴ In total, 25 lesions were identified and treated with a median SBRT dose of 54 Gy (range 36–54 Gy) in 3 to 4 fractions.⁴²⁴ OS at 4 years was reported to be 78%.⁴²⁴ In another study, 30 patients with sarcoma with pulmonary metastases received SBRT at a median dose of 50 Gy in 4 to 5 fractions.⁴²⁵ Patients had received prior chemotherapy, surgery, or thoracic RT. Local control at 12 and 24 months was reported to be 94% and 86%, respectively, while OS was 76% and 43%.⁴²⁵ These reports suggest that SBRT may prove to be a promising alternative to surgery for oligometastatic disease. Unresectable metastatic disease should be managed with chemotherapy and/or RT followed by reassessment of the primary site for local control.

Surveillance

Once treatment is completed, surveillance should occur every 3 months for 2 years, then every 4 months for year 3, then every 6 months for years 4 and 5, and annually thereafter. Surveillance should include a complete physical, chest imaging, and imaging of the primary site as performed during initial disease workup. Head-to-toe PET/CT and/or bone scan (category 2B) may also be considered. Functional reassessment should be performed at every visit.

**Relapsed or Refractory Disease**

About 30% of patients with localized disease and 80% of the patients presenting with metastatic disease will relapse. The presence of solitary metastases, time to first relapse, and complete resectability of the disease at first recurrence have been reported to be the most important prognostic indicators for improved survival, whereas patients not amenable to surgery and those with a second or a third recurrence have a poor prognosis.⁴²⁶⁻⁴³¹ In patients with primary non-metastatic osteosarcoma, a longer relapse-free interval to pulmonary metastases was significantly associated with better survival.⁴²⁹ The prognostic significance of surgical clearance among patients with second and subsequent recurrences was also confirmed in a report of survival estimates derived from large cohorts of unselected patients treated at the COSS group trials.⁴³²

The combination of etoposide with cyclophosphamide or ifosfamide has been evaluated in clinical trials.⁴³³⁻⁴³⁵ In a phase II trial of the French Society of Pediatric Oncology, high-dose ifosfamide and etoposide resulted in a response rate of 48% in patients with relapsed or refractory osteosarcoma.⁴³⁴ In another phase II trial, cyclophosphamide and etoposide resulted in a 19% response rate and 35% rate of stable disease in patients with relapsed high-risk osteosarcoma.⁴³³ PFS at 4 months was 42%.

In a non-comparative, double-blind, placebo-controlled, phase II trial (REGOBONE), the efficacy and safety of regorafenib, a multikinase inhibitor, was evaluated among patients with progressive metastatic osteosarcoma (who underwent 1–2 previous lines of chemotherapy and had a performance status of ECOG 0-1).⁴³⁶ It was found that 65% of patients in the regorafenib arm exhibited non-progressive disease at 8 weeks compared to no patients in the placebo arm.⁴³⁶ In view of confirmed disease progression, 10 patients in the placebo arm were permitted to cross over to the regorafenib arm to receive treatment.⁴³⁶ The most

commonly noted adverse effects associated with regorafenib included hypertension and hand-foot skin reaction.⁴³⁶ It was concluded that regorafenib displayed antitumor activity in progressive metastatic osteosarcoma, delaying disease progression. Similarly, in another randomized, double-blind phase II study (SARC024), the activity of regorafenib was again evaluated in patients with progressive metastatic osteosarcoma.⁴³⁷ The study met its primary endpoint with a median PFS of 3.6 months in the regorafenib arm versus 1.7 months in the placebo arm (CI, 0.21–0.85; $P = .017$; hazard ratio [HR], 0.42).⁴³⁷ The NCCN Panel has included regorafenib under second-line therapy for osteosarcoma (relapsed, refractory, or metastatic disease) with a category 1 recommendation.

Similar to its activity in patients with advanced Ewing sarcoma, cabozantinib, as aforementioned, also exhibited activity in patients with advanced osteosarcoma. In the CABONE trial, the primary endpoint for patients with osteosarcoma included 6-month objective response as well as 6-month non-progression.²⁸⁵ Secondary endpoints included safety, best overall response, 1-year and 2-year PFS and OS, and metabolic response (evaluated by ¹⁸F-FDG PET-CT 28 days after the first dose).²⁸⁵ Similar to that of Ewing sarcoma, the primary endpoints for patients with osteosarcoma were reached as 12% of patients showed an objective response and 33% were progression-free at 6 months.²⁸⁵ Seventeen percent of patients exhibited partial response and 62% of patients showed stable disease as their best overall response.²⁸⁵ Of those with stable disease, 33% of individuals displayed tumor shrinkage.²⁸⁵ Cabozantinib has thus been included in the guideline as a second-line treatment option for patients with relapsed, refractory, or metastatic osteosarcoma.

Single-agent gemcitabine and combination regimens such as docetaxel and gemcitabine; cyclophosphamide and topotecan; or ifosfamide,



carboplatin, and etoposide have also been effective in the treatment of patients with relapsed or refractory bone sarcomas.^{276,286,438-440}

Samarium-153-ethylenediamine tetramethylene phosphonate (Sm-153-EDTMP) is a beta-particle-emitting, bone-seeking radiopharmaceutical, and has been evaluated in patients with locally recurrent or metastatic osteosarcoma or skeletal metastases.^{441,442} Andersen and colleagues have reported that Sm-153-EDTMP with peripheral blood progenitor cell support had low non-hematologic toxicity and provided pain palliation for patients with osteosarcoma local recurrences or osteoblastic bone metastases.⁴⁴¹ Results of a dose-finding study also demonstrated that Sm-153-EDTMP can be effective in the treatment of patients with high-risk osteosarcoma.⁴⁴²

Targeted inhibition of a variety of molecular pathways such as mTOR, SRC family of kinases, and vascular endothelial growth factor receptors (VEGFRs) are being evaluated in clinical trials to improve outcomes in patients with relapsed or refractory osteosarcoma. In a phase II trial of the Italian Sarcoma Group (n = 30), sorafenib (VEGFR inhibitor) demonstrated activity in patients with relapsed and unresectable high-grade osteosarcoma after failure of standard multimodal therapy.⁴⁴³ The PFS at 4 months (primary endpoint) was 46%. Median PFS and OS were 4 months and 7 months, respectively. The CBR (defined as no progression at 6 months) was 29%. Partial response and stable disease were seen in 8% and 34% of patients, respectively, and were durable for 6 months or more in 17% of patients.

To extend the duration of activity, a study examined sorafenib combined with everolimus for patients with unresectable or relapsed high-grade osteosarcoma (n = 38).⁴⁴⁴ Data suggested that this regimen is active in the second-line setting, but toxicity required dose reductions and/or treatment interruptions in 66% of patients. Therefore, under second-line options for patients with osteosarcoma, the NCCN Bone Panel has moved sorafenib

in combination with everolimus from preferred regimens to other recommended regimens (category 2B recommendation).

The safety and efficacy of HDT/HCT in patients with locally advanced, metastatic, or relapsed osteosarcoma have also been evaluated.^{445,446} In the Italian Sarcoma Group study, treatment with carboplatin and etoposide was followed by stem cell rescue, combined with surgery-induced complete response in chemosensitive disease.⁴⁴⁶ Transplant-related mortality was 3.1%. The 3-year OS and DFS rates were 20% and 12%, respectively. The efficacy of this approach in patients with high-risk disease is yet to be determined in prospective randomized studies.

The optimal treatment strategy for patients with relapsed or refractory disease has yet to be defined. If relapse occurs, the patient should receive second-line chemotherapy and/or surgical resection when feasible, followed by imaging to assess treatment response. See the *Bone Cancer Systemic Therapy Agents* in the algorithm for a complete list of second-line chemotherapy regimens. Surveillance is recommended for patients with disease that responds to second-line therapy.

Patients with disease progression or relapse after second-line therapy could be managed with resection, palliative RT (that may include Sm-153-EDTMP), or best supportive care. Participation in a clinical trial is strongly encouraged.

High-Grade Undifferentiated Pleomorphic Sarcoma of Bone

High-grade UPS of the bone most frequently arises in the appendicular skeleton and is associated with both a high rate of local recurrence and local nodal and distal metastases.⁴⁴⁷ The addition of chemotherapy to surgery has been shown to improve clinical outcomes in patients with non-metastatic malignant fibrous histiocytoma (MFH).⁴⁴⁸⁻⁴⁵⁰ In the European Osteosarcoma Intergroup study, adjuvant or neoadjuvant chemotherapy



with doxorubicin and cisplatin resulted in good pathologic response rates and survival (quite comparable with those for osteosarcoma) in patients with non-metastatic MFH.⁴⁵⁰ Median survival time was 63 months, and the 5-year PFS and OS rates were 56% and 59%, respectively. The guidelines recommend that patients with high-grade UPS of bone should be managed with regimens listed for osteosarcoma.

Immunotherapy for Bone Cancer

Immunotherapies harness the immune system to attack and destroy tumors. New cancer therapies are based on what we know about immune regulation and immune system checkpoints. The immune system is hardwired to regulate itself to maintain self-tolerance, ensuring that no unnecessary damage is done to harm the body after responding to a foreign antigen. For example, some immune cells upregulate cell surface molecules, such as the well-characterized cytotoxic T-lymphocyte–associated protein 4 (CTLA-4) and programmed cell death protein 1 pathway (PD-1/PD-L1), which serve as immune checkpoints that regulate the activation and function of T cells. The self-tolerance enabled by these molecules and other mechanisms is also employed by cancer cells to evade recognition by the immune system. Immune checkpoint blockade is used as cancer therapies reverse T-cell tolerance by blocking inhibitory interactions between tumor cells and infiltrating T cells, thus allowing an antitumor immune response.⁴⁵¹⁻⁴⁵³

Identifying patients whose disease will respond to checkpoint blockade has been difficult to assess, partly due to the difficulty in measuring dynamic immune-related molecules.⁴⁵⁴ Determining tumor mutational burden has helped predict responsiveness to checkpoint inhibitors.^{455,456} A high tumor mutation load was also associated with genetic alterations, such as microsatellite instability (MSI), that may lead to dysregulation in DNA repair mechanisms.⁴⁵⁷ A study analyzing genomes in over 100 tumor types found that a mutational hotspot in the promoter of a DNA mismatch

repair (MMR) gene is associated with high tumor mutational load.⁴⁵⁵ Cases of high mutation load have been identified in most cancer types and may identify patients who could benefit from immunotherapy.

A study pioneered in patients with advanced colorectal cancer with genomic instability and high tumor mutational burden found responsiveness to anti-PD-1 therapy correlated to MMR deficiency (dMMR).⁴⁵⁸ A prospective study to evaluate the efficacy of PD-1 blockade in 86 patients with 12 different advanced cancers with dMMR, including osteosarcoma, found that treatment with pembrolizumab resulted in durable responses (ORR in 53% of patients, with 21% complete response). While median PFS and OS were not reached, estimates of these outcomes at 1- and 2-year survival are 64% and 53% for PFS and 76% and 64% for OS.⁴⁵⁹ The FDA later granted accelerated approval to pembrolizumab, a PD-1–blocking antibody used as a systemic treatment option for adult and pediatric patients with unresectable or metastatic MSI-high (MSI-H) or dMMR solid tumors that have progressed following prior treatment and who have no satisfactory alternative treatment options.⁴⁶⁰

More recently, a multicohort, single-arm, open-label phase II study (KEYNOTE-158) evaluated the activity of pembrolizumab in patients with previously treated advanced solid tumors.⁴⁶¹ Patients were evaluated for tissue tumor mutational burden (tTMB) status by next-generation sequencing (NGS) and those with TMB-high status (defined as ≥ 10 mutations/megabase) exhibited clinical improvement with an ORR of 29% (95% CI, 21–39) compared to 6% (95% CI, 5–8) among the non-tTMB-high group.⁴⁶¹ The FDA has since approved pembrolizumab as a treatment option for patients with advanced solid tumors that are TMB-high and possess no alternative treatment options.⁴⁶²

NCCN recommends this treatment only for patients with MSI-H/dMMR or tTMB-high chondrosarcomas, chordomas, Ewing sarcomas, and



osteosarcomas. NCCN does not recommend this systemic treatment for GCTB since it is not technically a malignant tumor.

Summary

Primary bone cancers are extremely rare neoplasms. Osteosarcoma, chondrosarcoma, and Ewing sarcoma are the three most common forms of primary bone cancers. High-grade UPS, chordoma, and GCTB are very rare.

Chondrosarcoma is usually found in middle-aged and older adults. Wide excision is the preferred treatment for resectable low- and high-grade chondrosarcomas. Intralesional excision with or without surgical adjuvant is an alternative option for less radiographically aggressive, non-pelvic, low-grade chondrosarcomas. Proton and/or photon beam RT may be useful for patients with chondrosarcomas of the skull base and axial skeleton with tumors in unfavorable location not amenable to resection. Chemotherapy has little role in the management of patients with chondrosarcoma.

Chordomas arise from the embryonic remnants of the notochord and are more common in older adults. For patients with resectable conventional or chondroid chordomas, wide excision with or without RT is the primary treatment option for chordomas of the sacrum and mobile spine, whereas intralesional excision with or without RT is the treatment of choice for skull base tumors. Adjuvant RT can be considered for large extra-compartmental tumors or for positive surgical margins following resection. RT is the primary treatment option for patients with unresectable chordomas, irrespective of the location of the tumor. Systemic therapy (alone or in combination with surgery or RT) is recommended for patients with recurrent tumors. Dedifferentiated chordomas are usually managed as described in the NCCN Guidelines for Soft Tissue Sarcoma.

Ewing sarcoma develops mainly in children and young adults. *EWS-FLI1* fusion gene resulting from t(11;22) chromosomal translocation is the most common cytogenetic abnormality in the majority of patients. Multiagent chemotherapy is the primary treatment and patients with disease that responds to primary treatment are treated with local control therapy (wide excision, definitive RT with chemotherapy, or amputation in selected cases) followed by adjuvant chemotherapy. Adjuvant chemotherapy following wide excision or amputation is recommended for all patients regardless of surgical margins. Progressive disease is best managed with RT with or without surgery followed by chemotherapy or best supportive care.

GCTB is the most common benign bone tumor predominant in young adults. Intralesional excision with or without an effective adjuvant is an adequate primary treatment for resectable tumors. Denosumab, serial embolizations, IFN, and RT are included as primary treatment options for patients with lesions that are resectable with acceptable morbidity or unresectable axial lesions. The guidelines recommend continuation of denosumab until disease progression in responding disease.

Osteosarcoma occurs mainly in children and young adults. Wide excision is the primary treatment for patients with low-grade osteosarcomas, whereas preoperative chemotherapy followed by wide excision is the preferred option for patients with high-grade osteosarcoma. Chemotherapy prior to wide excision can be considered for patients with periosteal lesions. Following wide excision, postoperative chemotherapy is recommended for patients with low-grade or periosteal sarcomas with pathologic findings of high-grade disease and those with high-grade sarcoma. RT followed by adjuvant chemotherapy is recommended if the sarcoma remains unresectable after preoperative chemotherapy. Patients with relapsed or refractory disease should be treated with second-line therapy. Progressive disease is managed with surgery, palliative RT, or



National
Comprehensive
Cancer
Network®

NCCN Guidelines Version 1.2021 Bone Cancer

best supportive care. Preoperative chemotherapy followed by wide excision of the primary and metastatic tumors is recommended for patients with resectable metastases. Chemotherapy, metastasectomy, stereotactic RT, and ablation are included as options for the management of metastatic disease.

Consistent with the NCCN philosophy, the panel encourages patients to participate in well-designed clinical trials to enable further advances.



References

- SEER Cancer Statistics Fact Sheets: Bone and Joint Cancer. Bethesda, MD: National Cancer Institute; 2018. Available at: <http://seer.cancer.gov/statfacts/html/bones.html>. Accessed January 23, 2019.
- Siegel RL, Miller KD, Jemal A. Cancer statistics, 2020. *CA Cancer J Clin* 2020;70:7-30. Available at: <https://www.ncbi.nlm.nih.gov/pubmed/31912902>.
- Bone Cancer: Statistics 2020. Available at: <https://www.cancer.net/cancer-types/bone-cancer/statistics>. Accessed July 19, 2020.
- Fletcher CDM, Bridge JA, Hogendoorn P, Mertens F. WHO Classification of Tumours of Soft Tissue and Bone. Vol. 5 (ed 4). Lyon: IARC Press; 2013.
- McMaster ML, Goldstein AM, Bromley CM, et al. Chordoma: incidence and survival patterns in the United States, 1973-1995. *Cancer Causes Control* 2001;12:1-11. Available at: <http://www.ncbi.nlm.nih.gov/pubmed/11227920>.
- Walcott BP, Nahed BV, Mohyeldin A, et al. Chordoma: current concepts, management, and future directions. *Lancet Oncol* 2012;13:e69-e76. Available at: <http://www.ncbi.nlm.nih.gov/pubmed/22300861>.
- de Alava E, Gerald WL. Molecular biology of the Ewing's sarcoma/primitive neuroectodermal tumor family. *J Clin Oncol* 2000;18:204-213. Available at: <http://www.ncbi.nlm.nih.gov/pubmed/10623711>.
- Delattre O, Zucman J, Melot T, et al. The Ewing family of tumors--a subgroup of small-round-cell tumors defined by specific chimeric transcripts. *N Engl J Med* 1994;331:294-299. Available at: <http://www.ncbi.nlm.nih.gov/pubmed/8022439>.
- Denny CT. Gene rearrangements in Ewing's sarcoma. *Cancer Invest* 1996;14:83-88. Available at: <http://www.ncbi.nlm.nih.gov/pubmed/8597892>.
- Burchill SA. Molecular abnormalities in Ewing's sarcoma. *Expert Rev Anticancer Ther* 2008;8:1675-1687. Available at: <http://www.ncbi.nlm.nih.gov/pubmed/18925858>.
- Calvert GT, Randall RL, Jones KB, et al. At-risk populations for osteosarcoma: the syndromes and beyond. *Sarcoma* 2012;2012:152382. Available at: <http://www.ncbi.nlm.nih.gov/pubmed/22550413>.
- Martin JW, Squire JA, Zielenska M. The genetics of osteosarcoma. *Sarcoma* 2012;2012:627254. Available at: <http://www.ncbi.nlm.nih.gov/pubmed/22685381>.
- Malkin D, Li FP, Strong LC, et al. Germ line p53 mutations in a familial syndrome of breast cancer, sarcomas, and other neoplasms. *Science* 1990;250:1233-1238. Available at: <http://www.ncbi.nlm.nih.gov/pubmed/1978757>.
- McIntyre JF, Smith-Sorensen B, Friend SH, et al. Germline mutations of the p53 tumor suppressor gene in children with osteosarcoma. *J Clin Oncol* 1994;12:925-930. Available at: <http://www.ncbi.nlm.nih.gov/pubmed/8164043>.
- Ognjanovic S, Olivier M, Bergemann TL, Hainaut P. Sarcomas in TP53 germline mutation carriers: a review of the IARC TP53 database. *Cancer* 2012;118:1387-1396. Available at: <http://www.ncbi.nlm.nih.gov/pubmed/21837677>.
- Ottaviani G, Jaffe N. The etiology of osteosarcoma. *Cancer Treat Res* 2009;152:15-32. Available at: <http://www.ncbi.nlm.nih.gov/pubmed/20213384>.
- MacCarthy A, Bayne AM, Draper GJ, et al. Non-ocular tumours following retinoblastoma in Great Britain 1951 to 2004. *Br J Ophthalmol* 2009;93:1159-1162. Available at: <http://www.ncbi.nlm.nih.gov/pubmed/19704040>.



18. Kalra S, Grimer RJ, Spooner D, et al. Radiation-induced sarcomas of bone: factors that affect outcome. *J Bone Joint Surg Br* 2007;89:808-813. Available at: <http://www.ncbi.nlm.nih.gov/pubmed/17613509>.

19. Mavrogenis AF, Pala E, Guerra G, Ruggieri P. Post-radiation sarcomas. Clinical outcome of 52 Patients. *J Surg Oncol* 2012;105:570-576. Available at: <http://www.ncbi.nlm.nih.gov/pubmed/22012601>.

20. Bernstein M, Kovar H, Paulussen M, et al. Ewing's sarcoma family of tumors: current management. *Oncologist* 2006;11:503-519. Available at: <http://www.ncbi.nlm.nih.gov/pubmed/16720851>.

21. Subbiah V, Anderson P, Lazar AJ, et al. Ewing's sarcoma: standard and experimental treatment options. *Curr Treat Options Oncol* 2009;10:126-140. Available at: <http://www.ncbi.nlm.nih.gov/pubmed/19533369>.

22. Federman N, Bernthal N, Eilber FC, Tap WD. The multidisciplinary management of osteosarcoma. *Curr Treat Options Oncol* 2009;10:82-93. Available at: <http://www.ncbi.nlm.nih.gov/pubmed/19238553>.

23. Cotterill SJ, Ahrens S, Paulussen M, et al. Prognostic factors in Ewing's tumor of bone: analysis of 975 patients from the European Intergroup Cooperative Ewing's Sarcoma Study Group. *J Clin Oncol* 2000;18:3108-3114. Available at: <http://www.ncbi.nlm.nih.gov/pubmed/10963639>.

24. Kager L, Zoubek A, Potechger U, et al. Primary metastatic osteosarcoma: presentation and outcome of patients treated on neoadjuvant Cooperative Osteosarcoma Study Group protocols. *J Clin Oncol* 2003;21:2011-2018. Available at: <http://www.ncbi.nlm.nih.gov/pubmed/12743156>.

25. Amin MB, Edge SB, Greene FL, et al. *AJCC Cancer Staging Manual*, 8th edition. New York: Springer; 2017.

26. Lee SJ, Schover LR, Partridge AH, et al. American Society of Clinical Oncology recommendations on fertility preservation in cancer patients. *J*

Clin Oncol 2006;24:2917-2931. Available at: <http://www.ncbi.nlm.nih.gov/pubmed/16651642>.

27. Rougraff BT, Kneisl JS, Simon MA. Skeletal metastases of unknown origin. A prospective study of a diagnostic strategy. *J Bone Joint Surg Am* 1993;75:1276-1281. Available at: <http://www.ncbi.nlm.nih.gov/pubmed/8408149>.

28. Heck RK, Peabody TD, Simon MA. Staging of primary malignancies of bone. *CA Cancer J Clin* 2006;56:366-375. Available at: <http://www.ncbi.nlm.nih.gov/pubmed/17135693>.

29. Kumar J, Seith A, Kumar A, et al. Whole-body MR imaging with the use of parallel imaging for detection of skeletal metastases in pediatric patients with small-cell neoplasms: comparison with skeletal scintigraphy and FDG PET/CT. *Pediatr Radiol* 2008;38:953-962. Available at: <http://www.ncbi.nlm.nih.gov/pubmed/18636251>.

30. Daldrup-Link HE, Franzius C, Link TM, et al. Whole-body MR imaging for detection of bone metastases in children and young adults: comparison with skeletal scintigraphy and FDG PET. *AJR Am J Roentgenol* 2001;177:229-236. Available at: <http://www.ncbi.nlm.nih.gov/pubmed/11418435>.

31. Schuetze SM. Utility of positron emission tomography in sarcomas. *Curr Opin Oncol* 2006;18:369-373. Available at: <http://www.ncbi.nlm.nih.gov/pubmed/16721133>.

32. Volker T, Denecke T, Steffen I, et al. Positron emission tomography for staging of pediatric sarcoma patients: results of a prospective multicenter trial. *J Clin Oncol* 2007;25:5435-5441. Available at: <http://www.ncbi.nlm.nih.gov/pubmed/18048826>.

33. Hawkins DS, Rajendran JG, Conrad EU, et al. Evaluation of chemotherapy response in pediatric bone sarcomas by [F-18]-fluorodeoxy-D-glucose positron emission tomography. *Cancer* 2002;94:3277-3284. Available at: <http://www.ncbi.nlm.nih.gov/pubmed/12115361>.



34. Hawkins DS, Schuetze SM, Butrynski JE, et al. [18F]Fluorodeoxyglucose positron emission tomography predicts outcome for Ewing sarcoma family of tumors. *J Clin Oncol* 2005;23:8828-8834. Available at: <http://www.ncbi.nlm.nih.gov/pubmed/16314643>.

35. Hawkins DS, Conrad EU, 3rd, Butrynski JE, et al. [F-18]-fluorodeoxy-D-glucose-positron emission tomography response is associated with outcome for extremity osteosarcoma in children and young adults. *Cancer* 2009;115:3519-3525. Available at: <http://www.ncbi.nlm.nih.gov/pubmed/19517457>.

36. Stacchiotti S, Longhi A, Ferraresi V, et al. Phase II study of imatinib in advanced chordoma. *J Clin Oncol* 2012;30:914-920. Available at: <http://www.ncbi.nlm.nih.gov/pubmed/22331945>.

37. Mammari H, Kerrou K, Nataf V, et al. Positron emission tomography/computed tomography imaging of residual skull base chordoma before radiotherapy using fluoromisonidazole and fluorodeoxyglucose: potential consequences for dose painting. *Int J Radiat Oncol Biol Phys* 2012;84:681-687. Available at: <http://www.ncbi.nlm.nih.gov/pubmed/22391104>.

38. Liu PT, Valadez SD, Chivers FS, et al. Anatomically based guidelines for core needle biopsy of bone tumors: implications for limb-sparing surgery. *Radiographics* 2007;27:189-205; discussion 206. Available at: <http://www.ncbi.nlm.nih.gov/pubmed/17235007>.

39. Huang AJ, Kattapuram SV. Musculoskeletal neoplasms: biopsy and intervention. *Radiol Clin North Am* 2011;49:1287-1305. Available at: <http://www.ncbi.nlm.nih.gov/pubmed/22024299>.

40. Ashford RU, McCarthy SW, Scolyer RA, et al. Surgical biopsy with intra-operative frozen section. An accurate and cost-effective method for diagnosis of musculoskeletal sarcomas. *J Bone Joint Surg Br* 2006;88:1207-1211. Available at: <http://www.ncbi.nlm.nih.gov/pubmed/16943474>.

41. Skrzynski MC, Biermann JS, Montag A, Simon MA. Diagnostic accuracy and charge-savings of outpatient core needle biopsy compared

with open biopsy of musculoskeletal tumors. *J Bone Joint Surg Am* 1996;78:644-649. Available at: <http://www.ncbi.nlm.nih.gov/pubmed/8642019>

42. Welker JA, Henshaw RM, Jelinek J, et al. The percutaneous needle biopsy is safe and recommended in the diagnosis of musculoskeletal masses. *Cancer* 2000;89:2677-2686. Available at: <http://www.ncbi.nlm.nih.gov/pubmed/11135231>

43. Mitsuyoshi G, Naito N, Kawai A, et al. Accurate diagnosis of musculoskeletal lesions by core needle biopsy. *J Surg Oncol* 2006;94:21-27. Available at: <http://www.ncbi.nlm.nih.gov/pubmed/16788939>.

44. Adams SC, Potter BK, Pitcher DJ, Temple HT. Office-based core needle biopsy of bone and soft tissue malignancies: an accurate alternative to open biopsy with infrequent complications. *Clin Orthop Relat Res* 2010;468:2774-2780. Available at: <http://www.ncbi.nlm.nih.gov/pubmed/20582496>.

45. Gogna A, Peh WC, Munk PL. Image-guided musculoskeletal biopsy. *Radiol Clin North Am* 2008;46:455-473, v. Available at: <http://www.ncbi.nlm.nih.gov/pubmed/18707957>.

46. Mankin HJ, Mankin CJ, Simon MA. The hazards of the biopsy, revisited. Members of the Musculoskeletal Tumor Society. *J Bone Joint Surg Am* 1996;78:656-663. Available at: <http://www.ncbi.nlm.nih.gov/pubmed/8642021>.

47. Davies NM, Livesley PJ, Cannon SR. Recurrence of an osteosarcoma in a needle biopsy track. *J Bone Joint Surg Br* 1993;75:977-978. Available at: <http://www.ncbi.nlm.nih.gov/pubmed/8245097>.

48. Saghieh S, Masrouha KZ, Musallam KM, et al. The risk of local recurrence along the core-needle biopsy tract in patients with bone sarcomas. *Iowa Orthop J* 2010;30:80-83. Available at: <http://www.ncbi.nlm.nih.gov/pubmed/21045976>.

49. Yang YJ, Damron TA. Comparison of needle core biopsy and fine-needle aspiration for diagnostic accuracy in musculoskeletal lesions. *Arch*



Pathol Lab Med 2004;128:759-764. Available at:
<http://www.ncbi.nlm.nih.gov/pubmed/15214827>.

50. Patel S, DeLaney TF. Advanced-technology radiation therapy for bone sarcomas. *Cancer Control* 2008;15:21-37. Available at:
<http://www.ncbi.nlm.nih.gov/pubmed/18094658>.

51. McGovern SL, Mahajan A. Progress in radiotherapy for pediatric sarcomas. *Curr Oncol Rep* 2012;14:320-326. Available at:
<http://www.ncbi.nlm.nih.gov/pubmed/22532264>.

52. Gelderblom H, Hogendoorn PCW, Dijkstra SD, et al. The clinical approach towards chondrosarcoma. *Oncologist* 2008;13:320-329. Available at:
<http://www.ncbi.nlm.nih.gov/pubmed/18378543>.

53. Riedel RF, Larrier N, Dodd L, et al. The clinical management of chondrosarcoma. *Curr Treat Options Oncol* 2009;10:94-106. Available at:
<http://www.ncbi.nlm.nih.gov/pubmed/19238552>.

54. Mankin HJ, Cantley KP, Schiller AL, Lippiello L. The biology of human chondrosarcoma. II. Variation in chemical composition among types and subtypes of benign and malignant cartilage tumors. *J Bone Joint Surg Am* 1980;62:176-188. Available at:
<http://www.ncbi.nlm.nih.gov/pubmed/7358749>.

55. Nicolle R, Ayadi M, Gomez-Brouchet A, et al. Integrated molecular characterization of chondrosarcoma reveals critical determinants of disease progression. *Nat Commun* 2019;10:4622. Available at:
<https://www.ncbi.nlm.nih.gov/pubmed/31604924>.

56. Chow W, Frankel P, Ruel C, et al. Results of a prospective phase 2 study of pazopanib in patients with surgically unresectable or metastatic chondrosarcoma. *Cancer* 2020;126:105-111. Available at:
<https://www.ncbi.nlm.nih.gov/pubmed/31509242>.

57. Verdegaal SH, Bovee JV, Pansuriya TC, et al. Incidence, predictive factors, and prognosis of chondrosarcoma in patients with Ollier disease and Maffucci syndrome: an international multicenter study of 161 patients.

Oncologist 2011;16:1771-1779. Available at:
<http://www.ncbi.nlm.nih.gov/pubmed/22147000>.

58. Ahmed AR, Tan T-S, Unni KK, et al. Secondary chondrosarcoma in osteochondroma: report of 107 patients. *Clin Orthop Relat Res* 2003;193-206. Available at:
<http://www.ncbi.nlm.nih.gov/pubmed/12782876>.

59. Amary MF, Damato S, Halai D, et al. Ollier disease and Maffucci syndrome are caused by somatic mosaic mutations of IDH1 and IDH2. *Nat Genet* 2011;43:1262-1265. Available at:
<http://www.ncbi.nlm.nih.gov/pubmed/22057236>.

60. Pansuriya TC, van Eijk R, d'Adamo P, et al. Somatic mosaic IDH1 and IDH2 mutations are associated with enchondroma and spindle cell hemangioma in Ollier disease and Maffucci syndrome. *Nat Genet* 2011;43:1256-1261. Available at:
<http://www.ncbi.nlm.nih.gov/pubmed/22057234>.

61. Amary MF, Bacsi K, Maggiani F, et al. IDH1 and IDH2 mutations are frequent events in central chondrosarcoma and central and periosteal chondromas but not in other mesenchymal tumours. *J Pathol* 2011;224:334-343. Available at:
<http://www.ncbi.nlm.nih.gov/pubmed/21598255>.

62. Meijer D, de Jong D, Pansuriya TC, et al. Genetic characterization of mesenchymal, clear cell, and dedifferentiated chondrosarcoma. *Genes Chromosomes Cancer* 2012;51:899-909. Available at:
<http://www.ncbi.nlm.nih.gov/pubmed/22674453>.

63. Amer KM, Munn M, Congiusta D, et al. Survival and Prognosis of Chondrosarcoma Subtypes: SEER Database Analysis. *J Orthop Res* 2020;38:311-319. Available at:
<https://www.ncbi.nlm.nih.gov/pubmed/31498474>.

64. Kilpatrick SE, Inwards CY, Fletcher CD, et al. Myxoid chondrosarcoma (chordoid sarcoma) of bone: a report of two cases and review of the literature. *Cancer* 1997;79:1903-1910. Available at:
<http://www.ncbi.nlm.nih.gov/pubmed/9149016>.



65. Antonescu CR, Argani P, Erlandson RA, et al. Skeletal and extraskeletal myxoid chondrosarcoma: a comparative clinicopathologic, ultrastructural, and molecular study. *Cancer* 1998;83:1504-1521. Available at: <http://www.ncbi.nlm.nih.gov/pubmed/9781944>.
66. Schneiderman BA, Kliethermes SA, Nystrom LM. Survival in Mesenchymal Chondrosarcoma Varies Based on Age and Tumor Location: A Survival Analysis of the SEER Database. *Clin Orthop Relat Res* 2017;475:799-805. Available at: <https://www.ncbi.nlm.nih.gov/pubmed/26975384>.
67. Hirabayashi Y, Ishida T, Yoshida MA, et al. Translocation (9;22)(q22;q12). A recurrent chromosome abnormality in extraskeletal myxoid chondrosarcoma. *Cancer Genet Cytogenet* 1995;81:33-37. Available at: <http://www.ncbi.nlm.nih.gov/pubmed/7773957>.
68. Panagopoulos I, Mertens F, Isaksson M, et al. Molecular genetic characterization of the EWS/CHN and RBP56/CHN fusion genes in extraskeletal myxoid chondrosarcoma. *Genes Chromosomes Cancer* 2002;35:340-352. Available at: <http://www.ncbi.nlm.nih.gov/pubmed/12378528>.
69. Nishio J, Iwasaki H, Nabeshima K, Naito M. Cytogenetics and molecular genetics of myxoid soft-tissue sarcomas. *Genet Res Int* 2011;2011:497148. Available at: <http://www.ncbi.nlm.nih.gov/pubmed/22567356>.
70. Paioli A, Gronchi A, Palmerini E, et al. Extraskeletal myxoid chondrosarcoma: A retrospective analysis of 69 patients with localized disease and molecularly confirmed diagnosis [abstract]. *ASCO Meeting Abstracts* 2014;32:10589. Available at: http://ascopubs.org/doi/abs/10.1200/jco.2014.32.15_suppl.10589.
71. Bruns J, Elbracht M, Niggemeyer O. Chondrosarcoma of bone: an oncological and functional follow-up study. *Ann Oncol* 2001;12:859-864. Available at: <http://www.ncbi.nlm.nih.gov/pubmed/11484965>.
72. Bergh P, Gunterberg B, Meis-Kindblom JM, Kindblom LG. Prognostic factors and outcome of pelvic, sacral, and spinal chondrosarcomas: a center-based study of 69 cases. *Cancer* 2001;91:1201-1212. Available at: <http://www.ncbi.nlm.nih.gov/pubmed/11283918>.
73. Enneking WF, Dunham WK. Resection and reconstruction for primary neoplasms involving the innominate bone. *J Bone Joint Surg Am* 1978;60:731-746. Available at: <http://www.ncbi.nlm.nih.gov/pubmed/701308>.
74. Norman A, Sissons HA. Radiographic hallmarks of peripheral chondrosarcoma. *Radiology* 1984;151:589-596. Available at: <http://www.ncbi.nlm.nih.gov/pubmed/6718712>.
75. Sanerkin NG. The diagnosis and grading of chondrosarcoma of bone: a combined cytologic and histologic approach. *Cancer* 1980;45:582-594. Available at: <http://www.ncbi.nlm.nih.gov/pubmed/6928110>.
76. Lee FY, Mankin HJ, Fondren G, et al. Chondrosarcoma of bone: an assessment of outcome. *J Bone Joint Surg Am* 1999;81:326-338. Available at: <http://www.ncbi.nlm.nih.gov/pubmed/10199270>.
77. Fiorenza F, Abudu A, Grimer RJ, et al. Risk factors for survival and local control in chondrosarcoma of bone. *J Bone Joint Surg Br* 2002;84:93-99. Available at: <http://www.ncbi.nlm.nih.gov/pubmed/11837841>.
78. Fayad LM, Ahlawat S, Khan MS, McCarthy E. Chondrosarcomas of the hands and feet: A case series and systematic review of the literature. *Eur J Radiol* 2015;84:2004-2012. Available at: <https://www.ncbi.nlm.nih.gov/pubmed/26189572>.
79. Nota SP, Braun Y, Schwab JH, et al. The identification of prognostic factors and survival statistics of conventional central chondrosarcoma. *Sarcoma* 2015;2015:623746. Available at: <https://www.ncbi.nlm.nih.gov/pubmed/26633939>.
80. Giuffrida AY, Burgueno JE, Koniaris LG, et al. Chondrosarcoma in the United States (1973 to 2003): an analysis of 2890 cases from the SEER database. *J Bone Joint Surg Am* 2009;91:1063-1072. Available at: <http://www.ncbi.nlm.nih.gov/pubmed/19411454>.



81. Andreou D, Gilg MM, Gosheger G, et al. Metastatic Potential of Grade I Chondrosarcoma of Bone: Results of a Multi-institutional Study. *Ann Surg Oncol* 2016;23:120-125. Available at: <https://www.ncbi.nlm.nih.gov/pubmed/26350369>.
82. Sheth DS, Yasko AW, Johnson ME, et al. Chondrosarcoma of the pelvis. Prognostic factors for 67 patients treated with definitive surgery. *Cancer* 1996;78:745-750. Available at: <http://www.ncbi.nlm.nih.gov/pubmed/8756367>.
83. Pring ME, Weber KL, Unni KK, Sim FH. Chondrosarcoma of the pelvis. A review of sixty-four cases. *J Bone Joint Surg Am* 2001;83-A:1630-1642. Available at: <http://www.ncbi.nlm.nih.gov/pubmed/11701784>.
84. Funovics PT, Panotopoulos J, Sabeti-Aschraf M, et al. Low-grade chondrosarcoma of bone: experiences from the Vienna Bone and Soft Tissue Tumour Registry. *Int Orthop* 2011;35:1049-1056. Available at: <http://www.ncbi.nlm.nih.gov/pubmed/20803012>.
85. Andreou D, Ruppin S, Fehlberg S, et al. Survival and prognostic factors in chondrosarcoma. *Acta Orthop* 2011;82:749-755. Available at: <http://www.ncbi.nlm.nih.gov/pubmed/22066552>.
86. Veth R, Schreuder B, van Beem H, et al. Cryosurgery in aggressive, benign, and low-grade malignant bone tumours. *Lancet Oncol* 2005;6:25-34. Available at: <http://www.ncbi.nlm.nih.gov/pubmed/15629273>.
87. Ahlmann ER, Menendez LR, Fedenko AN, Learch T. Influence of cryosurgery on treatment outcome of low-grade chondrosarcoma. *Clin Orthop Relat Res* 2006;451:201-207. Available at: <http://www.ncbi.nlm.nih.gov/pubmed/16788412>.
88. Mohler DG, Chiu R, McCall DA, Avedian RS. Curettage and cryosurgery for low-grade cartilage tumors is associated with low recurrence and high function. *Clin Orthop Relat Res* 2010;468:2765-2773. Available at: <http://www.ncbi.nlm.nih.gov/pubmed/20574801>.
89. Leerapun T, Hugate RR, Inwards CY, et al. Surgical management of conventional grade I chondrosarcoma of long bones. *Clin Orthop Relat Res* 2007;463:166-172. Available at: <http://www.ncbi.nlm.nih.gov/pubmed/17632422>.
90. Donati D, Colangeli S, Colangeli M, et al. Surgical treatment of grade I central chondrosarcoma. *Clin Orthop Relat Res* 2010;468:581-589. Available at: <http://www.ncbi.nlm.nih.gov/pubmed/19727994>.
91. Hickey M, Farrokhyar F, Deheshi B, et al. A systematic review and meta-analysis of intralesional versus wide resection for intramedullary grade I chondrosarcoma of the extremities. *Ann Surg Oncol* 2011;18:1705-1709. Available at: <http://www.ncbi.nlm.nih.gov/pubmed/21258968>.
92. Chen X, Yu LJ, Peng HM, et al. Is intralesional resection suitable for central grade 1 chondrosarcoma: A systematic review and updated meta-analysis. *Eur J Surg Oncol* 2017;43:1718-1726. Available at: <https://www.ncbi.nlm.nih.gov/pubmed/28666625>.
93. Gonzalez Del Pino J, Lozano Calderon SA, Chebib I, Jupiter JB. Intralesional Versus Wide Resection of Low-Grade Chondrosarcomas of the Hand. *J Hand Surg Am* 2016;41:541-549 e545. Available at: <https://www.ncbi.nlm.nih.gov/pubmed/26803570>.
94. Dierselhuis EF, Goulding KA, Stevens M, Jutte PC. Intralesional treatment versus wide resection for central low-grade chondrosarcoma of the long bones. *Cochrane Database Syst Rev* 2019;3:CD010778. Available at: <https://www.ncbi.nlm.nih.gov/pubmed/30845364>.
95. Goda JS, Ferguson PC, O'Sullivan B, et al. High-risk extracranial chondrosarcoma. *Cancer* 2011;117:2513-2519. Available at: <http://www.ncbi.nlm.nih.gov/pubmed/21246520>.
96. Indelicato DJ, Rotondo RL, Begosh-Mayne D, et al. A Prospective Outcomes Study of Proton Therapy for Chordomas and Chondrosarcomas of the Spine. *Int J Radiat Oncol Biol Phys* 2016;95:297-303. Available at: <https://www.ncbi.nlm.nih.gov/pubmed/27084648>.
97. Hug EB, Loreda LN, Slater JD, et al. Proton radiation therapy for chordomas and chondrosarcomas of the skull base. *J Neurosurg*



1999;91:432-439. Available at:

<http://www.ncbi.nlm.nih.gov/pubmed/10470818>.

98. Munzenrider JE, Liebsch NJ. Proton therapy for tumors of the skull base. *Strahlenther Onkol* 1999;175 Suppl 2:57-63. Available at:

<http://www.ncbi.nlm.nih.gov/pubmed/10394399>.

99. Noel G, Habrand JL, Mammar H, et al. Combination of photon and proton radiation therapy for chordomas and chondrosarcomas of the skull base: the Centre de Protontherapie D'Orsay experience. *Int J Radiat Oncol Biol Phys* 2001;51:392-398. Available at:

<http://www.ncbi.nlm.nih.gov/pubmed/11567813>.

100. Noel G, Feuvret L, Ferrand R, et al. Radiotherapeutic factors in the management of cervical-basal chordomas and chondrosarcomas.

Neurosurgery 2004;55:1252-1260. Available at:

<http://www.ncbi.nlm.nih.gov/pubmed/15574207>.

101. Ares C, Hug EB, Lomax AJ, et al. Effectiveness and safety of spot scanning proton radiation therapy for chordomas and chondrosarcomas of the skull base: first long-term report. *Int J Radiat Oncol Biol Phys* 2009;75:1111-1118. Available at:

<http://www.ncbi.nlm.nih.gov/pubmed/19386442>.

102. Amichetti M, Amelio D, Cianchetti M, et al. A systematic review of proton therapy in the treatment of chondrosarcoma of the skull base.

Neurosurg Rev 2010;33:155-165. Available at:

<http://www.ncbi.nlm.nih.gov/pubmed/19921291>.

103. DeLaney TF, Liebsch NJ, Pedlow FX, et al. Long-term results of Phase II study of high dose photon/proton radiotherapy in the management of spine chordomas, chondrosarcomas, and other sarcomas. *J Surg Oncol* 2014;110:115-122. Available at:

<http://www.ncbi.nlm.nih.gov/pubmed/24752878>.

104. Sahgal A, Chan MW, Atenafu EG, et al. Image-guided, intensity-modulated radiation therapy (IG-IMRT) for skull base chordoma and chondrosarcoma: preliminary outcomes. *Neuro Oncol* 2015;17:889-894.

Available at: <https://www.ncbi.nlm.nih.gov/pubmed/25543126>.

105. Schulz-Ertner D, Nikoghosyan A, Thilmann C, et al. Results of carbon ion radiotherapy in 152 patients. *Int J Radiat Oncol Biol Phys* 2004;58:631-640. Available at:

<http://www.ncbi.nlm.nih.gov/pubmed/14751537>.

106. Schulz-Ertner D, Nikoghosyan A, Hof H, et al. Carbon ion radiotherapy of skull base chondrosarcomas. *Int J Radiat Oncol Biol Phys* 2007;67:171-177. Available at:

<http://www.ncbi.nlm.nih.gov/pubmed/17056193>.

107. Imai R, Kamada T, Araki N, et al. Clinical Efficacy of Carbon Ion Radiotherapy for Unresectable Chondrosarcomas. *Anticancer Res* 2017;37:6959-6964. Available at:

<https://www.ncbi.nlm.nih.gov/pubmed/29187480>.

108. Kano H, Sheehan J, Sneed PK, et al. Skull base chondrosarcoma radiosurgery: report of the North American Gamma Knife Consortium. *J Neurosurg* 2015;123:1268-1275. Available at:

<https://www.ncbi.nlm.nih.gov/pubmed/26115468>.

109. Mitchell AD, Ayoub K, Mangham DC, et al. Experience in the treatment of dedifferentiated chondrosarcoma. *J Bone Joint Surg Br* 2000;82:55-61. Available at:

<http://www.ncbi.nlm.nih.gov/pubmed/10697315>.

110. Dickey ID, Rose PS, Fuchs B, et al. Dedifferentiated chondrosarcoma: the role of chemotherapy with updated outcomes. *J Bone Joint Surg Am* 2004;86-A:2412-2418. Available at:

<http://www.ncbi.nlm.nih.gov/pubmed/15523011>.

111. Grimer RJ, Gosheger G, Taminiau A, et al. Dedifferentiated chondrosarcoma: prognostic factors and outcome from a European group. *Eur J Cancer* 2007;43:2060-2065. Available at:

<http://www.ncbi.nlm.nih.gov/pubmed/17720491>.

112. Staals EL, Bacchini P, Bertoni F. Dedifferentiated central chondrosarcoma. *Cancer* 2006;106:2682-2691. Available at:

<http://www.ncbi.nlm.nih.gov/pubmed/16691621>.



113. Frezza AM, Cesari M, Baumhoer D, et al. Mesenchymal chondrosarcoma: prognostic factors and outcome in 113 patients. A European Musculoskeletal Oncology Society study. *Eur J Cancer* 2015;51:374-381. Available at: <http://www.ncbi.nlm.nih.gov/pubmed/25529371>.

114. Dantonello TM, Int-Veen C, Leuschner I, et al. Mesenchymal chondrosarcoma of soft tissues and bone in children, adolescents, and young adults: experiences of the CWS and COSS study groups. *Cancer* 2008;112:2424-2431. Available at: <http://www.ncbi.nlm.nih.gov/pubmed/18438777>.

115. Schuetze SM, Bolejack V, Choy E, et al. Phase 2 study of dasatinib in patients with alveolar soft part sarcoma, chondrosarcoma, chordoma, epithelioid sarcoma, or solitary fibrous tumor. *Cancer* 2017;123:90-97. Available at: <https://www.ncbi.nlm.nih.gov/pubmed/27696380>.

116. Villalobos VM, Hoffner B, Elias AD. We can study ultrarare tumors effectively in this day and age, it just takes a cooperative approach: The role of dasatinib in assorted indolent sarcomas. *Cancer* 2017;123:20-24. Available at: <https://www.ncbi.nlm.nih.gov/pubmed/27696384>.

117. Tap WD, Villalobos VM, Cote GM, et al. Phase I Study of the Mutant IDH1 Inhibitor Ivosidenib: Safety and Clinical Activity in Patients With Advanced Chondrosarcoma. *J Clin Oncol* 2020;38:1693-1701. Available at: <https://www.ncbi.nlm.nih.gov/pubmed/32208957>.

118. Uhl M, Welzel T, Oelmann J, et al. Active raster scanning with carbon ions: reirradiation in patients with recurrent skull base chordomas and chondrosarcomas. *Strahlenther Onkol* 2014;190:686-691. Available at: <http://www.ncbi.nlm.nih.gov/pubmed/24663287>.

119. Chugh R, Tawbi H, Lucas DR, et al. Chordoma: the nonsarcoma primary bone tumor. *Oncologist* 2007;12:1344-1350. Available at: <http://www.ncbi.nlm.nih.gov/pubmed/18055855>.

120. Shih AR, Cote GM, Chebib I, et al. Clinicopathologic characteristics of poorly differentiated chordoma. *Mod Pathol* 2018;31:1237-1245. Available at: <https://www.ncbi.nlm.nih.gov/pubmed/29483606>.

121. Rachinger W, Eigenbrod S, Dutzmann S, et al. Male sex as a risk factor for the clinical course of skull base chordomas. *J Neurosurg* 2014;120:1313-1320. Available at: <http://www.ncbi.nlm.nih.gov/pubmed/24405075>.

122. Yamaguchi T, Suzuki S, Ishiwa H, Ueda Y. Intraosseous benign notochordal cell tumours: overlooked precursors of classic chordomas? *Histopathology* 2004;44:597-602. Available at: <http://www.ncbi.nlm.nih.gov/pubmed/15186275>.

123. Deshpande V, Nielsen GP, Rosenthal DI, Rosenberg AE. Intraosseous benign notochord cell tumors (BNCT): further evidence supporting a relationship to chordoma. *Am J Surg Pathol* 2007;31:1573-1577. Available at: <http://www.ncbi.nlm.nih.gov/pubmed/17895760>.

124. Yamaguchi T, Iwata J, Sugihara S, et al. Distinguishing benign notochordal cell tumors from vertebral chordoma. *Skeletal Radiol* 2008;37:291-299. Available at: <http://www.ncbi.nlm.nih.gov/pubmed/18188556>.

125. Nishiguchi T, Mochizuki K, Ohsawa M, et al. Differentiating benign notochordal cell tumors from chordomas: radiographic features on MRI, CT, and tomography. *AJR Am J Roentgenol* 2011;196:644-650. Available at: <http://www.ncbi.nlm.nih.gov/pubmed/21343509>.

126. Meyers SP, Hirsch WL, Jr., Curtin HD, et al. Chordomas of the skull base: MR features. *AJNR Am J Neuroradiol* 1992;13:1627-1636. Available at: <http://www.ncbi.nlm.nih.gov/pubmed/1442442>.

127. Weber AL, Liebsch NJ, Sanchez R, Sweriduk ST, Jr. Chordomas of the skull base. Radiologic and clinical evaluation. *Neuroimaging Clin N Am* 1994;4:515-527. Available at: <http://www.ncbi.nlm.nih.gov/pubmed/7952953>.

128. Rosenthal DI, Scott JA, Mankin HJ, et al. Sacrococcygeal chordoma: magnetic resonance imaging and computed tomography. *AJR Am J Roentgenol* 1985;145:143-147. Available at: <http://www.ncbi.nlm.nih.gov/pubmed/3873835>.



129. Plathow C, Weber MA, Debus J, Kauczor HU. [Imaging of sacral chordoma: comparison between MRI and CT]. *Radiologe* 2005;45:63-68. Available at: <http://www.ncbi.nlm.nih.gov/pubmed/15662521>.

130. Sung MS, Lee GK, Kang HS, et al. Sacrococcygeal chordoma: MR imaging in 30 patients. *Skeletal Radiol* 2005;34:87-94. Available at: <http://www.ncbi.nlm.nih.gov/pubmed/15480648>.

131. Meyer JE, Lepke RA, Lindfors KK, et al. Chordomas: their CT appearance in the cervical, thoracic and lumbar spine. *Radiology* 1984;153:693-696. Available at: <http://www.ncbi.nlm.nih.gov/pubmed/6494465>.

132. Ducou le Pointe H, Brugieres P, Chevalier X, et al. Imaging of chordomas of the mobile spine. *J Neuroradiol* 1991;18:267-276. Available at: <http://www.ncbi.nlm.nih.gov/pubmed/1765812>.

133. Ferraresi V, Nuzzo C, Zoccali C, et al. Chordoma: clinical characteristics, management and prognosis of a case series of 25 patients. *BMC Cancer* 2010;10:22-22. Available at: <http://www.ncbi.nlm.nih.gov/pubmed/20109225>.

134. Jawad MU, Scully SP. Surgery significantly improves survival in patients with chordoma. *Spine (Phila Pa 1976)* 2010;35:117-123. Available at: <http://www.ncbi.nlm.nih.gov/pubmed/20042964>.

135. Fuchs B, Dickey ID, Yaszemski MJ, et al. Operative management of sacral chordoma. *J Bone Joint Surg Am* 2005;87:2211-2216. Available at: <http://www.ncbi.nlm.nih.gov/pubmed/16203885>.

136. Ruggieri P, Mavrogenis AF, Ussia G, et al. Recurrence after and complications associated with adjuvant treatments for sacral giant cell tumor. *Clin Orthop Relat Res* 2010;468:2954-2961. Available at: <http://www.ncbi.nlm.nih.gov/pubmed/20623262>.

137. Stacchiotti S, Casali PG, Lo Vullo S, et al. Chordoma of the mobile spine and sacrum: a retrospective analysis of a series of patients surgically treated at two referral centers. *Ann Surg Oncol* 2010;17:211-219. Available at: <http://www.ncbi.nlm.nih.gov/pubmed/19847568>.

138. Kayani B, Sewell MD, Tan KA, et al. Prognostic Factors in the Operative Management of Sacral Chordomas. *World Neurosurg* 2015;84:1354-1361. Available at: <https://www.ncbi.nlm.nih.gov/pubmed/26115803>.

139. Forsyth PA, Cascino TL, Shaw EG, et al. Intracranial chordomas: a clinicopathological and prognostic study of 51 cases. *J Neurosurg* 1993;78:741-747. Available at: <http://www.ncbi.nlm.nih.gov/pubmed/8468605>.

140. Tzortzidis F, Elahi F, Wright D, et al. Patient outcome at long-term follow-up after aggressive microsurgical resection of cranial base chordomas. *Neurosurgery* 2006;59:230-237. Available at: <http://www.ncbi.nlm.nih.gov/pubmed/16883163>.

141. Sen C, Triana AI, Berglind N, et al. Clival chordomas: clinical management, results, and complications in 71 patients. *J Neurosurg* 2010;113:1059-1071. Available at: <http://www.ncbi.nlm.nih.gov/pubmed/19929198>.

142. Wu Z, Zhang J, Zhang L, et al. Prognostic factors for long-term outcome of patients with surgical resection of skull base chordomas-106 cases review in one institution. *Neurosurg Rev* 2010;33:451-456. Available at: <http://www.ncbi.nlm.nih.gov/pubmed/20668904>.

143. Di Maio S, Temkin N, Ramanathan D, Sekhar LN. Current comprehensive management of cranial base chordomas: 10-year meta-analysis of observational studies. *J Neurosurg* 2011;115:1094-1105. Available at: <http://www.ncbi.nlm.nih.gov/pubmed/21819197>.

144. Di Maio S, Rostomily R, Sekhar LN. Current surgical outcomes for cranial base chordomas: cohort study of 95 patients. *Neurosurgery* 2012;70:1355-1360. Available at: <http://www.ncbi.nlm.nih.gov/pubmed/22157545>.

145. Radaelli S, Stacchiotti S, Ruggieri P, et al. Sacral Chordoma: Long-term Outcome of a Large Series of Patients Surgically Treated at Two Reference Centers. *Spine (Phila Pa 1976)* 2016;41:1049-1057. Available at: <https://www.ncbi.nlm.nih.gov/pubmed/27054448>.



146. Boriani S, Bandiera S, Biagini R, et al. Chordoma of the mobile spine: fifty years of experience. *Spine (Phila Pa 1976)* 2006;31:493-503.

Available at: <http://www.ncbi.nlm.nih.gov/pubmed/16481964>.

147. Meng T, Yin H, Li B, et al. Clinical features and prognostic factors of patients with chordoma in the spine: a retrospective analysis of 153 patients in a single center. *Neuro Oncol* 2015;17:725-732. Available at:

<https://www.ncbi.nlm.nih.gov/pubmed/25488908>.

148. Ahmed AT, Abdel-Rahman O, Morsy M, et al. Management of Sacrococcygeal Chordoma: A Systematic Review and Meta-analysis of Observational Studies. *Spine (Phila Pa 1976)* 2018;43:E1157-E1169.

Available at: <https://www.ncbi.nlm.nih.gov/pubmed/29538244>.

149. Moojen WA, Vleggeert-Lankamp CL, Krol AD, Dijkstra SP. Long-term results: adjuvant radiotherapy in en bloc resection of sacrococcygeal chordoma is advisable. *Spine (Phila Pa 1976)* 2011;36:E656-661.

Available at: <http://www.ncbi.nlm.nih.gov/pubmed/21217422>.

150. Rotondo RL, Folkert W, Liebsch NJ, et al. High-dose proton-based radiation therapy in the management of spine chordomas: outcomes and clinicopathological prognostic factors. *J Neurosurg Spine* 2015;23:788-797. Available at:

<https://www.ncbi.nlm.nih.gov/pubmed/26340383>.

151. Catton C, O'Sullivan B, Bell R, et al. Chordoma: long-term follow-up after radical photon irradiation. *Radiother Oncol* 1996;41:67-72. Available at:

<http://www.ncbi.nlm.nih.gov/pubmed/8961370>.

152. Wagner TD, Kobayashi W, Dean S, et al. Combination short-course preoperative irradiation, surgical resection, and reduced-field high-dose postoperative irradiation in the treatment of tumors involving the bone. *Int J Radiat Oncol Biol Phys* 2009;73:259-266. Available at:

<http://www.ncbi.nlm.nih.gov/pubmed/19100921>.

153. Pennicooke B, Laufer I, Sahgal A, et al. Safety and Local Control of Radiation Therapy for Chordoma of the Spine and Sacrum: A Systematic Review. *Spine (Phila Pa 1976)* 2016;41 Suppl 20:S186-S192. Available at:

<https://www.ncbi.nlm.nih.gov/pubmed/27509195>.

154. Foweraker KL, Burton KE, Maynard SE, et al. High-dose radiotherapy in the management of chordoma and chondrosarcoma of the skull base and cervical spine: Part 1--Clinical outcomes. *Clin Oncol (R Coll Radiol)* 2007;19:509-516. Available at:

<http://www.ncbi.nlm.nih.gov/pubmed/17524633>.

155. Potluri S, Jefferies SJ, Jena R, et al. Residual postoperative tumour volume predicts outcome after high-dose radiotherapy for chordoma and chondrosarcoma of the skull base and spine. *Clin Oncol (R Coll Radiol)* 2011;23:199-208. Available at:

<http://www.ncbi.nlm.nih.gov/pubmed/20980136>.

156. Jian BJ, Bloch OG, Yang I, et al. Adjuvant radiation therapy and chondroid chordoma subtype are associated with a lower tumor recurrence rate of cranial chordoma. *J Neurooncol* 2010;98:101-108.

Available at: <http://www.ncbi.nlm.nih.gov/pubmed/19953297>.

157. Yasuda M, Bresson D, Chibbaro S, et al. Chordomas of the skull base and cervical spine: clinical outcomes associated with a multimodal surgical resection combined with proton-beam radiation in 40 patients. *Neurosurg Rev* 2012;35:171-182. Available at:

<http://www.ncbi.nlm.nih.gov/pubmed/21863225>.

158. McDonald MW, Linton OR, Moore MG, et al. Influence of Residual Tumor Volume and Radiation Dose Coverage in Outcomes for Clival Chordoma. *Int J Radiat Oncol Biol Phys* 2016;95:304-311. Available at:

<https://www.ncbi.nlm.nih.gov/pubmed/26519991>.

159. Fagundes MA, Hug EB, Liebsch NJ, et al. Radiation therapy for chordomas of the base of skull and cervical spine: patterns of failure and outcome after relapse. *Int J Radiat Oncol Biol Phys* 1995;33:579-584.

Available at: <http://www.ncbi.nlm.nih.gov/pubmed/7558946>.

160. Noel G, Feuvret L, Calugaru V, et al. Chordomas of the base of the skull and upper cervical spine. One hundred patients irradiated by a 3D conformal technique combining photon and proton beams. *Acta Oncol* 2005;44:700-708. Available at:

<http://www.ncbi.nlm.nih.gov/pubmed/16227160>.



161. Park L, Delaney TF, Liebsch NJ, et al. Sacral chordomas: Impact of high-dose proton/photon-beam radiation therapy combined with or without surgery for primary versus recurrent tumor. *Int J Radiat Oncol Biol Phys* 2006;65:1514-1521. Available at:

<http://www.ncbi.nlm.nih.gov/pubmed/16757128>.

162. Amichetti M, Cianchetti M, Amelio D, et al. Proton therapy in chordoma of the base of the skull: a systematic review. *Neurosurg Rev* 2009;32:403-416. Available at:

<http://www.ncbi.nlm.nih.gov/pubmed/19319583>.

163. Staab A, Rutz HP, Ares C, et al. Spot-scanning-based proton therapy for extracranial chordoma. *Int J Radiat Oncol Biol Phys* 2011;81:489-496.

Available at: <http://www.ncbi.nlm.nih.gov/pubmed/21497457>.

164. Rutz HP, Weber DC, Sugahara S, et al. Extracranial chordoma: Outcome in patients treated with function-preserving surgery followed by spot-scanning proton beam irradiation. *Int J Radiat Oncol Biol Phys* 2007;67:512-520. Available at:

<http://www.ncbi.nlm.nih.gov/pubmed/17084540>.

165. Schulz-Ertner D, Karger CP, Feuerhake A, et al. Effectiveness of carbon ion radiotherapy in the treatment of skull-base chordomas. *Int J Radiat Oncol Biol Phys* 2007;68:449-457. Available at:

<http://www.ncbi.nlm.nih.gov/pubmed/17363188>.

166. Takahashi S, Kawase T, Yoshida K, et al. Skull base chordomas: efficacy of surgery followed by carbon ion radiotherapy. *Acta Neurochir (Wien)* 2009;151:759-769. Available at:

<http://www.ncbi.nlm.nih.gov/pubmed/19434365>.

167. Nishida Y, Kamada T, Imai R, et al. Clinical outcome of sacral chordoma with carbon ion radiotherapy compared with surgery. *Int J Radiat Oncol Biol Phys* 2011;79:110-116. Available at:

<http://www.ncbi.nlm.nih.gov/pubmed/20400242>.

168. Imai R, Kamada T, Araki N, et al. Carbon Ion Radiation Therapy for Unresectable Sacral Chordoma: An Analysis of 188 Cases. *Int J Radiat*

Oncol Biol Phys 2016;95:322-327. Available at:

<https://www.ncbi.nlm.nih.gov/pubmed/27084649>.

169. Uhl M, Welzel T, Jensen A, et al. Carbon ion beam treatment in patients with primary and recurrent sacrococcygeal chordoma. *Strahlenther Onkol* 2015;191:597-603. Available at:

<https://www.ncbi.nlm.nih.gov/pubmed/25737378>.

170. Kabolizadeh P, Chen YL, Liebsch N, et al. Updated Outcome and Analysis of Tumor Response in Mobile Spine and Sacral Chordoma Treated With Definitive High-Dose Photon/Proton Radiation Therapy. *Int J Radiat Oncol Biol Phys* 2017;97:254-262. Available at:

<https://www.ncbi.nlm.nih.gov/pubmed/27986348>.

171. Baumann BC, Lustig RA, Mazzoni S, et al. A prospective clinical trial of proton therapy for chordoma and chondrosarcoma: Feasibility assessment. *J Surg Oncol* 2019;120:200-205. Available at:

<https://www.ncbi.nlm.nih.gov/pubmed/31111502>.

172. Zhou J, Yang B, Wang X, Jing Z. Comparison of the Effectiveness of Radiotherapy with Photons and Particles for Chordoma After Surgery: A Meta-Analysis. *World Neurosurg* 2018;117:46-53. Available at:

<https://www.ncbi.nlm.nih.gov/pubmed/29879512>.

173. Gabriele P, Macias V, Stasi M, et al. Feasibility of intensity-modulated radiation therapy in the treatment of advanced cervical chordoma. *Tumori* 2003;89:298-304. Available at:

<http://www.ncbi.nlm.nih.gov/pubmed/12908787>.

174. Yoneoka Y, Tsumanuma I, Fukuda M, et al. Cranial base chordoma--long term outcome and review of the literature. *Acta Neurochir (Wien)* 2008;150:773-778; . Available at:

<http://www.ncbi.nlm.nih.gov/pubmed/18548191>.

175. Zabel-du Bois A, Nikoghosyan A, Schwahofer A, et al. Intensity modulated radiotherapy in the management of sacral chordoma in primary versus recurrent disease. *Radiother Oncol* 2010;97:408-412. Available at:

<http://www.ncbi.nlm.nih.gov/pubmed/21056488>.



176. Kano H, Iqbal FO, Sheehan J, et al. Stereotactic radiosurgery for chordoma: a report from the North American Gamma Knife Consortium. *Neurosurgery* 2011;68:379-389. Available at: <http://www.ncbi.nlm.nih.gov/pubmed/21135744>.

177. Bugoci DM, Girvigian MR, Chen JCT, et al. Photon-based Fractionated Stereotactic Radiotherapy for Postoperative Treatment of Skull Base Chordomas. *Am J Clin Oncol* 2012. Available at: <http://www.ncbi.nlm.nih.gov/pubmed/22772429>.

178. Fleming GF, Heimann PS, Stephens JK, et al. Dedifferentiated chordoma. Response to aggressive chemotherapy in two cases. *Cancer* 1993;72:714-718. Available at: <http://www.ncbi.nlm.nih.gov/pubmed/8334623>.

179. Tamborini E, Miselli F, Negri T, et al. Molecular and biochemical analyses of platelet-derived growth factor receptor (PDGFR) B, PDGFRA, and KIT receptors in chordomas. *Clin Cancer Res* 2006;12:6920-6928. Available at: <http://www.ncbi.nlm.nih.gov/pubmed/17145809>.

180. Tamborini E, Viridis E, Negri T, et al. Analysis of receptor tyrosine kinases (RTKs) and downstream pathways in chordomas. *Neuro Oncol* 2010;12:776-789. Available at: <http://www.ncbi.nlm.nih.gov/pubmed/20164240>.

181. Casali PG, Stacchiotti S, Grosso F, et al. Adding cisplatin (CDDP) to imatinib (IM) re-establishes tumor response following secondary resistance to IM in advanced chordoma [abstract]. *J Clin Oncol* 2007;25:Abstract 10038. Available at: http://ascopubs.org/doi/abs/10.1200/jco.2007.25.18_suppl.10038.

182. Stacchiotti S, Marrari A, Tamborini E, et al. Response to imatinib plus sirolimus in advanced chordoma. *Ann Oncol* 2009;20:1886-1894. Available at: <http://www.ncbi.nlm.nih.gov/pubmed/19570961>.

183. Hindi N, Casali PG, Morosi C, et al. Imatinib in advanced chordoma: A retrospective case series analysis. *Eur J Cancer* 2015;51:2609-2614. Available at: <https://www.ncbi.nlm.nih.gov/pubmed/26283036>.

184. Singhal N, Kotasek D, Parnis FX. Response to erlotinib in a patient with treatment refractory chordoma. *Anticancer Drugs* 2009;20:953-955. Available at: <http://www.ncbi.nlm.nih.gov/pubmed/19730087>.

185. Launay SG, Chetaille B, Medina F, et al. Efficacy of epidermal growth factor receptor targeting in advanced chordoma: case report and literature review. *BMC Cancer* 2011;11:423-423. Available at: <http://www.ncbi.nlm.nih.gov/pubmed/21970335>.

186. Stacchiotti S, Tamborini E, Lo Vullo S, et al. Phase II study on lapatinib in advanced EGFR-positive chordoma. *Ann Oncol* 2013;24:1931-1936. Available at: <http://www.ncbi.nlm.nih.gov/pubmed/23559153>.

187. Bompas E, Le Cesne A, Tresch-Bruneel E, et al. Sorafenib in patients with locally advanced and metastatic chordomas: a phase II trial of the French Sarcoma Group (GSF/GETO). *Ann Oncol* 2015;26:2168-2173. Available at: <https://www.ncbi.nlm.nih.gov/pubmed/26202596>.

188. Lebellec L, Bertucci F, Tresch-Bruneel E, et al. Circulating vascular endothelial growth factor (VEGF) as predictive factor of progression-free survival in patients with advanced chordoma receiving sorafenib: an analysis from a phase II trial of the french sarcoma group (GSF/GETO). *Oncotarget* 2016. Available at: <https://www.ncbi.nlm.nih.gov/pubmed/27659533>.

189. Thieblemont C, Biron P, Rocher F, et al. Prognostic factors in chordoma: role of postoperative radiotherapy. *Eur J Cancer* 1995;31A:2255-2259. Available at: <http://www.ncbi.nlm.nih.gov/pubmed/8652252>.

190. Boriani S, Saravanja D, Yamada Y, et al. Challenges of local recurrence and cure in low grade malignant tumors of the spine. *Spine (Phila Pa 1976)* 2009;34:S48-57. Available at: <http://www.ncbi.nlm.nih.gov/pubmed/19829277>.

191. Chambers PW, Schwinn CP. Chordoma. A clinicopathologic study of metastasis. *Am J Clin Pathol* 1979;72:765-776. Available at: <http://www.ncbi.nlm.nih.gov/pubmed/389031>.



192. McPherson CM, Suki D, McCutcheon IE, et al. Metastatic disease from spinal chordoma: a 10-year experience. *J Neurosurg Spine* 2006;5:277-280. Available at:

<http://www.ncbi.nlm.nih.gov/pubmed/17048762>.

193. Ailon T, Torabi R, Fisher CG, et al. Management of Locally Recurrent Chordoma of the Mobile Spine and Sacrum: A Systematic Review. *Spine (Phila Pa 1976)* 2016;41 Suppl 20:S193-S198. Available at:

<https://www.ncbi.nlm.nih.gov/pubmed/27753782>.

194. Shing DC, McMullan DJ, Roberts P, et al. FUS/ERG gene fusions in Ewing's tumors. *Cancer Res* 2003;63:4568-4576. Available at:

<http://www.ncbi.nlm.nih.gov/pubmed/12907633>.

195. Ng TL, O'Sullivan MJ, Pallen CJ, et al. Ewing sarcoma with novel translocation t(2;16) producing an in-frame fusion of FUS and FEV. *J Mol Diagn* 2007;9:459-463. Available at:

<http://www.ncbi.nlm.nih.gov/pubmed/17620387>.

196. Ambros IM, Ambros PF, Strehl S, et al. MIC2 is a specific marker for Ewing's sarcoma and peripheral primitive neuroectodermal tumors. Evidence for a common histogenesis of Ewing's sarcoma and peripheral primitive neuroectodermal tumors from MIC2 expression and specific chromosome aberration. *Cancer* 1991;67:1886-1893. Available at:

<http://www.ncbi.nlm.nih.gov/pubmed/1848471>.

197. Perlman EJ, Dickman PS, Askin FB, et al. Ewing's sarcoma--routine diagnostic utilization of MIC2 analysis: a Pediatric Oncology Group/Children's Cancer Group Intergroup Study. *Hum Pathol* 1994;25:304-307. Available at:

<http://www.ncbi.nlm.nih.gov/pubmed/8150461>.

198. Olsen SH, Thomas DG, Lucas DR. Cluster analysis of immunohistochemical profiles in synovial sarcoma, malignant peripheral nerve sheath tumor, and Ewing sarcoma. *Mod Pathol* 2006;19:659-668. Available at:

<http://www.ncbi.nlm.nih.gov/pubmed/16528378>.

199. Machado I, Navarro S, Llombart-Bosch A. Ewing sarcoma and the new emerging Ewing-like sarcomas: (CIC and BCOR-rearranged-

sarcomas). A systematic review. *Histol Histopathol* 2016;31:1169-1181. Available at: <https://www.ncbi.nlm.nih.gov/pubmed/27306060>.

200. Sbaraglia M, Righi A, Gambarotti M, Dei Tos AP. Ewing sarcoma and Ewing-like tumors. *Virchows Arch* 2020;476:109-119. Available at:

<https://www.ncbi.nlm.nih.gov/pubmed/31802230>.

201. Glaubiger DL, Makuch R, Schwarz J, et al. Determination of prognostic factors and their influence on therapeutic results in patients with Ewing's sarcoma. *Cancer* 1980;45:2213-2219. Available at:

<http://www.ncbi.nlm.nih.gov/pubmed/7370962>.

202. Gobel V, Jurgens H, Etspuler G, et al. Prognostic significance of tumor volume in localized Ewing's sarcoma of bone in children and adolescents. *J Cancer Res Clin Oncol* 1987;113:187-191. Available at:

<http://www.ncbi.nlm.nih.gov/pubmed/3558454>.

203. Ahrens S, Hoffmann C, Jabar S, et al. Evaluation of prognostic factors in a tumor volume-adapted treatment strategy for localized Ewing sarcoma of bone: the CESS 86 experience. *Cooperative Ewing Sarcoma Study. Med Pediatr Oncol* 1999;32:186-195. Available at:

<http://www.ncbi.nlm.nih.gov/pubmed/10064186>.

204. Bacci G, Longhi A, Ferrari S, et al. Prognostic factors in non-metastatic Ewing's sarcoma tumor of bone: an analysis of 579 patients treated at a single institution with adjuvant or neoadjuvant chemotherapy between 1972 and 1998. *Acta Oncol* 2006;45:469-475. Available at:

<http://www.ncbi.nlm.nih.gov/pubmed/16760184>.

205. Rodriguez-Galindo C, Liu T, Krasin MJ, et al. Analysis of prognostic factors in ewing sarcoma family of tumors: review of St. Jude Children's Research Hospital studies. *Cancer* 2007;110:375-384. Available at:

<http://www.ncbi.nlm.nih.gov/pubmed/17569105>.

206. Serlo J, Helenius I, Vettenranta K, et al. Surgically treated patients with axial and peripheral Ewing's sarcoma family of tumours: A population based study in Finland during 1990-2009. *Eur J Surg Oncol* 2015;41:893-898. Available at: <http://www.ncbi.nlm.nih.gov/pubmed/25817983>.



207. Grevener K, Haveman LM, Ranft A, et al. Management and Outcome of Ewing Sarcoma of the Head and Neck. *Pediatr Blood Cancer* 2016;63:604-610. Available at: <https://www.ncbi.nlm.nih.gov/pubmed/26702872>.

208. Bacci G, Boriani S, Balladelli A, et al. Treatment of nonmetastatic Ewing's sarcoma family tumors of the spine and sacrum: the experience from a single institution. *Eur Spine J* 2009;18:1091-1095. Available at: <http://www.ncbi.nlm.nih.gov/pubmed/19277725>.

209. Bosma SE, Ayu O, Fiocco M, et al. Prognostic factors for survival in Ewing sarcoma: A systematic review. *Surg Oncol* 2018;27:603-610. Available at: <https://www.ncbi.nlm.nih.gov/pubmed/30449479>.

210. Cangir A, Vietti TJ, Gehan EA, et al. Ewing's sarcoma metastatic at diagnosis. Results and comparisons of two intergroup Ewing's sarcoma studies. *Cancer* 1990;66:887-893. Available at: <http://www.ncbi.nlm.nih.gov/pubmed/2201433>.

211. Paulino AC, Mai WY, Teh BS. Radiotherapy in metastatic ewing sarcoma. *Am J Clin Oncol* 2013;36:283-286. Available at: <http://www.ncbi.nlm.nih.gov/pubmed/22547005>.

212. Oberlin O, Deley MC, Bui BN, et al. Prognostic factors in localized Ewing's tumours and peripheral neuroectodermal tumours: the third study of the French Society of Paediatric Oncology (EW88 study). *Br J Cancer* 2001;85:1646-1654. Available at: <http://www.ncbi.nlm.nih.gov/pubmed/11742482>.

213. Paulussen M, Ahrens S, Dunst J, et al. Localized Ewing tumor of bone: final results of the cooperative Ewing's Sarcoma Study CESS 86. *J Clin Oncol* 2001;19:1818-1829. Available at: <http://www.ncbi.nlm.nih.gov/pubmed/11251014>.

214. Pan HY, Morani A, Wang WL, et al. Prognostic factors and patterns of relapse in ewing sarcoma patients treated with chemotherapy and r0 resection. *Int J Radiat Oncol Biol Phys* 2015;92:349-357. Available at: <https://www.ncbi.nlm.nih.gov/pubmed/25772182>.

215. Kissane JM, Askin FB, Foulkes M, et al. Ewing's sarcoma of bone: clinicopathologic aspects of 303 cases from the Intergroup Ewing's Sarcoma Study. *Hum Pathol* 1983;14:773-779. Available at: <http://www.ncbi.nlm.nih.gov/pubmed/6885037>.

216. Gupta AA, Pappo A, Saunders N, et al. Clinical outcome of children and adults with localized Ewing sarcoma: impact of chemotherapy dose and timing of local therapy. *Cancer* 2010;116:3189-3194. Available at: <http://www.ncbi.nlm.nih.gov/pubmed/20564643>.

217. Lee J, Hoang BH, Ziogas A, Zell JA. Analysis of prognostic factors in Ewing sarcoma using a population-based cancer registry. *Cancer* 2010;116:1964-1973. Available at: <http://www.ncbi.nlm.nih.gov/pubmed/20151425>.

218. Treglia G, Salsano M, Stefanelli A, et al. Diagnostic accuracy of (1)(8)F-FDG-PET and PET/CT in patients with Ewing sarcoma family tumours: a systematic review and a meta-analysis. *Skeletal Radiol* 2012;41:249-256. Available at: <http://www.ncbi.nlm.nih.gov/pubmed/22072239>.

219. Avigad S, Cohen IJ, Zilberstein J, et al. The predictive potential of molecular detection in the nonmetastatic Ewing family of tumors. *Cancer* 2004;100:1053-1058. Available at: <http://www.ncbi.nlm.nih.gov/pubmed/14983502>.

220. de Alava E, Kawai A, Healey JH, et al. EWS-FLI1 fusion transcript structure is an independent determinant of prognosis in Ewing's sarcoma. *J Clin Oncol* 1998;16:1248-1255. Available at: <http://www.ncbi.nlm.nih.gov/pubmed/9552022>.

221. Zoubek A, Dockhorn-Dworniczak B, Delattre O, et al. Does expression of different EWS chimeric transcripts define clinically distinct risk groups of Ewing tumor patients? *J Clin Oncol* 1996;14:1245-1251. Available at: <http://www.ncbi.nlm.nih.gov/pubmed/8648380>.

222. Le Deley MC, Delattre O, Schaefer KL, et al. Impact of EWS-ETS fusion type on disease progression in Ewing's sarcoma/peripheral primitive neuroectodermal tumor: prospective results from the cooperative Euro-



E.W.I.N.G. 99 trial. J Clin Oncol 2010;28:1982-1988. Available at: <http://www.ncbi.nlm.nih.gov/pubmed/20308673>.

223. van Doorninck JA, Ji L, Schaub B, et al. Current treatment protocols have eliminated the prognostic advantage of type 1 fusions in Ewing sarcoma: a report from the Children's Oncology Group. J Clin Oncol 2010;28:1989-1994. Available at: <http://www.ncbi.nlm.nih.gov/pubmed/20308669>.

224. Burgert EO, Nesbit ME, Garnsey LA, et al. Multimodal therapy for the management of nonpelvic, localized Ewing's sarcoma of bone: intergroup study IESS-II. J Clin Oncol 1990;8:1514-1524. Available at: <http://www.ncbi.nlm.nih.gov/pubmed/2099751>.

225. Nesbit ME, Gehan EA, Burgert EO, et al. Multimodal therapy for the management of primary, nonmetastatic Ewing's sarcoma of bone: a long-term follow-up of the First Intergroup study. J Clin Oncol 1990;8:1664-1674. Available at: <http://www.ncbi.nlm.nih.gov/pubmed/2213103>.

226. Grier HE, Krailo MD, Tarbell NJ, et al. Addition of ifosfamide and etoposide to standard chemotherapy for Ewing's sarcoma and primitive neuroectodermal tumor of bone. N Engl J Med 2003;348:694-701. Available at: <http://www.ncbi.nlm.nih.gov/pubmed/12594313>.

227. Shamberger RC, LaQuaglia MP, Gebhardt MC, et al. Ewing sarcoma/primitive neuroectodermal tumor of the chest wall: impact of initial versus delayed resection on tumor margins, survival, and use of radiation therapy. Ann Surg 2003;238:563-567; discussion 567-568. Available at: <http://www.ncbi.nlm.nih.gov/pubmed/14530727>.

228. Krasin MJ, Davidoff AM, Rodriguez-Galindo C, et al. Definitive surgery and multiagent systemic therapy for patients with localized Ewing sarcoma family of tumors: local outcome and prognostic factors. Cancer 2005;104:367-373. Available at: <http://www.ncbi.nlm.nih.gov/pubmed/15948159>.

229. Wexler LH, DeLaney TF, Tsokos M, et al. Ifosfamide and etoposide plus vincristine, doxorubicin, and cyclophosphamide for newly diagnosed

Ewing's sarcoma family of tumors. Cancer 1996;78:901-911. Available at: <http://www.ncbi.nlm.nih.gov/pubmed/8756388>.

230. Rosito P, Mancini AF, Rondelli R, et al. Italian Cooperative Study for the treatment of children and young adults with localized Ewing sarcoma of bone: a preliminary report of 6 years of experience. Cancer 1999;86:421-428. Available at: <http://www.ncbi.nlm.nih.gov/pubmed/10430250>.

231. Kolb EA, Kushner BH, Gorlick R, et al. Long-term event-free survival after intensive chemotherapy for Ewing's family of tumors in children and young adults. J Clin Oncol 2003;21:3423-3430. Available at: <http://www.ncbi.nlm.nih.gov/pubmed/12972518>.

232. Oberlin O, Habrand JL, Zucker JM, et al. No benefit of ifosfamide in Ewing's sarcoma: a nonrandomized study of the French Society of Pediatric Oncology. J Clin Oncol 1992;10:1407-1412. Available at: <http://www.ncbi.nlm.nih.gov/pubmed/1517783>.

233. Bacci G, Picci P, Ferrari S, et al. Neoadjuvant chemotherapy for Ewing's sarcoma of bone: no benefit observed after adding ifosfamide and etoposide to vincristine, actinomycin, cyclophosphamide, and doxorubicin in the maintenance phase--results of two sequential studies. Cancer 1998;82:1174-1183. Available at: <http://www.ncbi.nlm.nih.gov/pubmed/9506366>.

234. Yock TI, Krailo M, Fryer CJ, et al. Local control in pelvic Ewing sarcoma: analysis from INT-0091--a report from the Children's Oncology Group. J Clin Oncol 2006;24:3838-3843. Available at: <http://www.ncbi.nlm.nih.gov/pubmed/16921035>.

235. Granowetter L, Womer R, Devidas M, et al. Dose-intensified compared with standard chemotherapy for nonmetastatic Ewing sarcoma family of tumors: a Children's Oncology Group Study. J Clin Oncol 2009;27:2536-2541. Available at: <http://www.ncbi.nlm.nih.gov/pubmed/19349548>.

236. Womer RB, West DC, Krailo MD, et al. Randomized Controlled Trial of Interval-Compressed Chemotherapy for the Treatment of Localized



Ewing Sarcoma: A Report From the Children's Oncology Group. *Journal of Clinical Oncology* 2012;30:4148-4154. Available at:

<http://www.ncbi.nlm.nih.gov/pubmed/23091096>.

237. Brennan B, Kirton L, Marec-Berard P, et al. Comparison of two chemotherapy regimens in Ewing sarcoma (ES): Overall and subgroup results of the Euro Ewing 2012 randomized trial (EE2012). *Journal of Clinical Oncology* 2020;38:11500-11500. Available at:

https://ascopubs.org/doi/abs/10.1200/JCO.2020.38.15_suppl.11500.

238. Miser JS, Krailo MD, Tarbell NJ, et al. Treatment of metastatic Ewing's sarcoma or primitive neuroectodermal tumor of bone: evaluation of combination ifosfamide and etoposide--a Children's Cancer Group and Pediatric Oncology Group study. *J Clin Oncol* 2004;22:2873-2876. Available at:

<http://www.ncbi.nlm.nih.gov/pubmed/15254055>.

239. Paulussen M, Craft AW, Lewis I, et al. Results of the EICESS-92 Study: two randomized trials of Ewing's sarcoma treatment--cyclophosphamide compared with ifosfamide in standard-risk patients and assessment of benefit of etoposide added to standard treatment in high-risk patients. *J Clin Oncol* 2008;26:4385-4393. Available at:

<http://www.ncbi.nlm.nih.gov/pubmed/18802150>.

240. Le Deley MC, Paulussen M, Lewis I, et al. Cyclophosphamide Compared With Ifosfamide in Consolidation Treatment of Standard-Risk Ewing Sarcoma: Results of the Randomized Noninferiority Euro-EWING99-R1 Trial. *J Clin Oncol* 2014. Available at:

<http://www.ncbi.nlm.nih.gov/pubmed/24982464>.

241. Ferrari S, Sundby Hall K, Luksch R, et al. Nonmetastatic Ewing family tumors: high-dose chemotherapy with stem cell rescue in poor responder patients. Results of the Italian Sarcoma Group/Scandinavian Sarcoma Group III protocol. *Annals of Oncology* 2011;22:1221-1227. Available at:

<http://www.ncbi.nlm.nih.gov/pubmed/21059639>.

242. Gaspar N, Rey A, Berard PM, et al. Risk adapted chemotherapy for localised Ewing's sarcoma of bone: The French EW93 study. *Eur J Cancer* 2012;48:1376-1385. Available at:

<http://www.ncbi.nlm.nih.gov/pubmed/22516209>.

243. Kushner BH, Meyers PA. How effective is dose-intensive/myeloablative therapy against Ewing's sarcoma/primitive neuroectodermal tumor metastatic to bone or bone marrow? The Memorial Sloan-Kettering experience and a literature review. *J Clin Oncol* 2001;19:870-880. Available at:

<http://www.ncbi.nlm.nih.gov/pubmed/11157041>.

244. Juergens C, Weston C, Lewis I, et al. Safety assessment of intensive induction with vincristine, ifosfamide, doxorubicin, and etoposide (VIDE) in the treatment of Ewing tumors in the EURO-E.W.I.N.G. 99 clinical trial. *Pediatr Blood Cancer* 2006;47:22-29. Available at:

<http://www.ncbi.nlm.nih.gov/pubmed/16572419>.

245. Oberlin O, Rey A, Desfachelles AS, et al. Impact of high-dose busulfan plus melphalan as consolidation in metastatic Ewing tumors: a study by the Societe Francaise des Cancers de l'Enfant. *J Clin Oncol* 2006;24:3997-4002. Available at:

<http://www.ncbi.nlm.nih.gov/pubmed/16921053>.

246. Rosenthal J, Bolotin E, Shakhnovits M, et al. High-dose therapy with hematopoietic stem cell rescue in patients with poor prognosis Ewing family tumors. *Bone Marrow Transplant* 2008;42:311-318. Available at:

<http://www.ncbi.nlm.nih.gov/pubmed/18587438>.

247. Burdach S, Thiel U, Schoniger M, et al. Total body MRI-governed involved compartment irradiation combined with high-dose chemotherapy and stem cell rescue improves long-term survival in Ewing tumor patients with multiple primary bone metastases. *Bone Marrow Transplant* 2010;45:483-489. Available at:

<http://www.ncbi.nlm.nih.gov/pubmed/19684633>.

248. Ladenstein R, Potschger U, Le Deley MC, et al. Primary disseminated multifocal Ewing sarcoma: results of the Euro-EWING 99 trial. *J Clin Oncol* 2010;28:3284-3291. Available at:

<http://www.ncbi.nlm.nih.gov/pubmed/20547982>.

249. Whelan J, Le Deley MC, Dirksen U, et al. High-Dose Chemotherapy and Blood Autologous Stem-Cell Rescue Compared With Standard Chemotherapy in Localized High-Risk Ewing Sarcoma: Results of Euro-



E.W.I.N.G.99 and Ewing-2008. J Clin Oncol 2018;36:JCO2018782516. Available at: <https://www.ncbi.nlm.nih.gov/pubmed/30188789>.

250. Dunst J, Jurgens H, Sauer R, et al. Radiation therapy in Ewing's sarcoma: an update of the CESS 86 trial. Int J Radiat Oncol Biol Phys 1995;32:919-930. Available at: <http://www.ncbi.nlm.nih.gov/pubmed/7607966>.

251. Schuck A, Ahrens S, Paulussen M, et al. Local therapy in localized Ewing tumors: results of 1058 patients treated in the CESS 81, CESS 86, and EICESS 92 trials. Int J Radiat Oncol Biol Phys 2003;55:168-177. Available at: <http://www.ncbi.nlm.nih.gov/pubmed/12504050>.

252. DuBois SG, Krailo MD, Gebhardt MC, et al. Comparative evaluation of local control strategies in localized Ewing sarcoma of bone: a report from the Children's Oncology Group. Cancer 2015;121:467-475. Available at: <https://www.ncbi.nlm.nih.gov/pubmed/25251206>.

253. Schuck A, Ahrens S, von Schorlemer I, et al. Radiotherapy in Ewing tumors of the vertebrae: treatment results and local relapse analysis of the CESS 81/86 and EICESS 92 trials. Int J Radiat Oncol Biol Phys 2005;63:1562-1567. Available at: <http://www.ncbi.nlm.nih.gov/pubmed/16137838>.

254. Indelicato DJ, Keole SR, Shahlaee AH, et al. Definitive radiotherapy for ewing tumors of extremities and pelvis: long-term disease control, limb function, and treatment toxicity. Int J Radiat Oncol Biol Phys 2008;72:871-877. Available at: <https://www.ncbi.nlm.nih.gov/pubmed/18455323>.

255. Krasin MJ, Rodriguez-Galindo C, Billups CA, et al. Definitive irradiation in multidisciplinary management of localized Ewing sarcoma family of tumors in pediatric patients: outcome and prognostic factors. Int J Radiat Oncol Biol Phys 2004;60:830-838. Available at: <http://www.ncbi.nlm.nih.gov/pubmed/15465200>.

256. Paulino AC, Nguyen TX, Mai WY, et al. Dose response and local control using radiotherapy in non-metastatic Ewing sarcoma. Pediatr Blood Cancer 2007;49:145-148. Available at: <https://www.ncbi.nlm.nih.gov/pubmed/16732580>.

257. Haeusler J, Ranft A, Boelling T, et al. The value of local treatment in patients with primary, disseminated, multifocal Ewing sarcoma (PDMES). Cancer 2010;116:443-450. Available at: <http://www.ncbi.nlm.nih.gov/pubmed/19924786>.

258. Paulussen M, Ahrens S, Burdach S, et al. Primary metastatic (stage IV) Ewing tumor: survival analysis of 171 patients from the EICESS studies. European Intergroup Cooperative Ewing Sarcoma Studies. Ann Oncol 1998;9:275-281. Available at: <http://www.ncbi.nlm.nih.gov/pubmed/9602261>.

259. Casey DL, Wexler LH, Meyers PA, et al. Radiation for bone metastases in Ewing sarcoma and rhabdomyosarcoma. Pediatr Blood Cancer 2015;62:445-449. Available at: <http://www.ncbi.nlm.nih.gov/pubmed/25346208>.

260. Bedetti B, Wiebe K, Ranft A, et al. Local control in Ewing sarcoma of the chest wall: results of the EURO-EWING 99 trial. Ann Surg Oncol 2015;22:2853-2859. Available at: <https://www.ncbi.nlm.nih.gov/pubmed/26104542>.

261. Denbo JW, Shannon Orr W, Wu Y, et al. Timing of surgery and the role of adjuvant radiotherapy in ewing sarcoma of the chest wall: a single-institution experience. Ann Surg Oncol 2012;19:3809-3815. Available at: <http://www.ncbi.nlm.nih.gov/pubmed/22752372>.

262. Burgers JM, van Glabbeke M, Busson A, et al. Osteosarcoma of the limbs. Report of the EORTC-SIOP 03 trial 20781 investigating the value of adjuvant treatment with chemotherapy and/or prophylactic lung irradiation. Cancer 1988;61:1024-1031. Available at: <https://www.ncbi.nlm.nih.gov/pubmed/3276390>.

263. Ronchi L, Buwenge M, Cortesi A, et al. Whole Lung Irradiation in Patients with Osteosarcoma and Ewing Sarcoma. Anticancer Res 2018;38:4977-4985. Available at: <https://www.ncbi.nlm.nih.gov/pubmed/30194141>.

264. Bolling T, Schuck A, Paulussen M, et al. Whole lung irradiation in patients with exclusively pulmonary metastases of Ewing tumors. Toxicity



analysis and treatment results of the EICESS-92 trial. *Strahlenther Onkol* 2008;184:193-197. Available at: <https://www.ncbi.nlm.nih.gov/pubmed/18398583>.

265. Bacci G, Forni C, Longhi A, et al. Long-term outcome for patients with non-metastatic Ewing's sarcoma treated with adjuvant and neoadjuvant chemotherapies. 402 patients treated at Rizzoli between 1972 and 1992. *Eur J Cancer* 2004;40:73-83. Available at: <http://www.ncbi.nlm.nih.gov/pubmed/14687792>.

266. Rodriguez-Galindo C, Billups CA, Kun LE, et al. Survival after recurrence of Ewing tumors: the St Jude Children's Research Hospital experience, 1979-1999. *Cancer* 2002;94:561-569. Available at: <http://www.ncbi.nlm.nih.gov/pubmed/11900241>.

267. Bacci G, Ferrari S, Longhi A, et al. Therapy and survival after recurrence of Ewing's tumors: the Rizzoli experience in 195 patients treated with adjuvant and neoadjuvant chemotherapy from 1979 to 1997. *Ann Oncol* 2003;14:1654-1659. Available at: <http://www.ncbi.nlm.nih.gov/pubmed/14581274>.

268. Leavey PJ, Mascarenhas L, Marina N, et al. Prognostic factors for patients with Ewing sarcoma (EWS) at first recurrence following multi-modality therapy: A report from the Children's Oncology Group. *Pediatr Blood Cancer* 2008;51:334-338. Available at: <http://www.ncbi.nlm.nih.gov/pubmed/18506764>.

269. Ferrari S, Luksch R, Hall KS, et al. Post-relapse survival in patients with Ewing sarcoma. *Pediatr Blood Cancer* 2015;62:994-999. Available at: <https://www.ncbi.nlm.nih.gov/pubmed/25585917>.

270. Robinson SI, Ahmed SK, Okuno SH, et al. Clinical outcomes of adult patients with relapsed Ewing sarcoma: a 30-year single-institution experience. *Am J Clin Oncol* 2014;37:585-591. Available at: <https://www.ncbi.nlm.nih.gov/pubmed/23466580>.

271. Stahl M, Ranft A, Paulussen M, et al. Risk of recurrence and survival after relapse in patients with Ewing sarcoma. *Pediatr Blood Cancer*

2011;57:549-553. Available at: <http://www.ncbi.nlm.nih.gov/pubmed/21442722>.

272. Van Mater D, Wagner L. Management of recurrent Ewing sarcoma: challenges and approaches. *Onco Targets Ther* 2019;12:2279-2288. Available at: <https://www.ncbi.nlm.nih.gov/pubmed/30988632>.

273. Bernstein ML, Devidas M, Lafreniere D, et al. Intensive therapy with growth factor support for patients with Ewing tumor metastatic at diagnosis: Pediatric Oncology Group/Children's Cancer Group Phase II Study 9457--a report from the Children's Oncology Group. *J Clin Oncol* 2006;24:152-159. Available at: <http://www.ncbi.nlm.nih.gov/pubmed/16382125>.

274. Hunold A, Weddeling N, Paulussen M, et al. Topotecan and cyclophosphamide in patients with refractory or relapsed Ewing tumors. *Pediatr Blood Cancer* 2006;47:795-800. Available at: <http://www.ncbi.nlm.nih.gov/pubmed/16411206>.

275. Kushner BH, Kramer K, Meyers PA, et al. Pilot study of topotecan and high-dose cyclophosphamide for resistant pediatric solid tumors. *Med Pediatr Oncol* 2000;35:468-474. Available at: <http://www.ncbi.nlm.nih.gov/pubmed/11070479>.

276. Saylor RL, Stine KC, Sullivan J, et al. Cyclophosphamide plus topotecan in children with recurrent or refractory solid tumors: a Pediatric Oncology Group phase II study. *J Clin Oncol* 2001;19:3463-3469. Available at: <http://www.ncbi.nlm.nih.gov/pubmed/11481351>.

277. Casey DA, Wexler LH, Merchant MS, et al. Irinotecan and temozolomide for Ewing sarcoma: the Memorial Sloan-Kettering experience. *Pediatr Blood Cancer* 2009;53:1029-1034. Available at: <http://www.ncbi.nlm.nih.gov/pubmed/19637327>.

278. Wagner LM, Crews KR, Iacono LC, et al. Phase I trial of temozolomide and protracted irinotecan in pediatric patients with refractory solid tumors. *Clin Cancer Res* 2004;10:840-848. Available at: <http://www.ncbi.nlm.nih.gov/pubmed/14871959>.



279. Wagner LM, McAllister N, Goldsby RE, et al. Temozolomide and intravenous irinotecan for treatment of advanced Ewing sarcoma. *Pediatr Blood Cancer* 2007;48:132-139. Available at: <http://www.ncbi.nlm.nih.gov/pubmed/16317751>.

280. Raciborska A, Bilska K, Drabko K, et al. Vincristine, irinotecan, and temozolomide in patients with relapsed and refractory Ewing sarcoma. *Pediatr Blood Cancer* 2013;60:1621-1625. Available at: <http://www.ncbi.nlm.nih.gov/pubmed/23776128>.

281. van Maldegem AM, Benson C, Rutkowski P, et al. Etoposide and carbo-or cisplatin combination therapy in refractory or relapsed Ewing sarcoma: a large retrospective study. *Pediatr Blood Cancer* 2015;62:40-44. Available at: <http://www.ncbi.nlm.nih.gov/pubmed/25251256>.

282. Burdach S, Jurgens H, Peters C, et al. Myeloablative radiochemotherapy and hematopoietic stem-cell rescue in poor-prognosis Ewing's sarcoma. *J Clin Oncol* 1993;11:1482-1488. Available at: <http://www.ncbi.nlm.nih.gov/pubmed/8101562>.

283. Barker LM, Pendergrass TW, Sanders JE, Hawkins DS. Survival after recurrence of Ewing's sarcoma family of tumors. *J Clin Oncol* 2005;23:4354-4362. Available at: <http://www.ncbi.nlm.nih.gov/pubmed/15781881>.

284. McTiernan A, Driver D, Michelagnoli MP, et al. High dose chemotherapy with bone marrow or peripheral stem cell rescue is an effective treatment option for patients with relapsed or progressive Ewing's sarcoma family of tumours. *Ann Oncol* 2006;17:1301-1305. Available at: <http://www.ncbi.nlm.nih.gov/pubmed/16782749>.

285. Italiano A, Mir O, Mathoulin-Pelissier S, et al. Cabozantinib in patients with advanced Ewing sarcoma or osteosarcoma (CABONE): a multicentre, single-arm, phase 2 trial. *Lancet Oncol* 2020;21:446-455. Available at: <https://www.ncbi.nlm.nih.gov/pubmed/32078813>.

286. Navid F, Willert JR, McCarville MB, et al. Combination of gemcitabine and docetaxel in the treatment of children and young adults with refractory

bone sarcoma. *Cancer* 2008;113:419-425. Available at: <http://www.ncbi.nlm.nih.gov/pubmed/18484657>.

287. Dominkus M, Ruggieri P, Bertoni F, et al. Histologically verified lung metastases in benign giant cell tumours--14 cases from a single institution. *Int Orthop* 2006;30:499-504. Available at: <http://www.ncbi.nlm.nih.gov/pubmed/16909252>.

288. Viswanathan S, Jambhekar NA. Metastatic giant cell tumor of bone: are there associated factors and best treatment modalities? *Clin Orthop Relat Res* 2010;468:827-833. Available at: <http://www.ncbi.nlm.nih.gov/pubmed/19597900>.

289. van der Heijden L, Dijkstra PDS, Blay JY, Gelderblom H. Giant cell tumour of bone in the denosumab era. *Eur J Cancer* 2017;77:75-83. Available at: <https://www.ncbi.nlm.nih.gov/pubmed/28365529>.

290. Anract P, De Pinieux G, Cottias P, et al. Malignant giant-cell tumours of bone. Clinico-pathological types and prognosis: a review of 29 cases. *Int Orthop* 1998;22:19-26. Available at: <http://www.ncbi.nlm.nih.gov/pubmed/9549577>.

291. Bertoni F, Bacchini P, Staals EL. Malignancy in giant cell tumor of bone. *Cancer* 2003;97:2520-2529. Available at: <http://www.ncbi.nlm.nih.gov/pubmed/12733152>.

292. Purohit S, Pardiwala DN. Imaging of giant cell tumor of bone. *Indian J Orthop* 2007;41:91-96. Available at: <http://www.ncbi.nlm.nih.gov/pubmed/21139758>.

293. Thomas DM, Skubitz KM. Giant cell tumour of bone. *Curr Opin Oncol* 2009;21:338-344. Available at: <http://www.ncbi.nlm.nih.gov/pubmed/19444102>.

294. Werner M. Giant cell tumour of bone: morphological, biological and histogenetical aspects. *Int Orthop* 2006;30:484-489. Available at: <http://www.ncbi.nlm.nih.gov/pubmed/17013643>.



295. McDonald DJ, Sim FH, McLeod RA, Dahlin DC. Giant-cell tumor of bone. *J Bone Joint Surg Am* 1986;68:235-242. Available at: <http://www.ncbi.nlm.nih.gov/pubmed/3511063>.

296. Campanacci M, Baldini N, Boriani S, Sudanese A. Giant-cell tumor of bone. *J Bone Joint Surg Am* 1987;69:106-114. Available at: <http://www.ncbi.nlm.nih.gov/pubmed/3805057>.

297. Saiz P, Virkus W, Piasecki P, et al. Results of giant cell tumor of bone treated with intralesional excision. *Clin Orthop Relat Res* 2004:221-226. Available at: <http://www.ncbi.nlm.nih.gov/pubmed/15241169>.

298. Malek F, Krueger P, Hatmi ZN, et al. Local control of long bone giant cell tumour using curettage, burring and bone grafting without adjuvant therapy. *Int Orthop* 2006;30:495-498. Available at: <http://www.ncbi.nlm.nih.gov/pubmed/16896875>.

299. Kivioja AH, Blomqvist C, Hietaniemi K, et al. Cement is recommended in intralesional surgery of giant cell tumors: a Scandinavian Sarcoma Group study of 294 patients followed for a median time of 5 years. *Acta Orthop* 2008;79:86-93. Available at: <http://www.ncbi.nlm.nih.gov/pubmed/18283578>.

300. Errani C, Ruggieri P, Asenzio MA, et al. Giant cell tumor of the extremity: A review of 349 cases from a single institution. *Cancer Treat Rev* 2010;36:1-7. Available at: <http://www.ncbi.nlm.nih.gov/pubmed/19879054>.

301. Klenke FM, Wenger DE, Inwards CY, et al. Giant cell tumor of bone: risk factors for recurrence. *Clin Orthop Relat Res* 2011;469:591-599. Available at: <http://www.ncbi.nlm.nih.gov/pubmed/20706812>.

302. O'Donnell RJ, Springfield DS, Motwani HK, et al. Recurrence of giant-cell tumors of the long bones after curettage and packing with cement. *J Bone Joint Surg Am* 1994;76:1827-1833. Available at: <http://www.ncbi.nlm.nih.gov/pubmed/7989388>.

303. Blackley HR, Wunder JS, Davis AM, et al. Treatment of giant-cell tumors of long bones with curettage and bone-grafting. *J Bone Joint Surg*

Am 1999;81:811-820. Available at: <http://www.ncbi.nlm.nih.gov/pubmed/10391546>.

304. Prosser GH, Baloch KG, Tillman RM, et al. Does curettage without adjuvant therapy provide low recurrence rates in giant-cell tumors of bone? *Clin Orthop Relat Res* 2005:211-218. Available at: <http://www.ncbi.nlm.nih.gov/pubmed/15930941>.

305. Becker WT, Dohle J, Bernd L, et al. Local recurrence of giant cell tumor of bone after intralesional treatment with and without adjuvant therapy. *J Bone Joint Surg Am* 2008;90:1060-1067. Available at: <http://www.ncbi.nlm.nih.gov/pubmed/18451399>.

306. Balke M, Schremper L, Gebert C, et al. Giant cell tumor of bone: treatment and outcome of 214 cases. *J Cancer Res Clin Oncol* 2008;134:969-978. Available at: <http://www.ncbi.nlm.nih.gov/pubmed/18322700>.

307. Pietschmann MF, Dietz RA, Utschneider S, et al. The influence of adjuvants on local recurrence rate in giant cell tumour of the bone. *Acta Chir Belg* 2010;110:584-589. Available at: <http://www.ncbi.nlm.nih.gov/pubmed/21337837>.

308. Klenke FM, Wenger DE, Inwards CY, et al. Recurrent giant cell tumor of long bones: analysis of surgical management. *Clin Orthop Relat Res* 2011;469:1181-1187. Available at: <http://www.ncbi.nlm.nih.gov/pubmed/20857250>.

309. Trieb K, Bitzan P, Lang S, et al. Recurrence of curetted and bone-grafted giant-cell tumours with and without adjuvant phenol therapy. *Eur J Surg Oncol* 2001;27:200-202. Available at: <http://www.ncbi.nlm.nih.gov/pubmed/11289759>.

310. Turcotte RE, Wunder JS, Isler MH, et al. Giant cell tumor of long bone: a Canadian Sarcoma Group study. *Clin Orthop Relat Res* 2002:248-258. Available at: <http://www.ncbi.nlm.nih.gov/pubmed/11953616>.

311. Oda Y, Miura H, Tsuneyoshi M, Iwamoto Y. Giant cell tumor of bone: oncological and functional results of long-term follow-up. *Jpn J Clin Oncol*



1998;28:323-328. Available at:

<http://www.ncbi.nlm.nih.gov/pubmed/9703860>.

312. Boons HW, Keijser LC, Schreuder HW, et al. Oncologic and functional results after treatment of giant cell tumors of bone. Arch Orthop Trauma Surg 2002;122:17-23. Available at:

<http://www.ncbi.nlm.nih.gov/pubmed/11995874>.

313. Su YP, Chen WM, Chen TH. Giant-cell tumors of bone: an analysis of 87 cases. Int Orthop 2004;28:239-243. Available at:

<http://www.ncbi.nlm.nih.gov/pubmed/15160253>.

314. Rastogi S, Prashanth I, Khan SA, et al. Giant cell tumor of bone: Is curettage the answer? Indian J Orthop 2007;41:109-114. Available at:

<http://www.ncbi.nlm.nih.gov/pubmed/21139761>.

315. Guo W, Sun X, Zang J, Qu H. Intralesional excision versus wide resection for giant cell tumor involving the acetabulum: which is better? Clin Orthop Relat Res 2012;470:1213-1220. Available at:

<http://www.ncbi.nlm.nih.gov/pubmed/22125245>.

316. Labs K, Perka C, Schmidt RG. Treatment of stages 2 and 3 giant-cell tumor. Arch Orthop Trauma Surg 2001;121:83-86. Available at:

<http://www.ncbi.nlm.nih.gov/pubmed/11195127>.

317. Mankin HJ, Hornicek FJ. Treatment of giant cell tumors with allograft transplants: a 30-year study. Clin Orthop Relat Res 2005;439:144-150.

Available at: <http://www.ncbi.nlm.nih.gov/pubmed/16205153>.

318. Mendenhall WM, Zlotecki RA, Scarborough MT, et al. Giant cell tumor of bone. Am J Clin Oncol 2006;29:96-99. Available at:

<http://www.ncbi.nlm.nih.gov/pubmed/16462511>.

319. Saini R, Bali K, Bachhal V, et al. En bloc excision and autogenous fibular reconstruction for aggressive giant cell tumor of distal radius: a report of 12 cases and review of literature. J Orthop Surg Res 2011;6:14.

Available at: <http://www.ncbi.nlm.nih.gov/pubmed/21385393>.

320. Dahlin DC. Caldwell Lecture. Giant cell tumor of bone: highlights of 407 cases. AJR Am J Roentgenol 1985;144:955-960. Available at:

<http://www.ncbi.nlm.nih.gov/pubmed/3872579>.

321. Schwartz LH, Okunieff PG, Rosenberg A, Suit HD. Radiation therapy in the treatment of difficult giant cell tumors. Int J Radiat Oncol Biol Phys 1989;17:1085-1088. Available at:

<http://www.ncbi.nlm.nih.gov/pubmed/2808042>.

322. Bennett CJ, Marcus RB, Million RR, Enneking WF. Radiation therapy for giant cell tumor of bone. Int J Radiat Oncol Biol Phys 1993;26:299-304.

Available at: <http://www.ncbi.nlm.nih.gov/pubmed/8491687>.

323. Malone S, O'Sullivan B, Catton C, et al. Long-term follow-up of efficacy and safety of megavoltage radiotherapy in high-risk giant cell tumors of bone. Int J Radiat Oncol Biol Phys 1995;33:689-694. Available at:

<http://www.ncbi.nlm.nih.gov/pubmed/7558960>.

324. Chakravarti A, Spiro IJ, Hug EB, et al. Megavoltage radiation therapy for axial and inoperable giant-cell tumor of bone. J Bone Joint Surg Am 1999;81:1566-1573. Available at:

<http://www.ncbi.nlm.nih.gov/pubmed/10565648>.

325. Nair MK, Jyothirmayi R. Radiation therapy in the treatment of giant cell tumor of bone. Int J Radiat Oncol Biol Phys 1999;43:1065-1069.

Available at: <http://www.ncbi.nlm.nih.gov/pubmed/10192357>.

326. Miszczyk L, Wydmanski J, Spindel J. Efficacy of radiotherapy for giant cell tumor of bone: given either postoperatively or as sole treatment. Int J Radiat Oncol Biol Phys 2001;49:1239-1242. Available at:

<http://www.ncbi.nlm.nih.gov/pubmed/11286829>.

327. Caudell JJ, Ballo MT, Zagars GK, et al. Radiotherapy in the management of giant cell tumor of bone. Int J Radiat Oncol Biol Phys 2003;57:158-165. Available at:

<http://www.ncbi.nlm.nih.gov/pubmed/12909228>.



328. Feigenberg SJ, Marcus Jr RB, Zlotecki RA, et al. Radiation therapy for giant cell tumors of bone. *Clin Orthop Relat Res* 2003;207-216.

Available at: <http://www.ncbi.nlm.nih.gov/pubmed/12782877>.

329. Ruka W, Rutkowski P, Morysinski T, et al. The megavoltage radiation therapy in treatment of patients with advanced or difficult giant cell tumors of bone. *Int J Radiat Oncol Biol Phys* 2010;78:494-498. Available at:

<http://www.ncbi.nlm.nih.gov/pubmed/20004531>.

330. Bhatia S, Mischczyk L, Roelandts M, et al. Radiotherapy for marginally resected, unresectable or recurrent giant cell tumor of the bone: a rare cancer network study. *Rare Tumors* 2011;3. Available at:

<http://www.ncbi.nlm.nih.gov/pubmed/22355503>.

331. Ma Y, Xu W, Yin H, et al. Therapeutic radiotherapy for giant cell tumor of the spine: a systemic review. *Eur Spine J* 2015;24:1754-1760.

Available at: <https://www.ncbi.nlm.nih.gov/pubmed/25943724>.

332. Hug EB, Muentner MW, Adams JA, et al. 3-D-conformal radiation therapy for pediatric giant cell tumors of the skull base. *Strahlenther Onkol* 2002;178:239-244. Available at:

<http://www.ncbi.nlm.nih.gov/pubmed/12082682>.

333. Roeder F, Timke C, Zwicker F, et al. Intensity modulated radiotherapy (IMRT) in benign giant cell tumors--a single institution case series and a short review of the literature. *Radiat Oncol* 2010;5:18.

Available at: <http://www.ncbi.nlm.nih.gov/pubmed/20187955>.

334. Thomas D, Henshaw R, Skubitz K, et al. Denosumab in patients with giant-cell tumour of bone: an open-label, phase 2 study. *Lancet Oncol* 2010;11:275-280. Available at:

<http://www.ncbi.nlm.nih.gov/pubmed/20149736>.

335. Branstetter DG, Nelson SD, Manivel JC, et al. Denosumab induces tumor reduction and bone formation in patients with giant-cell tumor of bone. *Clin Cancer Res* 2012;18:4415-4424. Available at:

<http://www.ncbi.nlm.nih.gov/pubmed/22711702>.

336. Chawla S, Henshaw R, Seeger L, et al. Safety and efficacy of denosumab for adults and skeletally mature adolescents with giant cell tumour of bone: interim analysis of an open-label, parallel-group, phase 2 study. *Lancet Oncol* 2013;14:901-908. Available at:

<http://www.ncbi.nlm.nih.gov/pubmed/23867211>.

337. Ueda T, Morioka H, Nishida Y, et al. Objective tumor response to denosumab in patients with giant cell tumor of bone: a multicenter phase II trial. *Ann Oncol* 2015;26:2149-2154. Available at:

<https://www.ncbi.nlm.nih.gov/pubmed/26205395>.

338. Rutkowski P, Ferrari S, Grimer RJ, et al. Surgical downstaging in an open-label phase II trial of denosumab in patients with giant cell tumor of bone. *Ann Surg Oncol* 2015;22:2860-2868. Available at:

<https://www.ncbi.nlm.nih.gov/pubmed/26033180>.

339. Martin-Broto J, Cleeland CS, Glare PA, et al. Effects of denosumab on pain and analgesic use in giant cell tumor of bone: interim results from a phase II study. *Acta Oncol* 2014;53:1173-1179. Available at:

<https://www.ncbi.nlm.nih.gov/pubmed/24834795>.

340. Errani C, Tsukamoto S, Leone G, et al. Denosumab May Increase the Risk of Local Recurrence in Patients with Giant-Cell Tumor of Bone Treated with Curettage. *J Bone Joint Surg Am* 2018;100:496-504.

Available at: <https://www.ncbi.nlm.nih.gov/pubmed/29557866>.

341. Scoccianti G, Totti F, Scoranz M, et al. Preoperative Denosumab With Curettage and Cryotherapy in Giant Cell Tumor of Bone: Is There an Increased Risk of Local Recurrence? *Clin Orthop Relat Res* 2018;476:1783-1790. Available at:

<https://www.ncbi.nlm.nih.gov/pubmed/30778015>.

342. Muller DA, Beltrami G, Scoccianti G, et al. Risks and benefits of combining denosumab and surgery in giant cell tumor of bone-a case series. *World J Surg Oncol* 2016;14:281. Available at:

<https://www.ncbi.nlm.nih.gov/pubmed/27809843>.

343. Engellau J, Seeger L, Grimer R, et al. Assessment of denosumab treatment effects and imaging response in patients with giant cell tumor of



bone. World J Surg Oncol 2018;16:191. Available at:
<https://www.ncbi.nlm.nih.gov/pubmed/30231890>.

344. Aponte-Tinao LA, Piuze NS, Roitman P, Farfalli GL. A High-grade Sarcoma Arising in a Patient With Recurrent Benign Giant Cell Tumor of the Proximal Tibia While Receiving Treatment With Denosumab. Clin Orthop Relat Res 2015;473:3050-3055. Available at:
<https://www.ncbi.nlm.nih.gov/pubmed/25758379>.

345. Broehm CJ, Garbrecht EL, Wood J, Bocklage T. Two Cases of Sarcoma Arising in Giant Cell Tumor of Bone Treated with Denosumab. Case Rep Med 2015;2015:767198. Available at:
<https://www.ncbi.nlm.nih.gov/pubmed/26798348>.

346. Lin PP, Guzel VB, Moura MF, et al. Long-term follow-up of patients with giant cell tumor of the sacrum treated with selective arterial embolization. Cancer 2002;95:1317-1325. Available at:
<http://www.ncbi.nlm.nih.gov/pubmed/12216101>.

347. Hosalkar HS, Jones KJ, King JJ, Lackman RD. Serial arterial embolization for large sacral giant-cell tumors: mid- to long-term results. Spine (Phila Pa 1976) 2007;32:1107-1115. Available at:
<http://www.ncbi.nlm.nih.gov/pubmed/17471094>.

348. Onishi H, Kaya M, Wada T, et al. Giant cell tumor of the sacrum treated with selective arterial embolization. Int J Clin Oncol 2010;15:416-419. Available at: <http://www.ncbi.nlm.nih.gov/pubmed/20198397>.

349. Emori M, Kaya M, Sasaki M, et al. Pre-operative Selective Arterial Embolization as a Neoadjuvant Therapy for Proximal Humerus Giant Cell Tumor of Bone: Radiological and Histological Evaluation. Jpn J Clin Oncol 2012;42:851-855. Available at:
<http://www.ncbi.nlm.nih.gov/pubmed/22689917>.

350. Kaiser U, Neumann K, Havemann K. Generalised giant-cell tumour of bone: successful treatment of pulmonary metastases with interferon alpha, a case report. J Cancer Res Clin Oncol 1993;119:301-303. Available at:
<http://www.ncbi.nlm.nih.gov/pubmed/8440744>.

351. Yasko AW. Interferon therapy for giant cell tumor of bone. Current Opinion in Orthopaedics 2006;17:568-572 Available at:
http://journals.lww.com/co-ortho/Fulltext/2006/12000/Interferon_therapy_for_giant_cell_tumor_of_bone.17.aspx.

352. Kaban LB, Troulis MJ, Wilkinson MS, et al. Adjuvant antiangiogenic therapy for giant cell tumors of the jaws. J Oral Maxillofac Surg 2007;65:2018-2024; discussion 2024. Available at:
<http://www.ncbi.nlm.nih.gov/pubmed/17884531>.

353. Wei F, Liu X, Liu Z, et al. Interferon alfa-2b for recurrent and metastatic giant cell tumor of the spine: report of two cases. Spine (Phila Pa 1976) 2010;35:E1418-1422. Available at:
<http://www.ncbi.nlm.nih.gov/pubmed/21030898>.

354. Cheng JC, Johnston JO. Giant cell tumor of bone. Prognosis and treatment of pulmonary metastases. Clin Orthop Relat Res 1997:205-214. Available at: <http://www.ncbi.nlm.nih.gov/pubmed/9170381>.

355. Siebenrock KA, Unni KK, Rock MG. Giant-cell tumour of bone metastasising to the lungs. A long-term follow-up. J Bone Joint Surg Br 1998;80:43-47. Available at:
<http://www.ncbi.nlm.nih.gov/pubmed/9460951>.

356. Klein MJ, Siegal GP. Osteosarcoma: anatomic and histologic variants. Am J Clin Pathol 2006;125:555-581. Available at:
<http://www.ncbi.nlm.nih.gov/pubmed/16627266>.

357. Antonescu CR, Huvos AG. Low-grade osteogenic sarcoma arising in medullary and surface osseous locations. Am J Clin Pathol 2000;114 Suppl:S90-103. Available at:
<http://www.ncbi.nlm.nih.gov/pubmed/11996175>.

358. Sheth DS, Yasko AW, Raymond AK, et al. Conventional and dedifferentiated parosteal osteosarcoma. Diagnosis, treatment, and outcome. Cancer 1996;78:2136-2145. Available at:
<http://www.ncbi.nlm.nih.gov/pubmed/8918422>.



359. Bertoni F, Bacchini P, Staals EL, Davidovitz P. Dedifferentiated parosteal osteosarcoma: the experience of the Rizzoli Institute. *Cancer* 2005;103:2373-2382. Available at: <http://www.ncbi.nlm.nih.gov/pubmed/15852358>.

360. Okada K, Unni KK, Swee RG, Sim FH. High grade surface osteosarcoma: a clinicopathologic study of 46 cases. *Cancer* 1999;85:1044-1054. Available at: <http://www.ncbi.nlm.nih.gov/pubmed/10091787>.

361. Staals EL, Bacchini P, Bertoni F. High-grade surface osteosarcoma: a review of 25 cases from the Rizzoli Institute. *Cancer* 2008;112:1592-1599. Available at: <http://www.ncbi.nlm.nih.gov/pubmed/18300258>.

362. Davis AM, Bell RS, Goodwin PJ. Prognostic factors in osteosarcoma: a critical review. *J Clin Oncol* 1994;12:423-431. Available at: <http://www.ncbi.nlm.nih.gov/pubmed/8113851>.

363. Ferrari S, Bertoni F, Mercuri M, et al. Predictive factors of disease-free survival for non-metastatic osteosarcoma of the extremity: an analysis of 300 patients treated at the Rizzoli Institute. *Ann Oncol* 2001;12:1145-1150. Available at: <http://www.ncbi.nlm.nih.gov/pubmed/11583198>.

364. Bielack SS, Kempf-Bielack B, Delling G, et al. Prognostic factors in high-grade osteosarcoma of the extremities or trunk: an analysis of 1,702 patients treated on neoadjuvant cooperative osteosarcoma study group protocols. *J Clin Oncol* 2002;20:776-790. Available at: <http://www.ncbi.nlm.nih.gov/pubmed/11821461>.

365. Bacci G, Longhi A, Ferrari S, et al. Prognostic significance of serum lactate dehydrogenase in osteosarcoma of the extremity: experience at Rizzoli on 1421 patients treated over the last 30 years. *Tumori* 2004;90:478-484. Available at: <http://www.ncbi.nlm.nih.gov/pubmed/15656333>.

366. Bacci G, Longhi A, Versari M, et al. Prognostic factors for osteosarcoma of the extremity treated with neoadjuvant chemotherapy: 15-year experience in 789 patients treated at a single institution. *Cancer*

2006;106:1154-1161. Available at: <http://www.ncbi.nlm.nih.gov/pubmed/16421923>.

367. Whelan JS, Jinks RC, McTiernan A, et al. Survival from high-grade localised extremity osteosarcoma: combined results and prognostic factors from three European Osteosarcoma Intergroup randomised controlled trials. *Ann Oncol* 2012;23:1607-1616. Available at: <http://www.ncbi.nlm.nih.gov/pubmed/22015453>.

368. Ogura K, Fujiwara T, Yasunaga H, et al. Development and external validation of nomograms predicting distant metastases and overall survival after neoadjuvant chemotherapy and surgery for patients with nonmetastatic osteosarcoma: A multi-institutional study. *Cancer* 2015;121:3844-3852. Available at: <https://www.ncbi.nlm.nih.gov/pubmed/26194185>.

369. Bertrand TE, Cruz A, Binitie O, et al. Do Surgical Margins Affect Local Recurrence and Survival in Extremity, Nonmetastatic, High-grade Osteosarcoma? *Clin Orthop Relat Res* 2016;474:677-683. Available at: <https://www.ncbi.nlm.nih.gov/pubmed/26013153>.

370. Lee RJ, Arshi A, Schwartz HC, Christensen RE. Characteristics and prognostic factors of osteosarcoma of the jaws: a retrospective cohort study. *JAMA Otolaryngol Head Neck Surg* 2015;141:470-477. Available at: <https://www.ncbi.nlm.nih.gov/pubmed/25811167>.

371. Collins M, Wilhelm M, Conyers R, et al. Benefits and adverse events in younger versus older patients receiving neoadjuvant chemotherapy for osteosarcoma: findings from a meta-analysis. *J Clin Oncol* 2013;31:2303-2312. Available at: <http://www.ncbi.nlm.nih.gov/pubmed/23669227>.

372. Altaf S, Enders F, Jeavons E, et al. High-BMI at diagnosis is associated with inferior survival in patients with osteosarcoma: a report from the Children's Oncology Group. *Pediatr Blood Cancer* 2013;60:2042-2046. Available at: <http://www.ncbi.nlm.nih.gov/pubmed/23955975>.

373. Bacci G, Briccoli A, Ferrari S, et al. Neoadjuvant chemotherapy for osteosarcoma of the extremities with synchronous lung metastases: treatment with cisplatin, adriamycin and high dose of methotrexate and



ifosfamide. *Oncol Rep* 2000;7:339-346. Available at:
<http://www.ncbi.nlm.nih.gov/pubmed/10671683>.

374. Daw NC, Billups CA, Rodriguez-Galindo C, et al. Metastatic osteosarcoma. *Cancer* 2006;106:403-412. Available at:
<http://www.ncbi.nlm.nih.gov/pubmed/16353204>.

375. Fu Y, Lan T, Cai H, et al. Meta-analysis of serum lactate dehydrogenase and prognosis for osteosarcoma. *Medicine (Baltimore)* 2018;97:e0741. Available at:
<https://www.ncbi.nlm.nih.gov/pubmed/29742740>.

376. Gu R, Sun Y. Does serum alkaline phosphatase level really indicate the prognosis in patients with osteosarcoma? A meta-analysis. *J Cancer Res Ther* 2018;14:S468-S472. Available at:
<https://www.ncbi.nlm.nih.gov/pubmed/29970708>.

377. Lambertini M, Del Mastro L, Pescio MC, et al. Cancer and fertility preservation: international recommendations from an expert meeting. *BMC Med* 2016;14:1. Available at:
<https://www.ncbi.nlm.nih.gov/pubmed/26728489>.

378. Practice Committee of the American Society for Reproductive Medicine. Electronic address aao. Fertility preservation in patients undergoing gonadotoxic therapy or gonadectomy: a committee opinion. *Fertil Steril* 2019;112:1022-1033. Available at:
<https://www.ncbi.nlm.nih.gov/pubmed/31843073>.

379. Sun J, Xu H, Qi M, et al. Identification of key genes in osteosarcoma by metaanalysis of gene expression microarray. *Mol Med Rep* 2019;20:3075-3084. Available at:
<https://www.ncbi.nlm.nih.gov/pubmed/31432118>.

380. Marulanda GA, Henderson ER, Johnson DA, et al. Orthopedic surgery options for the treatment of primary osteosarcoma. *Cancer Control* 2008;15:13-20. Available at:
<http://www.ncbi.nlm.nih.gov/pubmed18094657>.

381. Bacci G, Ferrari S, Lari S, et al. Osteosarcoma of the limb. Amputation or limb salvage in patients treated by neoadjuvant chemotherapy. *J Bone Joint Surg Br* 2002;84:88-92. Available at:
<http://www.ncbi.nlm.nih.gov/pubmed/11837839>.

382. Mavrogenis AF, Abati CN, Romagnoli C, Ruggieri P. Similar survival but better function for patients after limb salvage versus amputation for distal tibia osteosarcoma. *Clin Orthop Relat Res* 2012;470:1735-1748. Available at: <http://www.ncbi.nlm.nih.gov/pubmed/22270466>.

383. Simon MA, Aschliman MA, Thomas N, Mankin HJ. Limb-salvage treatment versus amputation for osteosarcoma of the distal end of the femur. 1986. *J Bone Joint Surg Am* 2005;87:2822-2822. Available at:
<http://www.ncbi.nlm.nih.gov/pubmed16322634>.

384. Aksnes LH, Bauer HCF, Jebsen NL, et al. Limb-sparing surgery preserves more function than amputation: a Scandinavian sarcoma group study of 118 patients. *J Bone Joint Surg Br* 2008;90:786-794. Available at:
<http://www.ncbi.nlm.nih.gov/pubmed18539673>.

385. Nagarajan R, Neglia JP, Clohisy DR, Robison LL. Limb salvage and amputation in survivors of pediatric lower-extremity bone tumors: what are the long-term implications? *J Clin Oncol* 2002;20:4493-4501. Available at:
<http://www.ncbi.nlm.nih.gov/pubmed12431974>.

386. Winkler K, Beron G, Kotz R, et al. Neoadjuvant chemotherapy for osteogenic sarcoma: results of a Cooperative German/Austrian study. *J Clin Oncol* 1984;2:617-624. Available at:
<http://www.ncbi.nlm.nih.gov/pubmed/6202851>.

387. Link MP, Goorin AM, Miser AW, et al. The effect of adjuvant chemotherapy on relapse-free survival in patients with osteosarcoma of the extremity. *N Engl J Med* 1986;314:1600-1606. Available at:
<http://www.ncbi.nlm.nih.gov/pubmed/3520317>.

388. Eilber F, Giuliano A, Eckardt J, et al. Adjuvant chemotherapy for osteosarcoma: a randomized prospective trial. *J Clin Oncol* 1987;5:21-26. Available at: <http://www.ncbi.nlm.nih.gov/pubmed/3543236>.



389. Link MP, Goorin AM, Horowitz M, et al. Adjuvant chemotherapy of high-grade osteosarcoma of the extremity. Updated results of the Multi-Institutional Osteosarcoma Study. *Clin Orthop Relat Res* 1991;8-14. Available at: <http://www.ncbi.nlm.nih.gov/pubmed/1884563>.

390. Meyers PA, Heller G, Healey J, et al. Chemotherapy for nonmetastatic osteogenic sarcoma: the Memorial Sloan-Kettering experience. *J Clin Oncol* 1992;10:5-15. Available at: <http://www.ncbi.nlm.nih.gov/pubmed/1370176>.

391. Goorin AM, Schwartzenuber DJ, Devidas M, et al. Presurgical chemotherapy compared with immediate surgery and adjuvant chemotherapy for nonmetastatic osteosarcoma: Pediatric Oncology Group Study POG-8651. *J Clin Oncol* 2003;21:1574-1580. Available at: <http://www.ncbi.nlm.nih.gov/pubmed/12697883>.

392. Bramwell V, Burgers M, Sneath R, et al. A comparison of two short intensive adjuvant chemotherapy regimens in operable osteosarcoma of limbs in children and young adults: the first study of the European Osteosarcoma Intergroup. *J Clin Oncol* 1992;10:1579-1591. Available at: <http://www.ncbi.nlm.nih.gov/pubmed/1403038>.

393. Souhami RL, Craft AW, Van der Eijken JW, et al. Randomised trial of two regimens of chemotherapy in operable osteosarcoma: a study of the European Osteosarcoma Intergroup. *Lancet* 1997;350:911-917. Available at: <http://www.ncbi.nlm.nih.gov/pubmed/9314869>.

394. Fuchs N, Bielack SS, Epler D, et al. Long-term results of the cooperative German-Austrian-Swiss osteosarcoma study group's protocol COSS-86 of intensive multidrug chemotherapy and surgery for osteosarcoma of the limbs. *Ann Oncol* 1998;9:893-899. Available at: <http://www.ncbi.nlm.nih.gov/pubmed/9789613>.

395. Bacci G, Ferrari S, Bertoni F, et al. Long-term outcome for patients with nonmetastatic osteosarcoma of the extremity treated at the istituto ortopedico rizzoli according to the istituto ortopedico rizzoli/osteosarcoma-2 protocol: an updated report. *J Clin Oncol* 2000;18:4016-4027. Available at: <http://www.ncbi.nlm.nih.gov/pubmed/11118462>.

396. Bacci G, Briccoli A, Ferrari S, et al. Neoadjuvant chemotherapy for osteosarcoma of the extremity: long-term results of the Rizzoli's 4th protocol. *Eur J Cancer* 2001;37:2030-2039. Available at: <http://www.ncbi.nlm.nih.gov/pubmed/11597381>.

397. Ferrari S, Smeland S, Mercuri M, et al. Neoadjuvant chemotherapy with high-dose ifosfamide, high-dose methotrexate, cisplatin, and doxorubicin for patients with localized osteosarcoma of the extremity: a joint study by the Italian and Scandinavian Sarcoma Groups. *J Clin Oncol* 2005;23:8845-8852. Available at: <http://www.ncbi.nlm.nih.gov/pubmed/16246977>.

398. Lewis IJ, Nooij MA, Whelan J, et al. Improvement in histologic response but not survival in osteosarcoma patients treated with intensified chemotherapy: a randomized phase III trial of the European Osteosarcoma Intergroup. *J Natl Cancer Inst* 2007;99:112-128. Available at: <http://www.ncbi.nlm.nih.gov/pubmed/17227995>.

399. Meyers PA, Schwartz CL, Krailo MD, et al. Osteosarcoma: the addition of muramyl tripeptide to chemotherapy improves overall survival--a report from the Children's Oncology Group. *J Clin Oncol* 2008;26:633-638. Available at: <http://www.ncbi.nlm.nih.gov/pubmed/18235123>.

400. Basaran M, Bavbek ES, Saglam S, et al. A phase II study of cisplatin, ifosfamide and epirubicin combination chemotherapy in adults with nonmetastatic and extremity osteosarcomas. *Oncology* 2007;72:255-260. Available at: <http://www.ncbi.nlm.nih.gov/pubmed/18185020>.

401. Le Deley MC, Guinebreiere JM, Gentet JC, et al. SFOP OS94: a randomised trial comparing preoperative high-dose methotrexate plus doxorubicin to high-dose methotrexate plus etoposide and ifosfamide in osteosarcoma patients. *Eur J Cancer* 2007;43:752-761. Available at: <http://www.ncbi.nlm.nih.gov/pubmed/17267204>.

402. Provisor AJ, Ettinger LJ, Nachman JB, et al. Treatment of nonmetastatic osteosarcoma of the extremity with preoperative and postoperative chemotherapy: a report from the Children's Cancer Group. *J Clin Oncol* 1997;15:76-84. Available at: <http://www.ncbi.nlm.nih.gov/pubmed/8996127>.



403. Bernthal NM, Federman N, Eilber FR, et al. Long-term results (>25 years) of a randomized, prospective clinical trial evaluating chemotherapy in patients with high-grade, operable osteosarcoma. *Cancer* 2012;118:5888-5893. Available at:

<http://www.ncbi.nlm.nih.gov/pubmed/22648705>.

404. Bacci G, Mercuri M, Longhi A, et al. Grade of chemotherapy-induced necrosis as a predictor of local and systemic control in 881 patients with non-metastatic osteosarcoma of the extremities treated with neoadjuvant chemotherapy in a single institution. *Eur J Cancer* 2005;41:2079-2085. Available at:

<http://www.ncbi.nlm.nih.gov/pubmed/16115755>.

405. Cesari M, Alberghini M, Vanel D, et al. Periosteal osteosarcoma: a single-institution experience. *Cancer* 2011;117:1731-1735. Available at:

<http://www.ncbi.nlm.nih.gov/pubmed/21472720>.

406. Grimer RJ, Bielack S, Flege S, et al. Periosteal osteosarcoma--a European review of outcome. *Eur J Cancer* 2005;41:2806-2811. Available at:

<http://www.ncbi.nlm.nih.gov/pubmed/16290134>.

407. Bacci G, Ferrari S, Tienghi A, et al. A comparison of methods of loco-regional chemotherapy combined with systemic chemotherapy as neoadjuvant treatment of osteosarcoma of the extremity. *Eur J Surg Oncol* 2001;27:98-9104. Available at:

<http://www.ncbi.nlm.nih.gov/pubmed/11237499>.

408. Guadagnolo BA, Zagars GK, Raymond AK, et al. Osteosarcoma of the jaw/craniofacial region: outcomes after multimodality treatment. *Cancer* 2009;115:3262-3270. Available at:

<http://www.ncbi.nlm.nih.gov/pubmed/19382187>.

409. Ciernik IF, Niemierko A, Harmon DC, et al. Proton-based radiotherapy for unresectable or incompletely resected osteosarcoma. *Cancer* 2011;117:4522-4530. Available at:

<http://www.ncbi.nlm.nih.gov/pubmed/21448934>.

410. DeLaney TF, Park L, Goldberg SI, et al. Radiotherapy for local control of osteosarcoma. *Int J Radiat Oncol Biol Phys* 2005;61:492-498. Available at:

<http://www.ncbi.nlm.nih.gov/pubmed/15667972>.

411. Winkler K, Beron G, Delling G, et al. Neoadjuvant chemotherapy of osteosarcoma: results of a randomized cooperative trial (COSS-82) with salvage chemotherapy based on histological tumor response. *J Clin Oncol* 1988;6:329-337. Available at:

<http://www.ncbi.nlm.nih.gov/pubmed/2448428>.

412. Marina NM, Smeland S, Bielack SS, et al. Comparison of MAPIE versus MAP in patients with a poor response to preoperative chemotherapy for newly diagnosed high-grade osteosarcoma (EURAMOS-1): an open-label, international, randomised controlled trial. *Lancet Oncol* 2016;17:1396-1408. Available at:

<https://www.ncbi.nlm.nih.gov/pubmed/27569442>.

413. Smeland S, Muller C, Alvegard TA, et al. Scandinavian Sarcoma Group Osteosarcoma Study SSG VIII: prognostic factors for outcome and the role of replacement salvage chemotherapy for poor histological responders. *Eur J Cancer* 2003;39:488-494. Available at:

<http://www.ncbi.nlm.nih.gov/pubmed/12751380>.

414. Smeland S, Bruland OS, Hjorth L, et al. Results of the Scandinavian Sarcoma Group XIV protocol for classical osteosarcoma: 63 patients with a minimum follow-up of 4 years. *Acta Orthop* 2011;82:211-216. Available at:

<http://www.ncbi.nlm.nih.gov/pubmed/21434784>.

415. Ferrari S, Ruggieri P, Cefalo G, et al. Neoadjuvant chemotherapy with methotrexate, cisplatin, and doxorubicin with or without ifosfamide in nonmetastatic osteosarcoma of the extremity: An Italian Sarcoma Group trial ISG/OS-1. *J Clin Oncol* 2012;30:2112-2118. Available at:

<http://www.ncbi.nlm.nih.gov/pubmed/22564997>.

416. Bielack SS, Smeland S, Whelan JS, et al. Methotrexate, doxorubicin, and cisplatin (MAP) plus maintenance pegylated interferon alfa-2b versus MAP alone in patients with resectable high-grade osteosarcoma and good histologic response to preoperative MAP: first results of the EURAMOS-1 good response randomized controlled trial. *J Clin Oncol* 2015;33:2279-2287. Available at:

<http://www.ncbi.nlm.nih.gov/pubmed/26033801>.

417. Meyers PA, Heller G, Healey JH, et al. Osteogenic sarcoma with clinically detectable metastasis at initial presentation. *J Clin Oncol*



1993;11:449-453. Available at:

<http://www.ncbi.nlm.nih.gov/pubmed/8445419>.

418. Bacci G, Briccoli A, Mercuri M, et al. Osteosarcoma of the extremities with synchronous lung metastases: long-term results in 44 patients treated with neoadjuvant chemotherapy. *J Chemother* 1998;10:69-76. Available at: <http://www.ncbi.nlm.nih.gov/pubmed/9531078>.

419. Bacci G, Briccoli A, Rocca M, et al. Neoadjuvant chemotherapy for osteosarcoma of the extremities with metastases at presentation: recent experience at the Rizzoli Institute in 57 patients treated with cisplatin, doxorubicin, and a high dose of methotrexate and ifosfamide. *Ann Oncol* 2003;14:1126-1134. Available at: <http://www.ncbi.nlm.nih.gov/pubmed/12853357>.

420. Smeland S, Bielack SS, Whelan J, et al. Survival and prognosis with osteosarcoma: outcomes in more than 2000 patients in the EURAMOS-1 (European and American Osteosarcoma Study) cohort. *Eur J Cancer* 2019;109:36-50. Available at: <https://www.ncbi.nlm.nih.gov/pubmed/30685685>.

421. Goorin AM, Harris MB, Bernstein M, et al. Phase II/III trial of etoposide and high-dose ifosfamide in newly diagnosed metastatic osteosarcoma: a pediatric oncology group trial. *J Clin Oncol* 2002;20:426-433. Available at: <http://www.ncbi.nlm.nih.gov/pubmed/11786570>.

422. Winkler K, Torggler S, Beron G, et al. [Results of treatment in primary disseminated osteosarcoma. Analysis of the follow-up of patients in the cooperative osteosarcoma studies COSS-80 and COSS-82]. *Onkologie* 1989;12:92-96. Available at: <http://www.ncbi.nlm.nih.gov/pubmed/2660050>.

423. Bacci G, Mercuri M, Briccoli A, et al. Osteogenic sarcoma of the extremity with detectable lung metastases at presentation. Results of treatment of 23 patients with chemotherapy followed by simultaneous resection of primary and metastatic lesions. *Cancer* 1997;79:245-254. Available at: <http://www.ncbi.nlm.nih.gov/pubmed/9010097>.

424. Mehta N, Selch M, Wang PC, et al. Safety and efficacy of stereotactic body radiation therapy in the treatment of pulmonary metastases from high grade sarcoma. *Sarcoma* 2013;2013:360214. Available at: <https://www.ncbi.nlm.nih.gov/pubmed/24198717>.

425. Baumann BC, Nagda SN, Kolker JD, et al. Efficacy and safety of stereotactic body radiation therapy for the treatment of pulmonary metastases from sarcoma: A potential alternative to resection. *J Surg Oncol* 2016;114:65-69. Available at: <https://www.ncbi.nlm.nih.gov/pubmed/27111504>.

426. Tabone MD, Kalifa C, Rodary C, et al. Osteosarcoma recurrences in pediatric patients previously treated with intensive chemotherapy. *J Clin Oncol* 1994;12:2614-2620. Available at: <http://www.ncbi.nlm.nih.gov/pubmed/7989936>.

427. Saeter G, Hoie J, Stenwig AE, et al. Systemic relapse of patients with osteogenic sarcoma. Prognostic factors for long term survival. *Cancer* 1995;75:1084-1093. Available at: <http://www.ncbi.nlm.nih.gov/pubmed/7850705>.

428. Ferrari S, Briccoli A, Mercuri M, et al. Postrelapse survival in osteosarcoma of the extremities: prognostic factors for long-term survival. *J Clin Oncol* 2003;21:710-715. Available at: <http://www.ncbi.nlm.nih.gov/pubmed/12586810>.

429. Buddingh EP, Anninga JK, Versteegh MIM, et al. Prognostic factors in pulmonary metastasized high-grade osteosarcoma. *Pediatr Blood Cancer* 2010;54:216-221. Available at: <http://www.ncbi.nlm.nih.gov/pubmed/19890902>.

430. Briccoli A, Rocca M, Salone M, et al. High grade osteosarcoma of the extremities metastatic to the lung: long-term results in 323 patients treated combining surgery and chemotherapy, 1985-2005. *Surg Oncol* 2010;19:193-199. Available at: <http://www.ncbi.nlm.nih.gov/pubmed/19515554>.

431. Daw NC, Chou AJ, Jaffe N, et al. Recurrent osteosarcoma with a single pulmonary metastasis: a multi-institutional review. *Br J Cancer*



2015;112:278-282. Available at:

<http://www.ncbi.nlm.nih.gov/pubmed/25422914>.

432. Bielack SS, Kempf-Bielack B, Branscheid D, et al. Second and subsequent recurrences of osteosarcoma: presentation, treatment, and outcomes of 249 consecutive cooperative osteosarcoma study group patients. *J Clin Oncol* 2009;27:557-565. Available at:

<http://www.ncbi.nlm.nih.gov/pubmed/19075282>.

433. Berger M, Grignani G, Ferrari S, et al. Phase 2 trial of two courses of cyclophosphamide and etoposide for relapsed high-risk osteosarcoma patients. *Cancer* 2009;115:2980-2987. Available at:

<http://www.ncbi.nlm.nih.gov/pubmed/19452540>.

434. Gentet JC, Brunat-Mentigny M, Demaille MC, et al. Ifosfamide and etoposide in childhood osteosarcoma. A phase II study of the French Society of Paediatric Oncology. *Eur J Cancer* 1997;33:232-237. Available at:

<http://www.ncbi.nlm.nih.gov/pubmed/9135494>.

435. Miser JS, Kinsella TJ, Triche TJ, et al. Ifosfamide with mesna uroprotection and etoposide: an effective regimen in the treatment of recurrent sarcomas and other tumors of children and young adults. *J Clin Oncol* 1987;5:1191-1198. Available at:

<http://www.ncbi.nlm.nih.gov/pubmed/3114435>.

436. Duffaud F, Mir O, Boudou-Rouquette P, et al. Efficacy and safety of regorafenib in adult patients with metastatic osteosarcoma: a non-comparative, randomised, double-blind, placebo-controlled, phase 2 study. *Lancet Oncol* 2019;20:120-133. Available at:

<https://www.ncbi.nlm.nih.gov/pubmed/30477937>.

437. Davis LE, Bolejack V, Ryan CW, et al. Randomized Double-Blind Phase II Study of Regorafenib in Patients With Metastatic Osteosarcoma. *J Clin Oncol* 2019;37:1424-1431. Available at:

<https://www.ncbi.nlm.nih.gov/pubmed/31013172>.

438. Merimsky O, Meller I, Flusser G, et al. Gemcitabine in soft tissue or bone sarcoma resistant to standard chemotherapy: a phase II study.

Cancer Chemother Pharmacol 2000;45:177-181. Available at:

<http://www.ncbi.nlm.nih.gov/pubmed/10663634>.

439. Van Winkle P, Angiolillo A, Krailo M, et al. Ifosfamide, carboplatin, and etoposide (ICE) reinduction chemotherapy in a large cohort of children and adolescents with recurrent/refractory sarcoma: the Children's Cancer Group (CCG) experience. *Pediatr Blood Cancer* 2005;44:338-347. Available at:

<http://www.ncbi.nlm.nih.gov/pubmed/15503297>.

440. Palmerini E, Jones RL, Marchesi E, et al. Gemcitabine and docetaxel in relapsed and unresectable high-grade osteosarcoma and spindle cell sarcoma of bone. *BMC Cancer* 2016;16:280. Available at:

<https://www.ncbi.nlm.nih.gov/pubmed/27098543>.

441. Anderson PM, Wiseman GA, Dispenzieri A, et al. High-dose samarium-153 ethylene diamine tetramethylene phosphonate: low toxicity of skeletal irradiation in patients with osteosarcoma and bone metastases. *J Clin Oncol* 2002;20:189-196. Available at:

<http://www.ncbi.nlm.nih.gov/pubmed/11773169>.

442. Loeb DM, Garrett-Mayer E, Hobbs RF, et al. Dose-finding study of 153Sm-EDTMP in patients with poor-prognosis osteosarcoma. *Cancer* 2009;115:2514-2522. Available at:

<http://www.ncbi.nlm.nih.gov/pubmed/19338063>.

443. Grignani G, Palmerini E, Dileo P, et al. A phase II trial of sorafenib in relapsed and unresectable high-grade osteosarcoma after failure of standard multimodal therapy: an Italian Sarcoma Group study. *Ann Oncol* 2012;23:508-516. Available at:

<http://www.ncbi.nlm.nih.gov/pubmed/21527590>.

444. Grignani G, Palmerini E, Ferraresi V, et al. Sorafenib and everolimus for patients with unresectable high-grade osteosarcoma progressing after standard treatment: a non-randomised phase 2 clinical trial. *Lancet Oncol* 2015;16:98-107. Available at:

<http://www.ncbi.nlm.nih.gov/pubmed/25498219>.

445. Lashkari A, Chow WA, Valdes F, et al. Tandem high-dose chemotherapy followed by autologous transplantation in patients with



locally advanced or metastatic sarcoma. *Anticancer Res* 2009;29:3281-3288. Available at: <http://www.ncbi.nlm.nih.gov/pubmed/19661346>.

446. Fagioli F, Aglietta M, Tienghi A, et al. High-dose chemotherapy in the treatment of relapsed osteosarcoma: an Italian sarcoma group study. *J Clin Oncol* 2002;20:2150-2156. Available at: <http://www.ncbi.nlm.nih.gov/pubmed/11956277>.

447. Papagelopoulos PJ, Galanis EC, Sim FH, Unni KK. Clinicopathologic features, diagnosis, and treatment of malignant fibrous histiocytoma of bone. *Orthopedics* 2000;23:59-65; quiz 66-57. Available at: <http://www.ncbi.nlm.nih.gov/pubmed/10642003>.

448. Bacci G, Avella M, Picci P, et al. Primary chemotherapy and delayed surgery for malignant fibrous histiocytoma of bone in the extremity. *Tumori* 1990;76:537-542. Available at: <http://www.ncbi.nlm.nih.gov/pubmed/2178284>.

449. Bacci G, Picci P, Mercuri M, et al. Neoadjuvant chemotherapy for high grade malignant fibrous histiocytoma of bone. *Clin Orthop Relat Res* 1998;178-189. Available at: <http://www.ncbi.nlm.nih.gov/pubmed/9577426>.

450. Bramwell VH, Steward WP, Nooij M, et al. Neoadjuvant chemotherapy with doxorubicin and cisplatin in malignant fibrous histiocytoma of bone: A European Osteosarcoma Intergroup study. *J Clin Oncol* 1999;17:3260-3269. Available at: <http://www.ncbi.nlm.nih.gov/pubmed/10506628>.

451. Brown HK, Schiavone K, Gouin F, et al. Biology of Bone Sarcomas and New Therapeutic Developments. *Calcif Tissue Int* 2018;102:174-195. Available at: <https://www.ncbi.nlm.nih.gov/pubmed/29238848>.

452. Li X, Shao C, Shi Y, Han W. Lessons learned from the blockade of immune checkpoints in cancer immunotherapy. *J Hematol Oncol* 2018;11:31. Available at: <https://www.ncbi.nlm.nih.gov/pubmed/29482595>.

453. Sukari A, Nagasaka M, Al-Hadidi A, Lum LG. Cancer Immunology and Immunotherapy. *Anticancer Res* 2016;36:5593-5606. Available at: <https://www.ncbi.nlm.nih.gov/pubmed/27793882>.

454. Topalian SL, Taube JM, Anders RA, Pardoll DM. Mechanism-driven biomarkers to guide immune checkpoint blockade in cancer therapy. *Nat Rev Cancer* 2016;16:275-287. Available at: <https://www.ncbi.nlm.nih.gov/pubmed/27079802>.

455. Chalmers ZR, Connelly CF, Fabrizio D, et al. Analysis of 100,000 human cancer genomes reveals the landscape of tumor mutational burden. *Genome Med* 2017;9:34. Available at: <https://www.ncbi.nlm.nih.gov/pubmed/28420421>.

456. Yarchoan M, Hopkins A, Jaffee EM. Tumor Mutational Burden and Response Rate to PD-1 Inhibition. *N Engl J Med* 2017;377:2500-2501. Available at: <https://www.ncbi.nlm.nih.gov/pubmed/29262275>.

457. Cancer Genome Atlas N. Comprehensive molecular characterization of human colon and rectal cancer. *Nature* 2012;487:330-337. Available at: <https://www.ncbi.nlm.nih.gov/pubmed/22810696>.

458. Le DT, Uram JN, Wang H, et al. PD-1 Blockade in Tumors with Mismatch-Repair Deficiency. *N Engl J Med* 2015;372:2509-2520. Available at: <https://www.ncbi.nlm.nih.gov/pubmed/26028255>.

459. Le DT, Durham JN, Smith KN, et al. Mismatch repair deficiency predicts response of solid tumors to PD-1 blockade. *Science* 2017;357:409-413. Available at: <https://www.ncbi.nlm.nih.gov/pubmed/28596308>.

460. Administration USFaD. FDA approves first cancer treatment for any solid tumor with a specific genetic feature; 2017. Available at: <https://www.fda.gov/newsevents/newsroom/pressannouncements/ucm560167.htm>.

461. Marabelle A, Fakih M, Lopez J, et al. Association of tumour mutational burden with outcomes in patients with advanced solid tumours treated with pembrolizumab: prospective biomarker analysis of the multicohort, open-label, phase 2 KEYNOTE-158 study. *Lancet Oncol* 2020. Available at: <https://www.ncbi.nlm.nih.gov/pubmed/32919526>.



462. FDA. FDA approves pembrolizumab for adults and children with TMB-H solid tumors; 2020. Available at: <https://www.fda.gov/drugs/drug-approvals-and-databases/fda-approves-pembrolizumab-adults-and-children-tmb-h-solid-tumors>.